

PROSTHETIC STOMATITIS IN GERIATRIC PATIENTS

ALINA CRISTIAN, DIANA MÂRZA, MARWA YASSIN CĂTĂNICIU

„Lucian Blaga” University of Sibiu

Abstract: The paper emphasizes the clinical aspects that may occur in elder patients who have partial, total or skeletal prostheses. The clinical study was made during a period of 3 years on 78 patients who had different clinical forms of prosthetic stomatitis.

Keywords: stomatitis, prostheses

Rezumat: Lucrarea prezintă manifestările clinice care pot să apară la pacienții geriatrici purtători de proteze totale sau parțiale acrilice sau de proteze scheletate. Studiul clinic s-a desfășurat pe perioada a 3 ani, cuprinzând un lot de 78 de pacienți care prezentau diverse forme clinice ale stomatopatiilor protetice.

Cuvinte cheie: stomatopatii, proteze dentare

INTRODUCTION

Prosthetic stomatitis is a frequent affection of the oral mucosa that cannot adapt itself from the physiological point of view, to the pressures or component parts of a prosthesis and is specific to the geriatric patients, who wear mobile prostheses [1,3]. This type of affections may occur on the background of certain diseases: diabetes, vascular diseases, hemopaties, arteriosclerosis, as well as due to certain local favouring factors, such as: deficient oral hygiene, acrylate porosity and the organism's reaction to the type of acrylate used, instability of prosthesis or due to imperfections in the accomplishment of prosthesis [2,4].

MATERIAL AND METHOD

Within our dental medicine setting, we have accomplished a study between September and January 2008, which aimed at monitoring the oral health condition of 78 patients, who wore mobile prostheses, aged between 65 and 82 and whose clinical examination revealed the presence of prosthetic stomatitis of different etiologies.

We issued an individual study sheet for each patient, mentioning besides the personal data, a questionnaire regarding the prosthesis wearing length, type of the prosthetic work, hygienization frequency and the patients' health condition.

The results of this study were materialized in tables and graphics.

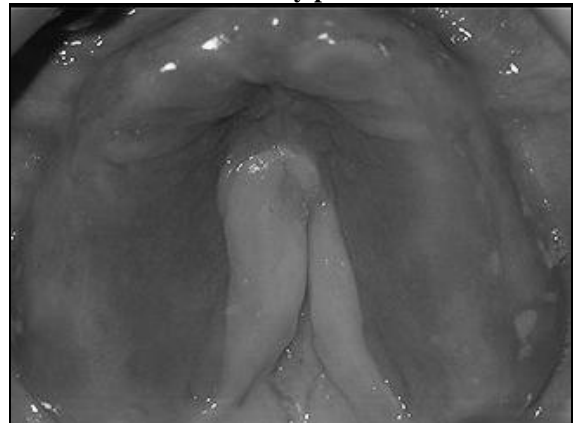CLINICAL CASES

Case 1:

The patient F.I., 68 years old, presented maxillary prosthetic stomatitis which affected the entire fixed gum that entered in direct contact with the mucosal face of an acrylic prosthesis. (picture no. 1).

This hypertrophy reaction of mucosa is late, the patient had been wearing the prosthesis for 5 years, period of time in which she was diagnosticated with major vascular disorders. The formation is not painful, is firm and does not present dyskeratosis. We guided the patient towards the specialized oro-maxial-facial service. The biopsic exam did not reveal any malign formation.

Picture no. 1: Late maxillary prosthetic stomatitis

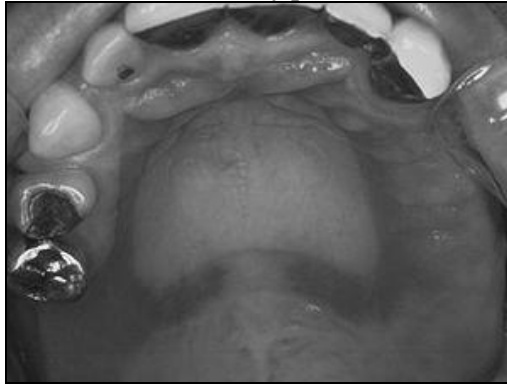

Case 2:

The patient T.E., 72 years old came to our specialized setting for the intra-oral examination, complaining about strong burn and discomfort in the area of the palate when masticating. The clinical examination revealed the presence of a basal stomatitis brought about by the maxillary skeletal prosthesis made 6 months ago. (picture no. 2). In the area of the hard palate and of the edentate crests, the impression of the prosthesis could be observed, presenting an erythematous area, irritating and sensitive to palpation. The patient's oral hygiene was deficient, this being the main cause of stomatitis.

CLINICAL ASPECTS

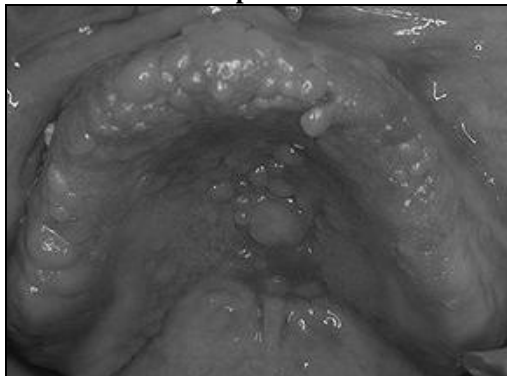
Picture no. 2: Basal maxillary prosthetic stomatitis



Case 3:

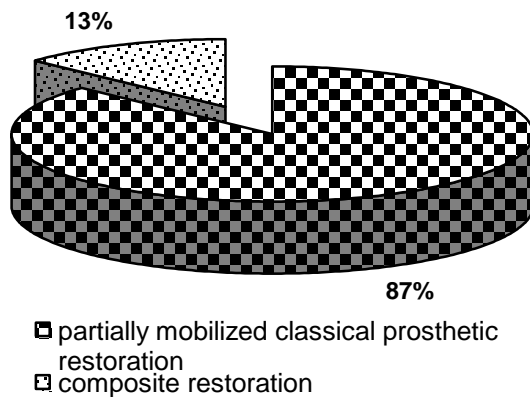
The intra-oral clinical examination of the patient F.C. revealed the presence of immediate allergic stomatitis that intersects the entire palatine mucosa (picture 3). The patient used to wear a total acrylic prosthesis accomplished three months ago. Although she had been trained, she did not remove the prosthesis from the prosthetic field for hygienization. The entire acrylic area presented food deposits, dental plaque and tartar.

Picture no. 3: Immediate prosthetic stomatitis



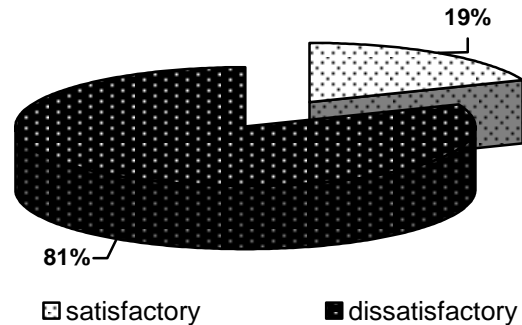
RESULTS AND DISCUSSIONS

Picture no. 4: Prosthetic stomatitis incidence according to the type of partially mobilized classical prosthetic restoration, in comparison with the composite restoration (fixed and adjunct).



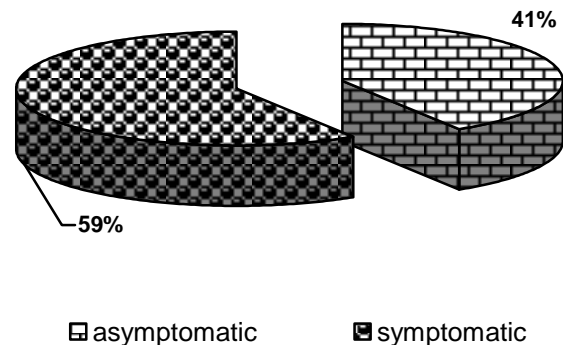
Out of those 78 patients included in our study, the majority presented stomatitis in relation with the partially mobilized classical prosthesis and there were only few cases that emphasized stomatitis in the patients with composite restoration.

Picture no. 5: Oral hygienization of the patients with prosthetic stomatitis



The low interest towards the oro-dental health of this category of patients is also reflected in the high percentage represented by a dissatisfactory oral hygienization.

Picture no. 6: Frequency of symptomatic or asymptomatic prosthetic frequency in the studied batch.



Regarding the relation of prostheses with the prosthetic field, the asymptomatic prosthetic stomatitis are predominant, mostly due to the deficient oral hygienization.

CONCLUSIONS

1. Prosthetic stomatitis are affections specific to the geriatric patients;
2. 87% of the patients with prosthetic stomatitis included in our study presented total or partial acrylic restoration;
3. The study emphasized a reduced preoccupation for the oro-dental hygiene, 81% of the cases evidencing a dissatisfactory oral hygiene;
4. Asymptomatic prosthetic stomatitis may be encountered in 59% of the patients, missing in 41% of cases;
5. The aspects encountered within the study must be taken into account according to the systemic

conditioning, besides the economic and socio-economic one.

BIBLIOGRAPHY

1. Bratu D., Ieremia L., Uram-Țuculescu S.: Bazele clinice și tehnice ale Protezării edentației totale, Oradea, Imprimeria de Vest, 2003;
2. Hutu E., Mihaela Păuna, Bodnar V., Constantinescu M.V.: Edentația totală. Aspecte clinice și tratament. Ed. Didactică și Pedagogică RA București 1996;
3. Laludenbach P.: "Stomatologie geriatrique". Encyc. Med. Chir. Stomatologie. Paris, 22052, 1991
4. Ieremia L., Chirilă Mioara - Balaș: "Gerontognatoprotetică. Elemente fundamentale și aplicative", Ed. University Press Tg. Mureș, 1999;