

EFFECTS OF THE OCCLUSAL TRAUMA ON THE MARGINAL PERIODONTIUM

ALINA CRISTIAN, DIANA MĂRZA, MARWA YASSIN CĂTĂNICIU

„Lucian Blaga” University of Sibiu

Abstract: *The paper presents the negative effects of occlusal trauma on the periodontal tissues due to multiple facts. These effects will bring about the over time loss of teeth, as well as dysfunctions of the entire dentomaxillary system*

Keywords: *occlusal trauma, periodontal disease*

Rezumat: *Lucrarea dezvăluie efectele negative ale traumei ocluzale, de diverse etiologii, asupra parodonțiului marginal, care vor determina în timp pierderea unităților masticatorii și implicit a funcționalității aparatului dento-maxilar*

Cuvinte cheie: *trauma ocluzală, boala parodontală.*

The occlusal trauma occurs in the disharmonic occlusion, as a result of the supraliminal occlusal forces, unphysiological in terms of intensity, length or frequency. (2) These may be classified into:

- Acute – brought about by the accidental interruption of certain hard objects between the dental arches during mastication or indirectly, as a result of accidental hits;
- Chronic – as a result of the overstress of the teeth in the neighbourhood of the edentate breach;
- Primary – pathological lesion – as a result of certain aggressive forces acting on the normal periodontium (active accelerating eruptions of the teeth, obturations or high crowns, improper orthodontic devices, parafunctional clench or grind of the teeth, interference of the pathologically migrated teeth, vicious occlusal habits).
- Secondary – lesion produced by a normal occlusal force acting on an affected periodontium.

Periodontal traumatic lesions:

The lesion caused by the occlusal trauma (atrophy or necrosis) does not have an inflammatory etiology, being the result of the compression of the blood vessels and tissues. (5)

If the mastication forces exceed the periodontium adaptation capacity, traumatic lesions will occur at this level.

The potential of the lateral or horizontal mastication forces is as smaller as they act on the crown cervical area, due to the fact that the application point of

the force is closer to the rotation centre of the traumatized tooth.

The torsion forces are the most harmful for the periodontium, as they induce apposition or even dental luxation.

The occlusal traumatism does not produce the gingival inflammation. The association of the occlusal trauma with the gingival inflammation may produce the occurrence of the periodontal pathologic pouches and of the osseous defects – co-destructive effect. (3)

The gingival evolutive inflammatory processes act on the gums and bones, with the profound affection of the periodontal ligament. (6) The evolution of the septic trauma is altered by the more serious affection of the periodontal ligament than of the bone or, through the accentuation of the alveolar bone re-absorption, more in lateral sense and implicitly, the occurrence of osseous pouches. (2)

The periodontal structures may suffer a series of changes, as a response to the different intensities of the occlusal trauma on the teeth. These disorders of the marginal periodontium homeostasis are manifested by the dental mobility of different degrees, as follows:

Table no. 1. Effects of the disorders of the marginal periodontium homeostasis

Homeostatic equilibrium	Periodontal structure	Dental mobility
hypo-function	hypotrophy	low
normal	normal	normal
hyper-function	hypertrophy	increased
traumatic occlusal	traumatic lesions	increased

If the increased dental mobility is maintained, the periodontium capacity to adapt to the large mastication forces will be exceeded and will bring about an enlargement of the periodontal space and a re-absorption of the bone. (7)

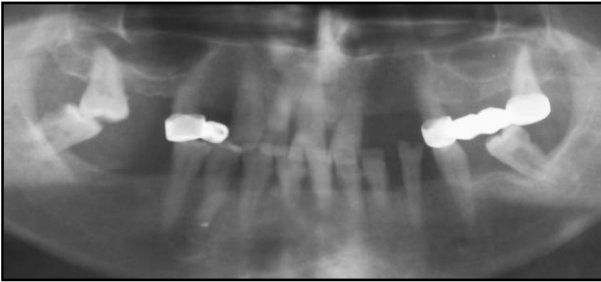
From the radiological point of view, at the level of the teeth in occlusal trauma, the following could be observed:

- Enlargement of the periodontium space associated to the narrowing of the lamina up to the partial or total destruction of this one, resulting in a dental mobility over the normal limits, as in picture no. 1. (3)

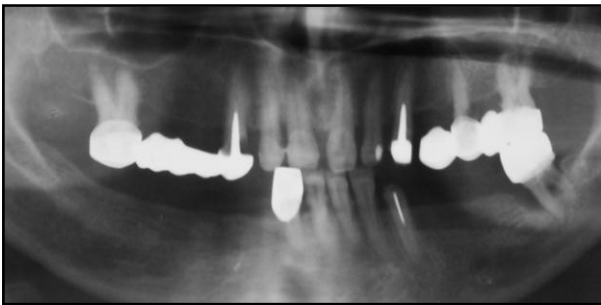
CLINICAL ASPECTS

- Periapical osseous rarefaction – hyper-transparency – in the vital teeth (picture no. 3). (3)
- The top of the interdental septa may present angular defects and without accentuated osseous re-absorptions. (2);
- The re-absorption of the alveolar or intra-radicular limbus, which occurs late after the over-infection of the periodontium (picture no. 2). (2)
- Condensation of the alveolar spongy osseous bone structure;
- Rounded thickness of the radicular apex – hypercementosis – and the radicular re-absorption, secondary to the trauma (risalis phenomena);
 - Re-absorption through the demineralization of the cement with a false aspect of increasing the periodontal space;
 - Root vertical re-absorption;

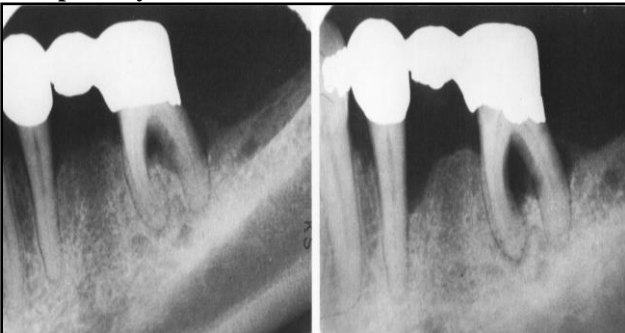Picture no. 1. Enlargement of the periodontal space at the level of the lower molars



Picture no. 2. Re-absorption of the alveolar and intra-radicular limbus, which occurs late after the over-infection of the periodontium marked at the level of the tooth 3.7



Picture no. 3. Periapical osseous rarefaction – hyper-transparency – at the vital teeth in occlusal trauma



CONCLUSIONS

1. For a practitioner, it is difficult to assess whether, from the etiological point of view, the occlusal trauma is primary or secondary, when after the periodontal affection caused by the occlusal trauma, the inflammatory component becomes over-infected.
2. Regarding the teeth in occlusal trauma, the selective polishing is required (corono-plastia);
3. The morpho-functional restoration of the obturations and prosthetic constructions require the observance of the functional occlusal conceptions. When recovering the occlusal area of a tooth, it is preferable not to perform a standard disharmonic morphology, but to perform certain occlusal antagonist elements with the transmission of the pressures along the tooth axe.
4. Odontal, prothetic restoration therapy includes preventing the occlusal iatrogeny and the adjustment of the occlusal disharmonies (obturations, micro-prostheses associated to corono-plastia).

REFERENCES

1. Ionita S, Petre A. Ocluzia dentară, Editura Didactică și Pedagogică R. A., București, 1997.
2. Horia Dumitriu. Parodontologie, Editura Viața Medicală Românească, București 1999.
3. Popa Sever. Protetica Dentară, Editura Medicală 2001.
4. Prelipceanu F, Doroga O. Protetică dentară, Editura Didactică și Pedagogică, București, 1986.
5. Davidovitz Z. Tooth Movement. Oral. Med. Biol. 1999.
6. Ante I H. Abutments. J Can Dent 1936.
7. Ramfjord SP and Ash MM JJ, Occlusion. 2nd Ed. Philadelphia, W. B. Saunders Co., 1971.