

STAGE I MEDIASTINO-PULMONARY SARCOIDOSIS WITH SIMULTANEOUS CARDIAC INVOLVEMENT – CASE REPORT

MARIA LĂCRĂMIOARA SÎNTĂMĂREANU

Clinical County Emergency Hospital of Sibiu

Abstract: Cardiac involvement in sarcoidosis, a multisystemic disease, characterized by the presence of noncaseating epithelioid granulomas, upon debut and when is clinically expressed, is defined by a reserved prognosis. The case presented, a 28 year-old male, non-smoker, with no significant medical history, who comes to the emergency room accusing lipothymia, palpitations, nausea, with normal cardiopulmonary examination. He is diagnosed with stage I mediastino-pulmonary sarcoidosis with simultaneous cardiac involvement. Long-term corticotherapy is initiated.

Keywords: cardiac sarcoidosis, noncaseating epithelioid granuloma, hilar adenopathy, differential diagnosis, corticotherapy

Rezumat: Afectarea cardiacă în sarcoidoză, boală multisistemică ce se caracterizează prin prezența granulomului epitelioid necazeificat, atunci când survine și se exteriorizează clinic, este grevată de un prognostic rezervat. Cazul prezentat, bărbat în vârstă de 28 ani, nefumător, cu antecedente patologice nesemnificative, ce se prezintă în serviciul de urgență acuzând stare lipotimică, palpitații, greață, cu examen obiectiv cardiopulmonar în limite normale, este diagnosticat, în urma investigațiilor de laborator și imagistice, cu sarcoidoză mediastino-pulmonară stadiul I cu afectare cardiacă simultană, instituindu-se corticoterapie pe termen lung.

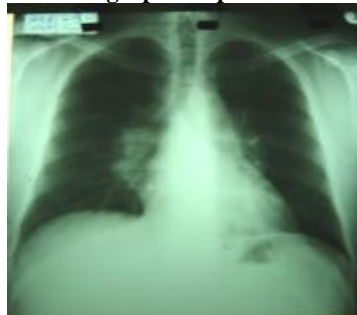Cuvinte cheie: sarcoidoză cardiacă, granulom epitelioid necazeificat, adenopatie hilară, diagnostic diferențial, corticoterapie

INTRODUCTION

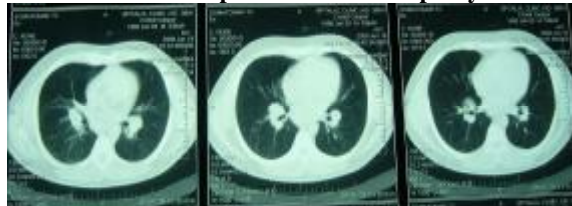A 28-year old male patient, non-smoker, with familial history of ischemic cardiopathy and chronic obstructive bronhopneumopathy, with no significant medical history, working at the Public Service of Salubrity, comes to the emergency room of the Clinical County Emergency Hospital, accusing lipothymia, palpitations, nausea, symptoms that occurred while the patient was on his way to work. Clinical examination revealed: BMI=31,14 Kg/m², constitutionally hyperpigmented teguments, BP=110/60 mmHg, HR=84 b/min. Chest radiography showed the left ventricle inferior arch slightly elongated and symmetrical, well delimited, polycyclic bilateral hilar opacities (picture no. 1).

Computed tomography revealed the presence of multiple mediastinal and bilateral hilar adenopathies and bilateral perihilar increased pulmonary interstitium. Ventilatory function was in normal ranges. EKG: sinus rhythm, HR=68 b/min, cardiac axis at 0°, inverted T waves in DIII, aVF which, was also present on EKG made in deep inspiration.

Picture no. 1. Radiographic aspect of hilar adenopathy



Picture no. 2. CT aspect of hilar adenopathy



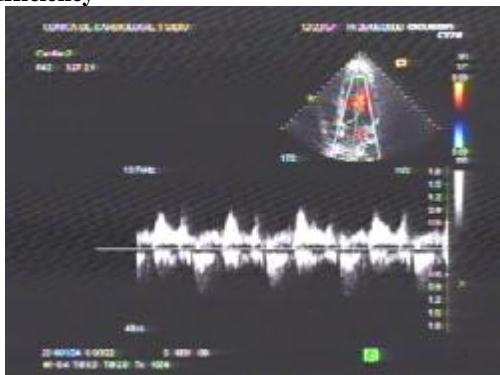
Holter monitorization emphasized sinusual pauses, atrial extrasystoles, pathologic Q waves in DI and aVL with no significance of coronary disease. Doppler echocardiography revealed a “variegated”, hyperecogen, slightly thickened septum, global hyperkinesia of the left ventricle, especially in the medio-apical septal region, ejection fraction (globally evaluated) of about 45%, mitral insufficiency grade I/II (picture no. 3), aortic and tricuspid insufficiency grade I.

Exercise tolerance testing was negative. Fiberbronchoscopy showed vocal cords and trachea of normal aspect, slightly enlarged carina at the base, a few whitish granulations scattered mainly in the left bronchial tree (at the level of the main left bronchus and interlobar spur LSL/LIL) (picture no. 4) with no signs of bronchial compression.

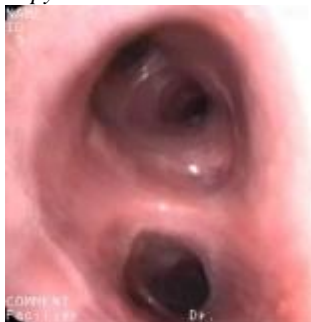CLINICAL ASPECTS

Cytological examination of bronchoalveolar lavage indicated the presence of lymphocytosis (28% lymphocytes). Bacteriologic examination: negative microscopy and cultures for KB (BAL). Histopathologic examination of bronchial mucosae fragments showed a reactionated epithelium and moderate corial perivascular lymphocytic infiltrate. PPD intradermoreaction (2 U) was positive (14 mm/Palmer II). Biologic examinations indicated peripheral lymphopenia, slightly increased serum calcium; markers of inflammatory syndrome were in normal ranges; hepatic and renal function with no modifications; blood sugar, lipids, proteins and immunologic profile were normal. Abdominal echography and eye examination revealed no pathologic modifications.

Picture no. 3. Echocardiographic aspect of mitral insufficiency



Picture no. 4. Whitish granulations revealed by fibrobronchoscopy



Based on clinical, biologic and imagistic examinations, we have established the high probability diagnosis of stage I mediastino-pulmonary sarcoidosis with simultaneous cardiac involvement. Corticotherapy was initiated (with gastric protection – Omeprazole 20mg/day) by administrating Prednisone 40 mg/day for a month, with subsequent progressive diminished doses up to a maintenance dose of 10 – 15 mg/day.

Simultaneous chemoprophylaxis with Isoniaside, 5 mg/Kg/day, for six to twelve months was initiated in order to prevent a tuberculosis reactivation, knowing that the patient had a positive PPD intradermoreaction.

In conclusion, the lack of histologic evidence of sarcoid granulomas and, especially, the impossibility of

performing the imagistic explorations with high sensitivity in the diagnosis of cardiac sarcoidosis (Delayed Gadolinium-enhanced magnetic resonance imaging, ^{18}F -FDG-PET, ^{201}Tl , ^{67}Ga or $^{99\text{m}}\text{Tc}$ scintigraphy)^(1,2,3) unable us to strongly sustain the diagnosis of cardiac sarcoidosis. In this context, a differential diagnosis, especially with ischemic cardiopathy, is to be considered. The coronary angiography would have been extremely useful to exclude the ischemic disease but, unfortunately, we did not have access to this exploration.

Still, the diagnosis of mediastino – pulmonary sarcoidosis established on the characteristic aspect of the hilar adenopathy and the presence of lymphocytic alveolitis, correlated with the young age of the patient, the normal profile of lipids and the negative exercise tolerance testing tilt the balance against the diagnosis of cardiac sarcoidosis rather than against ischemic cardiopathy. The absence of the sarcoid granulomas on the bronchial mucosae biptic specimens does not exclude the diagnosis of sarcoidosis, knowing the fact that these are emphasized only in 57 – 88 of the cases.(4,5)

BIBLIOGRAPHY

1. Smedema JP, Snoep G et al. Evaluation of the Accuracy of Gadolinium-Enhanced Cardiovascular Magnetic resonance in the Diagnosis of Cardiac Sarcoidosis, *J Am Coll Cardiol* 2005;(45):1683-1690.
2. Okumura W, Iwasaki T, Toyama T. Usefulness of Fasting ^{18}F -FDG PET in Identification of Cardiac Sarcoidosis, *Journal of Nuclear Medicine* 2004;45(12):1989-1998.
3. Pandya C, Brunken RC, Tchou P et al. Detecting cardiac involvement in sarcoidosis: a call for prospective studies of newer imaging techniques. *Eur Respir J* 2007;(29):418-422.
4. Costabel U, Guzman J, Drent M. Diagnosis approach to sarcoidosis. *Eur Respir Monograph*, 2005;(10):259–264.
5. Poletti V, Casoni G, Chilosi M. Pathology. *Eur Respir Monograph* 2005: 82-91.