

INDICATIONS AND ADVANTAGES OF THE EARLY VITRECTOMY IN THE HEMOPHTHALMUS FROM DIABETIC RETINOPATHY

R. BĂLĂ¹, ADELINA BĂLĂ

^{1,2} Military Emergency Hospital Sibiu

Cuvinte cheie: hemofthalmus, retinopatie diabetică, decolare retiniană traccională

Keywords: hemophthalmus, diabetic retinopathy, tractional retinian detachment

Rezumat: *Lucrarea prezintă principalele indicații și avantaje ale vitrectomiei precoce în cazul frecvenței complicații oculare din retinopatia diabetică – hemofthalmusul. Abordarea chirurgicală act „agresivă” permite o recuperare funcțională importantă rapidă.*

Abstract: *This study presents the main indications and advantages of the early vitrectomy in the most severe eye complication in the diabetic retinopathy-the hemophthalmos. A more aggressive surgical approach allows the important and fast functional recovery.*

SCIENTIFIC ARTICLE OF BIBLIOGRAPHIC SYNTHESIS

The persistent vitrean hemorrhage, the oldest indication of vitrectomy in the diabetic patient, continues to be from the point of view of frequency, the main vitreoretinian cause of surgery in the diabetic retinopathy, despite the extended use of the retinian photocoagulation. The timing of this surgical intervention is still the object of vast controversy in the literature of speciality. According to the study Diabetic Retinopathy Vitrectomy Study (DRVS) effectuated in 1985 only in the lots of patients with diabetes mellitus type I, was observed a significant improvement of the visual acuity. After the surgical intervention in the first six months from the stroke. It is supposed that for this type of diabetes, the postpone of the surgery allowed the excessive development of the fibrovascular tissue with the aggravation of the retinian manifestations. For the cases of diabetes type II the post-surgery results of the two lots with early vitrectomy and the one with postponed vitrectomy for one year were alike. Benson in his study recommended avoiding the surgery for at least 6 months, if there are no important retinian tractions, to allow the hyaline a spontaneous clarification, more than 25% of the patients with early vitrectomy are according to DRVS in the stadium of NLP, no luminous perception. More, any study has proved the retinian affectation after the ocular siderosis in the old hemophthalmus. The conclusions of this study lost their values with the apparition of the retinian endophotocoagulation.

The present conception that should be adopted in all cases of persistent hemophthalmos recommends the vitrectomy, in the absence of rubeosis iridis, in the first 3 months after the apparition of the hemorrhage in patients with type I diabetes mellitus and in the first 6 months in patients with diabetes mellitus type II. In particular cases, the opportunity of the intervention will be decided not only by the old hemophthalmus, the type of diabetes mellitus, but also the severity of the retinian manifestations (monitored before the vitrean hemorrhage) and by the status of the other eye. A special mention for the patients with a multisystemic advanced affectation in which is possible

the anesthesia, it is recommended the emergency surgery, a visual rehabilitation having a powerful social and emotional impact. The main advantage of the early vitrectomy is the possibility of recovery at the cases of patients with an evolution intra and post surgery, in the shortest time of a superior visual acuity, increasing the quality of life.

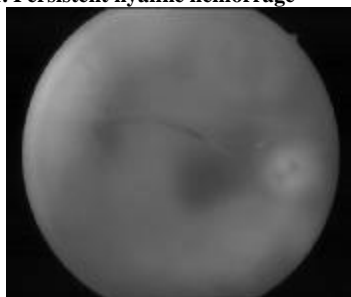
Also, the postpone of the vitrectomy means the postpone of the panphotocoagulation, so the delay of the treatment of retinian ischemia with the possibility of subjective and objective aggravation of the case. More, it is well-known that the resorption of the hyaline hemorrhage varies with the type of hemorrhage. In the hyaline hemorrhage the fibrine is lysed thanks to an enzyme contained in the hyalocytes that activates the plasminogen from the clot of blood in formation. This one splits and the red cells are released then destroyed through spontaneous lysis or through macrophage phagocytosis, so the hemoglobin is released and then the split products. It is produced an agglomeration of the collagen fibrils and a degradation through precipitation and after that a depolymerization of the hyaluronic acid. The whole area interested in hemorrhage is in time liquefied with the organization of the hyaline through straps, bands and yellow-white canvas that eventually disappear, but lately and incomplete, the visual acuteness may remain even in the presence of those resorptions very low. It is well known the high frequency in the diabetic retinopathy proliferative of the recidivant hyaline hemorrhage that determines practically the impossibility of the observed spontaneous hyaline clarification. It has been observed that in old hemophthalmos with duration of years posterior vitrectomy doesn't bring important benefits, because the severe ischemia and of the extended retinian atrophy settled. If, before the vitreoretinian intervention, the panphotocoagulation of the retina it is possible a minimal improvement of the visual acuteness postvitrectomy even to those cases. The pre-surgical diagnosis of the hemophthalmus doesn't raise any clinical problems, the diagnosis being easy. The biomicroscopic exam of the eye bottom won't allow the visualization of the details at the posterior pole. In those cases, extremely important is the ocular

¹Corresponding Author: R. Bălă, Military Emergency Hospital Sibiu, 42-46, B-dul Victoriei street, Sibiu, România, e-mail: radubala@gmail.com; tel +40-(269) 2112 09

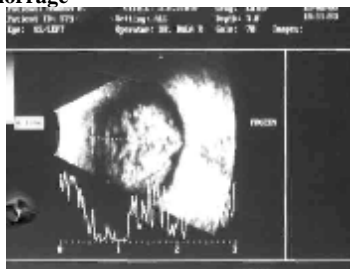
Article received on 20.04.2010 and accepted for publication on 30.04.2010
ACTA MEDICA TRANSILVANICA June 2010; 2(2)181-182

ecography (fig.2, 3) which through the extremely utile information provided may disjoint the diagnosis: the presence or the absence of the tractionale membranes or of an internal retinian detachment, the presence and the localization of the hemorrhage. The ecographic images reveal usually a dispersion of light points in the area corresponding to the hyaline, the blood being powerfully ultrasonoreflectant. Not rarely may be decelated hypodense linear echoes or medium reflective with a pint of departure retinal but with no traction on that level as a sign of the presence of a proliferative fibrovascular process. There are many situations that associate the hemophthalmus with a tractional retinal detachment, these representing practically from the point of view of the observed frequency the second surgical indication of the proliferative retinian detachment.

Figure no. 1. Persistent hyaline hemorrhage



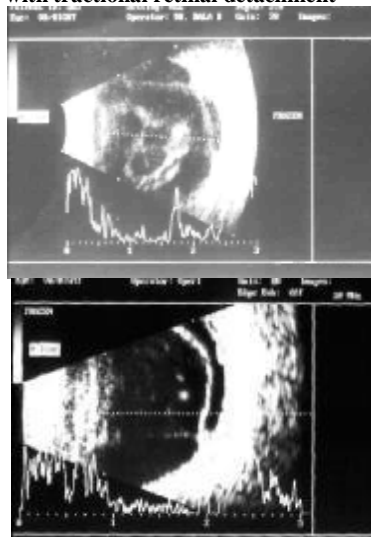Figures no. 2. and 3. Ocular ecographies in persistent hyaline hemorrhage



The traditional DR pathogeny from the diabetic retinopathy has developed interactions with the posterior hyaloid, pre-retinian and retinian fibrovascular proliferative membrane. Initially, the epiretinian fibrovascular tissue insinuating along the posterior hyaloid, realizing strong adherences with the hyaline and the retina. As the fibrous component contains actinic filaments, having contractile properties, according to its development with the apparition of the posterior detachment of the hyaline, almost constant in the diabetics, appear anteroposterior tractions that can determine a retinal detachment. Frecquently, due to the retinal neo-vessels fragility or of the tractional membranes, a tractional retinal detachment even stationary may complicate with the hyaline hemorrhage. Other times, at the cases studied insufficient the ecography (effectuated to confirm the diagnosis of hemophthalmus) will evidenciate for the first time the presence of a tractional detachment of the retina, more if the hemophthalmus is not very dense. The biomicroscopic examination of the posterior pole is in those kind of cases, of a quality inferior to the ecography, the only one adequated to visualize the tractional membranes. Even so, the tractional brides are sometimes difficult to visualize (especially in the dense, massive hyaline hemorrhage) to require the effectuation of ore incidences. The surgical indication in the persistent

hemophthalmus associated to tractional retinal detachment it should be operated as soon as possible, the access to the bottom of the eye being absolutely necessary to prevent the irreversible macular lesions that could determinate an aggravation of the diabetic retinopathy. In conclusion, with the increasing of the surgical performances it is imposed a change of the therapeutical conceptions regarding hemophthalmus in diabetic retinopathy. The vitreoretinal surgery isn't an ultimate precocious therapeutical alternative of those patients, a surgical approach allowing the majority of the cases an important, rapid unctional recovery.

Figures no. 4. and 5. Ocular ecographies in hemophthalmus associated with tractional retinal detachment



BIBLIOGRAPHY

1. Diabetic Retinopathy Vitrectomy Study Research Group. Early vitrectomy for severe vitreous hemorrhage in diabetic retinopathy. Two-year results of a randomized trial. Diabetic retinopathy vitrectomy study report 2. Arch Ophthalmol.1985; 103:1644-54.
2. Benson WE. Diabetic retinopathy. Clinical Volume 3, chapter 30. Duane's Ophthalmology 2000 on CD-ROM, Lippincott Williams&Wilkins, 2000
3. Charles S. Vitreous Microsurgery. Second edition. Baltimore, London, Los Angeles; Sydney: Williams & Wilkins, 1987: 1 – 25; 115 – 132.
4. Kanski JJ. Clinical ophthalmology – a systematic approach. Fifth edition. Edinburgh, London, New York, Oxford, Philadelphia, St. Louis, Sydney, Toronto: Butterworth – Heinemann, 2003: 393 – 396; 439 – 455.
5. Baron D, Guillemaut MN, Lignereaux F, Levecq R. Conduite a tenir devant une hemorragie intravitreene chez le diabetique. Oftalmologia 2002 ; 2: 76 – 81.
6. Sireteanu L, Tudor C, Sireteanu A. Atlas de ecografie oculară. Tg.-Mures; Tipomur, 1998: 49 – 52; 57.