A SIMPLE SIMULTANEOUS AESTHETIC RESTORATION TECHNIQUE OF TWO FRACTURED UPPER INCISORS

MONA IONAŞ [1], ANCA FRAŢILĂ[2], MARIANA SABĂU[3] T. IONAŞ[4]

[1,2,3] „Lucian Blaga" University of Sibiu, [4]Dental Practice SC.AMIC S.R.L.

Keywords: *teeth fractures, reconstruction*

Abstract: *The coronary reconstruction of the fractured anterior teeth presents a challenge in modern aesthetic stomatology. Therapeutic indication is provided only after a thorough examination in terms of odontal, periodontal and orthodontic health, after an attentive evaluation of the occlusion, as well as after taking into account the aesthetic needs and the economic possibilities of the patients. The patient, 12 years of age, presented for coronary reconstruction of the teeth 11 and 21 affected by crown fracture, without complications. The treatment was performed by using a simultaneous indirect-direct technique for the two incisors, applying a silicone based oral matrix prepared on a wax-up model. This is a simple, minimally invasive method, which does not affect the tooth vitality, ensuring a proper morphological recovery and an appropriate stratification of the composite material with outstanding aesthetic results*

Cuvinte cheie: *facturi dentare, restaurare*

Rezumat: *Reconstituirile coronare ale dinţilor frontali fracturaţi reprezintă o provocare în stomatologia estetică modernă. Indicaţia terapeutică se face după o examinare aprofundată iniţială o examinare atentă din punct de vedere al sănătăţii odontale, parodontale, ortodontice, ocluziei, nevoilor estetice şi posibilităţilor economice.Pacientul, în vârstă de 12 ani s-a prezentat pentru reconstituirea coronară a dinţilor 11 şi 21 afectaţi de fracturi coronare fără complicaţii. Tratamentul s-a realizat printr-o tehnică indirect-directă, simultană, a celor doi incisivi utilizând o matrice orală din silicon realizată după conturarea din ceară pe un model de studiu a peretelui palatinal al „restaurării".Acesată metodă este simplă, minimal invazivă, permite păstrarea vitalităţii dinţilor tineri, asigură o refacere corespunzătoare a morfologiei şi uşurează stratificarea corespunzătoare a materialului compozit cu rezultate estetice deosebite.*

INTRODUCTION

Dental fractures represent an aesthetic imbalance in the overall dental composition. (1) Statistics indicate that dento-alveolar trauma are more common in children and youth, primarily affecting the upper front group. (2)

The dentist is the one who has to choose the most appropriate clinical solution.

The aesthetic expectations of the patients today have increased. Their expectations can be met only after a thorough initial examination with emphasis on odontal, periodontal, ortodontal health, on occlusions and on their aesthetic needs and economic possibilities. (3)

Ceramic veneers and dental composites are the two treatment options for the anterior frontal area. (4,5)

The most conservative non-invasive techniques should be evaluated first. (3) The composite restorations have the advantage of a minimally invasive preparation, an easy in situ adaptation, and also the advantage that the changes in color of the teeth with ageing can easily be repaired.

Ceramic veneers with very stable color properties require a tooth preparation with the reduction of the tooth structure, which is why they are considered irreversible dental treatments. (4, 5)

New materials and methods appear and are in a continuous state of change, this is why the doctor has sometimes difficulties in keeping up with them.

The large coronary restorations require an individual silicon matrix. This can be obtained through a wax-up technique realized on the working model. (6)

MATERIAL AND METHOD

A patient, 12 years of age, presented to the dental office with affected physiognomic function, due to the fracture of teeth 11 and 21, without having the pulp chamber open.

The radiological paraclinical examinations revealed no fractures at root level, showing a positive reaction during the vitality tests.

The aim of the treatment is to restore the morphology and function without affecting the vitality of the teeth.

From an aesthetic point of view, the smile of the patient is affected, the upper central incisors are affected by the fracture, and one can also observe a relief morphological structure of the three lobes, with A2 as a basic color of the teeth.

Cronology of the treatment:

- Examine the patient
- Make a mould of the work area, of the antagonists and of the occlusion
- Prepare the work model
- Realize a wax model of the palate wall of "restoration", in the final desired form.
- Realize a silicone oral matrix which includes the vestibular margin of the incisal edge
- Perform a professional brushing
- Choose the basic color with the help of the color key -A2, take a small amount from the chosen material, photopolymerize it because the colors suffer a light change

[1]Corresponding Author: Mona Ionaş,14, ap. 11 Rahova street, Sibiu, România, e-mail: stomatologmonaionas@yahoo.com, tel +40- 0722237603
Article received on 02.02.2010 and accepted for publication on 15.02.2010
ACTA MEDICA TRANSILVANICA June 2010; 2(2)254-256

after application.

- Isolate the work area with a rubber dam
- Verify the silicone oral matrix and its position
- Realize a slightly uneven bevel on the vestibular surface of the tooth, to allow a uniform transition from the composite material to the tooth.
- Apply the adhesive system and the stratified composite material: A2E for enamel applied on the palate wall, then apply the dentine color A2D for the three lobes, and finally YT for translucency. The photopolymerization process of the adhesive takes 10 seconds, the composite material being applied in layers of max. 1,5-2mm, the photopolymerization time measures 10 seconds for enamel shades and translucency, and 20 seconds for dentine shades, according to the manufacturer's indications for the equipment used.
- Remove the silicone oral matrix
- Finishing and polishing

Figure no. 1. Initial aspect

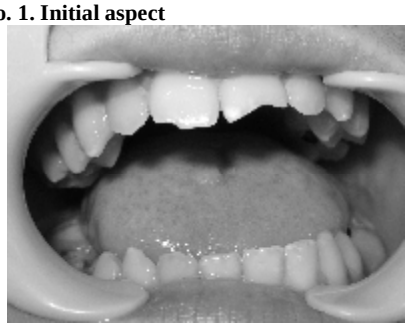

Figure no. 2. To obtain an individualised oral matrix, a palatinal wall of „restoration" is shaped in wax on a study model, in its desired final form, a silicone oral matrix is realized which includes the vestibular margin of the incisal edge.

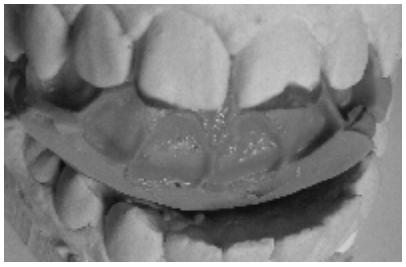

Figure no. 3. Aspect of teeth 11 and 21 after realising a slightly uneven bevel on the vestibular surface

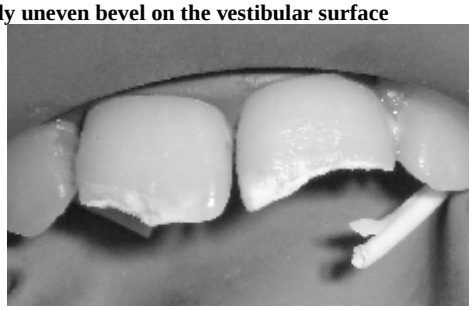

Dental materials used in dental office:

- Zeta Plus (Zermack Clinical)-condensation silicone (putty) and Oranwash L (Zermack Clinical)-for the dental mold and the silicone key.
- AHL Generic Prophylaxis Paste (Advanced Healthcare) – professional tooth brush paste
- Color key VitaPan Clasic (Vivadent)
- Rubber dam isolation system Optidam (KerrHave)
- Diamond bur of medium granulation
- Phosphoric acid 37% (3M ESPE)
- Adper Single Bond 2 (3M ESPE)-adhesive of the type demineralizing-washing
- Filtek Supreme XT (3M ESPE) – composite shades A2E, A2D, YT
- Elipar Freelight 2 (3M ESPE, 1000 mW/cm^2) – LED light curing unit
- Finishing and Polishing Discs (3M ESPE)
- Interproximal finishing strips (3M ESPE)

Figure no. 4. Oral view of the filling after a minimum vestibular finishing

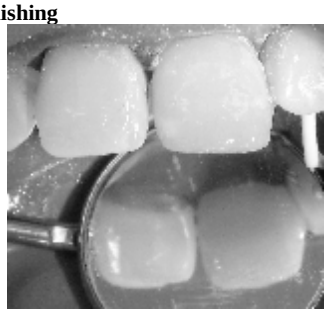

Figure no. 5. Final aspect

DISCUSSIONS

This technique allows a corresponding stratification with very little finishing and brushing(6), including the restoration contour and the position of the incisal edge.(7)

It is a simple conservatory restoration technique of the front teeth in young patients.(8)

A thorough knowledge of the technique, of the materials will help us choose the colors of the composite materials, of the stratification and of the surface structure.

CONCLUSIONS

This is a simple, minimally invasive method, which maintains tooth vitality, and ensuring a proper morphological recovery and an appropriate stratification of the composite material with outstanding aesthetic results.

BIBLIOGRAPHY

1. Vâlceanu A.S, Vârlan C.M., "Simultaneous aesthetical restauration of central fractured incisiors", Timişoara Medical Journal, Nr 2-3, 2006, pag. 222-225
2. Burlibaşa C., "Chirurgie orală şi maxilofacială", Editura Medicală, 2005, pag. 699-713;
3. Weistein AR,"Esthetic applications of restorative materials and techniques in the anterior dentition.", Dent Clin North Am., 1993, 37(3), pag. 391-409;
4. Hirata R., "A smile says more than a thousand words:

Reconstruction & modification of anterior teeth“, Cosmetic Dentistry Vol. 3, Issue 1, 2009, pag. 30-32;
5. Ardu S., Krejci I.,”Restaurații biomimetice din compozit pe dinții frontali”, Quintesence International România, 2006, Nr. 4, pag. 351-358;
6. Ritter AV, „Direct resin-based composites: curent recomandation for optimal clinical results”,Compendium, 2005, 26(7), pag 481-492;
7. Peyton J.H., „Finishing and polishing techniques: direct composite resin restorations”, Pract Proced Aesthet Dent, 2004, vol. 16, nr. 4 pag. 293-298
8. J. Fred Arnold, „Direct resin bonding for successful treatment of Class IV fractures: case report”, Dent Today, 2007, vol. 26, nr. 10, pag. 110-112.