

# THE ELECTRONEUROGRAPHIC EXPLORATION IN THE NEUROPATHIES ASSOCIATED WITH THE OBLITERATIVE CHRONIC ARTERIOPATHIES OF THE LOWER LIMBS

SANDA PATRICHI<sup>1</sup>, O. BĂJENARU<sup>2</sup>

<sup>1</sup>Clinical Rehabilitation Hospital, Cluj-Napoca, <sup>2</sup>"Carol Davila" University, Bucharest

**Keywords:** ischemic neuropathy, multiplex mononeuropathy

**Abstract:** This article aims to set a electroneurographic investigation grid for patients with ischemic pathology of the lower limbs and to assess the involvement degree of the peripheral nervous system at this patients. The electrophysiological investigation of 47 patients with chronic obliterative arteriopathy of the lower limbs showed that the decrease in CMAP amplitude is much more common in comparison with the decrease of VCM, suggesting a predominantly axonal impairment of the motor nerves. Both the motor action potential amplitude as well as the motor conduction velocity decrease differently on the studied nerves, fact that suggests the presence of multiplex mononeuropathy. A significant proportion of studied nerves are normal, sustaining the predominantly inhomogeneous effect on the peripheral nerves in ischemic neuropathy. With regard to sensory nerve damage, decreasing the potential amplitude is much more frequently encountered, in comparison with the decrease of the sensitive conduction velocity, suggesting the predominantly axonal impairing of the studied sensory nerves.

**Cuvinte cheie:** neuropatie ischemică, mononeuropatie multiplex

**Rezumat:** Articolul își propune să stabilească o grilă de explorare electroneurografică la pacienții cu patologie ischemică a membrelor inferioare și să evalueze gradul de interesare a sistemului nervos periferic la acești pacienți. Studiile electrofiziologice efectuate pe lotul de 47 de pacienți cu arteriopatie obliterantă au arătat că scăderea amplitudinii CMAP este mult mai frecvent întâlnită comparativ cu scăderea VCM, ceea ce sugerează o afectare predominant axonală a nervilor motori. Atât amplitudinea potențialului motor cât și viteza de conducere motorie scad în mod diferit pe nervii studiați, aspect care sugerează prezența mononeuropatiei multiplex. Un procent semnificativ din nervii studiați sunt normali, susținând afectarea predominant inomogenă a nervilor periferici în neuropatia ischemică. În ceea ce privește afectarea nervilor senzitivi, scăderea amplitudinii potențialelor senzitive este mult mai frecvent întâlnită, comparativ cu scăderea vitezei de conducere sensitive, sugerând afectarea predominant axonală a nervilor senzitivi studiați.

## INTRODUCTION

There is a real "obscurity" in the study of the peripheral nervous system involvement in the peripheral ischemic pathology. The reality of this level of damage requires thorough electrophysiological investigations in patients presenting chronic arterial disease of the lower limbs.

From a morpho-pathological point of view, although the peripheral nerve vascular architecture confers a high degree of resistance, both in chronic as well as acute ischemia, one encounters an axonal degeneration process of focal character of both the myelinated and the non-myelinated nerve fibers. One can also encounter a process of demyelination, secondary to axonal lesions or due to Schwann cell damage by ischemia. (3,5,13)

Clinically, the neuropathy associated with obliterative arteriopathy has been described through two patterns:

- as an **distal polyneuropathy**, more or less symmetrical, seen especially in high arterial damage (distal aorta, common iliac arteries, common femoral arteries). (1,4,11,20,21)
- as an **monomelic neuropathy or mononeuritis multiplex**, the spatial and temporal dispersion of neurological symptoms and electrophysiological change being related rather to phenomena of global ischemia than to a systemic disease, as it is in the case of polyneuropathies.

(1,3,4,6,14,18)

From the electrophysiological point of view, approximately the same issues are encountered: monomelic neuropathy, multineuropathy or distal polyneuropathy with more or less symmetrical distribution. In the case of ischemic neuropathy, electroneurography shows the decrease of the CMAP (compound muscular action potential) amplitude, the moderate increase of distal latencies, the also moderate decrease of motor and sensitive conduction velocities (MCV and SCV) and the increase of the F wave latency. (2,9,10,12)

Electromyography put in evidence anomalies in the sense of axonal loss (hence sharp positives and fibrillation potentials) in the intrinsic muscles of the leg and to a lesser extent in the anterior tibial, gastrocnemian and solar muscles, reduced recruitment (of neuropathic type) or lack of recruitment, as well as records of re-innervation (large motor unit potentials and / or polyphasic potentials), occurring several months after the lesion. (7,8,14,15,16)

## OBJECTIVES

This study aims to:

- to assess the degree of involvement of the peripheral nervous system in ischemic pathology, comparing the functional and clinical aspects.
- to establish an electroneurographic exploration grid (ENG)

<sup>1</sup>Corresponding Author: Sanda Patrichi, Clinical Hospital of Recovery, 46-50, Viilor street, Cluj-Napoca, România; e-mail: sandapatrichi@yahoo.com; tel +40-0744703366

Article received on 25.01.2010 and accepted for publication on 01.02.2010

ACTA MEDICA TRANSILVANICA June 2010; 2(2)199-202

## CLINICAL ASPECTS

in patients with ischemic pathology of the lower limbs.

### MATERIAL AND METHOD

47 patients with a diagnosis of chronic arterial disease of the lower limbs were included in the study, patients who were admitted in Clinical Rehabilitation Hospital of Cluj-Napoca. Based on a set of biochemical tests (which included ESR and determinations of blood sugar, cholesterol, triglycerides, urea, hemoglobin, hematocrit, WBC and platelets) were excluded those patients who presented a different etiology (other than ischemic) of the peripheral nervous system damage. The obliterative arteriopathy diagnosis was established clinically and through arterial Doppler examination of the lower limbs. The electrophysiological testing was performed with a Keypoint Portable type device, existent in the "Mircea Serban" Neuroelectrophysiology Laboratory of the Clinical Rehabilitation Hospital. The electroneurographic exploration grid comprised: the stimulus intensity at the maximum amplitude of the action potential, CMAP latency and amplitude at both the proximal and distal stimulation, the motor conduction velocity on the common peroneal and tibial nerves, bilaterally, as well as the latency and amplitude of SNAP and the sensitive conduction velocity on the sural nerve, bilaterally. The values obtained were compared with normal values for the parameters of existing record in the literature. Normal values for common peroneal nerve, stimulated distally on the ankle and proximally in popliteal fossa are considered more than 5 mV for potential amplitude and more than 42m/s for conduction velocity. For tibial nerve, stimulated in the same regions, normal values were more than 3 mV for potential amplitude and more than 41m/s for conduction velocity. For sural nerve were considered normal a potential amplitude greater than 3  $\mu$ V and a conduction velocity more than 42m/s. (7,8,12,17) The statistical processing of data was performed using SPSS program.

### RESULTS AND DISCUSSION


Out of the lot of 47 patients with chronic obliterative arteriopathy of the lower limbs confirmed through arterial Doppler examination, without other associated pathologies that could cause neuropathy, only one fifth (21.3%) were women. The median age in the lot was of 63,6 years.

From an electroneurographic point of view, in the case of neuropathy associated with chronic obliterative arteriopathy, one notices an amplitude reduction of CMAP (compound muscle action potential), a moderate increase of distal latencies and a moderate reduction of the motor (MCV) and sensitive (SCV) conduction velocity. Sensitive and motor conduction velocities are not significantly affected in some groups of patients (probably in early stages of the arterial disease), being predominantly axonal affected, or they may be slightly lower in other described groups of patients, the most likely explanation being the preferential loss of fast conduction, myelinated axons, fact supported also by some histological studies (5,6,18,20).

When the CMAP amplitude, which reflects the number of excitable nerve fibers (that it is consider in a semi-quantitative manner the number of fibers that respond to a maximal stimulus) decreases, it specifically and sensibly suggests an axonal damage. (Fig. 1.) In the case of neuropathy associated with chronic obliterative arteriopathy, it is lower in case of pain at rest, than in that of intermittent claudication, and there is a relationship between the degree of clinical impairment (pain intensity and character) and CMAP amplitude. (2,9,12) The reduction of CMAP amplitude in the symptomatic leg is the most prominent electrophysiological abnormality. The CMAP amplitude is a less sensitive parameter in the cases with moderate symptoms, due to its wide variation, even in normal

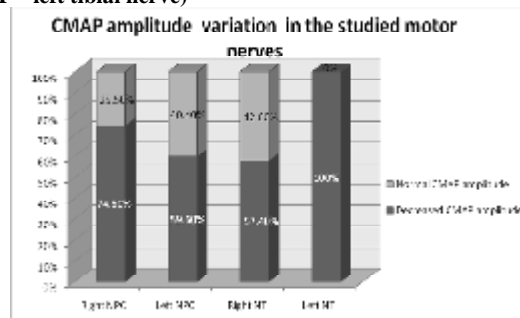
subjects (18,19,20).

**Figure no. 1. Patient BI, male, 52 years old, diagnosed with ischemic neuropathy, presenting a decreased CMAP amplitude in the left peroneal nerve**



In the studied group one found that there is an increased, irregular frequency of the compound muscle action potential decrease with percentages ranging between 59.6% and 100%, both in distal as well as proximal stimulation of the common peroneal and tibial nerves, bilaterally. This certifies axonal damage of the studied nerves and it is consistent with the previous data from literature. (Fig. 2.)

**Figure no. 2. Changes in CMAP amplitude in the studied motor nerves (CMAP - compound muscle action potential, Right NPC - right common peroneal nerve, Left NPC - left common peroneal nerve, Right NT - right tibial nerve, Right NT - left tibial nerve)**



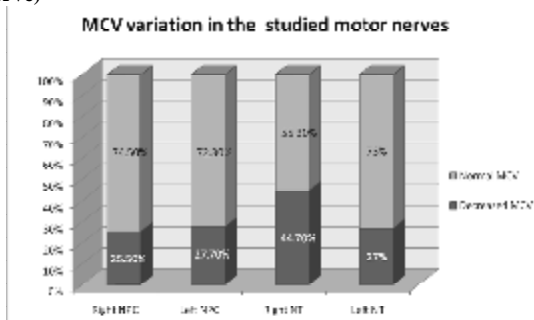
On the other hand, the decrease of motor conduction velocity (MCV) in the studied motor nerves occurs more rarely (ranging between 17% and 44.7%), suggesting that the process of demyelination is seen less frequently. To a certain extent, the decrease of conduction velocity can be explained by the impairment of large diameter axons, which transmit faster the impulses.(Fig.3)

Regarding the electroneurography on sensory nerves, previous research has shown that sensory nerve action potential (SNAP) on sural nerve is reduced or absent, depending on the degree of the damage to the investigated nerves. (Fig. 4.) In general, in most studies, sensitive nervous action potential of the sural nerve was absent but in some cases with lighter vascular impairment (intermittent claudication) it was present but with reduced amplitude. However SNAP is less sensitive for the ischemic neuropathy than the CMAP amplitude. (17,18,19)


Regarding the sensory impairment on our group of patients, there was a decrease of the SNAP amplitude (sensory nerve action potential), ranging between 66% and 68%, suggesting an axonal lesion of the sural nerves. (Fig. 5.) However, reduced sensory potential amplitude is rare in comparison with the low amplitude potential in the motor nerves, suggesting that the SNAP amplitude is less sensitive to ischemic neuropathy than CMAP amplitude.

## CLINICAL ASPECTS

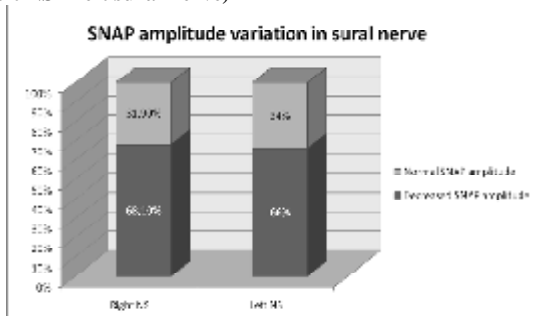
**Figure no. 3. MCV variation in the studied motor nerves (VCM - motor conduction velocity, Right NPC – right common peroneal nerve, Left NPC – left common peroneal nerve, Right NT – right tibial nerve, Left NT – left tibial nerve)**



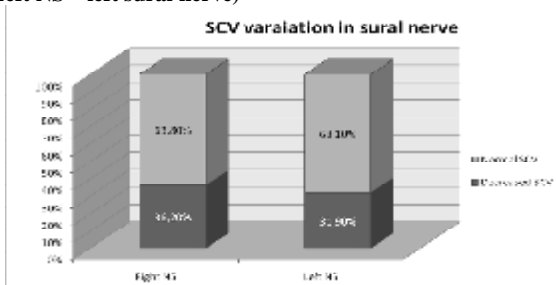
**Figure no. 4. Patient AM, male, 64 years old, diagnosed with ischemic neuropathy, which presents a decrease of SNAP amplitude in the right sural nerve**



**Figure no. 5. Sural nerve SNAP amplitude variation (SNAP - sensory nerve action potential, Right NS – right sural nerve, Left NS – left sural nerve)**



**Figure no. 6. SCV variation in the sural nerve (VCS – sensitive conduction velocity, Right NS – right sural nerve, Left NS – left sural nerve)**



The sensitive conduction velocity (SCV), measured on the sural nerves was lower in comparison with the normal values

(ranging between 31.9% and 36.2%), the most likely explanation being the preferential loss of fast conduction, myelinated axons. (Fig. 6.)

## CONCLUSIONS

The secondary impairment of peripheral nerves in chronic obliterative arteriopathy is frequently encountered in the current clinical practice. Clinically, the neuropathy associated with obliterative arteriopathy has been described through two patterns: as a polyneuropathy, with predominantly distal damage, more or less symmetrical, seen especially in high pressure disturbances (distal aorta, common iliac arteries, common femoral arteries) or a multiplex mononeuritis, where one considers that the unequal and asymmetrical distribution of nerves, the dispersion in space and time of the neurological symptoms and the electrophysiological changes are related to global ischemia phenomena rather than a systemic disease, as in the case of polyneuropathies.

Electrophysiologically, the same issues can be found: monomelic neuropathy, multilineuropathy or distal polyneuropathy with more or less symmetrical distribution. In the case of ischemic neuropathy electroneurography shows a CMAP (compound muscle action potential) amplitude decrease, a distal latencies moderate increase, the also a moderate decrease of motor and sensorial conduction velocities (MCV and SCV) and the increase of the F wave latency. Decreased CMAP amplitude is much more frequently encountered in comparison with the motor conduction velocity decrease. Both motor action potential amplitude and motor conduction velocity decrease differently in the studied nerves, which suggests the presence of the multiplex mononeuropathy. With regard to sensory nerve damage, it is of axonal or axonal-demyelinating type, one noticing mainly a decrease of SNAP amplitude and less frequently a decrease of SCV. A significant percentage of the studied nerves are normal, sustaining the predominantly inhomogeneous effect on the peripheral nerves in ischemic neuropathy.

## REFERENCES

1. Andary MK, Barinder SM. Ischemic Monomelic Neuropathy. eMedicine, Sept, 2007
2. Blum AS, Rutkove SB. The Clinical NeuroPhysiology Primer. Humana Press Inc., 2007
3. Cambier J, Masson M, Dehen H. Neurologie. ed. Masson , Paris, 2000
4. Candelise L, Hughes R, Liberati A, Uitdehaag B, Warlow C. Evidence-based Neurology:Management of Neurological Disorders. Blackwell Publishing, 2007
5. Câmpeanu E, Șerban M, Dumitru E. Neurologie Clinică. vol II, Ed. Dacia, Cluj-Napoca, 1980
6. Chroni E, Papapetropoulou V, Tsolakis J, et al. Chronic ischemic monomelic neuropathy from critical limb ischemia. Neurology. Jun 11 2002;58(11):1705
7. DeLisa JA, Lee HJ, Baran EM, Lai K, Spielholz N, Mackenzie K. Manual of nerve conduction velocity and clinical neurophysiology. Third Edition, Raven Press, New York, 1994
8. Faye Chiou Tan. EMG Secrets. Hanley & Belfus, Philadelphia, 2004
9. Fournier E. Examen electromyographique et etude de la conduction nerveuse- semiologie electrophysiologique. Ed. Technique et documentation, 1998
10. Fournier E. Atlas d electromyography. Technique et documentation, 2000
11. Laghi Pasini F, Pastorelli M, Beermann U, De Candia S. Peripheral Neuropathy Associated with Ischemic Vascular

## CLINICAL ASPECTS

---

- Disease of the Lower Limbs. *Angiology*, Vol. 47, No. 6, 569-577, 1996
12. Leis AA, Trapani VC. *Atlas of Electromyography*. 1st Edition, Oxford University Press, 2000
  13. Nukada H, Andre M van Rij, Packer S, McMorran D. Pathology of acute and chronic ischaemic neuropathy in atherosclerotic peripheral vascular disease. *Brain*, 1996, 119, 1449-1460
  14. Pabón Meneses R, Gila L, Urriza J, Imirizaldu L, Arrechea M, Lacruz F. Pseudo-conduction block in nonsystemic vasculitic neuropath. *An Sist Sanit Navar*. 2009 May-Aug;32(2):279-87.
  15. Pease WS, Lew HL, Johnson EW. *Johnson's Practical Electromyography*. Fourth Edition, Lippincott Williams and Wilkins, 2007
  16. Preston DC, Shapiro BE. *Electromyography and Neuromuscular Disorders, Clinical-Electrophysiologic Correlations*. Second Edition, Elsevier, 2005
  17. Ropper AH, Brown RH. *Adams and Victor's Principles of Neurology*. 8th ed., McGraw Hill, New-York, 2005
  18. Rossi CM, Di Comite G. The clinical spectrum of the neurological involvement in vasculitides. *J Neurol Sci*. 2009, Oct 15;285(1-2):13-21.
  19. Shy ME, Lewis RA. An approach to patients with peripheral neuropathy. *Continuum*, peripheral neuropathy, vol. 9, number6, dec. 2003
  20. Ugalde V, Rosen BS. Ischaemic Peripheral Neuropathy. *Phys Med Rehabil Clin N Am*, 2001. May, 12
  21. Weber F, Ziegler A. Axonal neuropathy in chronic peripheral arterial occlusive disease, *Muscle&nerve*, 2002, 26:471-476
  22. Weinberg DH, Simovic D, Isner J, et al. Chronic ischemic monomelic neuropathy from critical limb ischemia. *Neurology*. Sep 25 2001;57(6):1008-12.