AESTHETIC RECONSTRUCTIONS IN THE PREVIOUS JAW

V. NICOLAE [1], DANA DUMITRA[2]

[1,2] *"Lucian Blaga" University of Sibiu*

Keywords: *Zirconium Dioxide, aesthetical reconstructions, unidental implant*

Abstract: *For a practicioner with experience , the restoration with one or two individual crowns is relatively simple from clinical and technical point of view,but if a single cronw has to be rebuilt in areas with major aesthetic concern, the prosthetic restoration becomes a challenge for any team of professionals. A major challenge for such a team si the unidental restoration , with or without implants , of a single incisor from the frontal maxilar area , especially the central superior incisors. These teeth have ahighly aesthetic part since they are in direct connection with the shape and the aspect of the face. This connection is widely described in papers reffering to the principles of aesthetic integration , of aesthetical approach in the frontal fixed prosthesis or aesthetical analysis and systematical approach of the prosthetic treatment in the aesthetical rehabilitations through fixed prosthesis as emphasised in Rufenacht and Goldstein's works presented in the bibliography.*

Cuvinte cheie: *dioxid de zirconiu, reconstrucţii estetice, implant unidentar*

Rezumat: *Pentru un protetician cu experienţă, restaurarea cu una sau două coroane individuale este relativ simplă din punct de vedere clinic şi tehnic, dar dacă trebuie reconstituită o singură coroană în zone cu interes estetic major, restaurarea protetică devine o provocare pentru orice echipă de profesionişti. O provocare majoră pentru o astfel de echipă este restaurarea unidentară, cu sau fără implante, a unui dinte incisiv din zona frontală maxilară, în special a incisivilor centrali superiori. Acestor dinţi le revine un rol estetic foarte mare deoarece se află în relaţie directă cu forma şi aspectul feţei. Această relaţie este descrisă pe larg în tratate cu referire la principiile de integrare estetică, de abordare estetică în protezările fixe anterioare, sau de analize estetice şi abordare sistematică a tratamentului protetic în reabilitările estetice prin protezare fixă, aşa cum reiese din lucrările lui Rufenacht şi Goldstein, prezentate în bibliografie.*

INTRODUCTION

In the evaluation of the dental shape of the central incisors we can use different parameters which are closely related to the individual anatomical aspects of each patient: the shape and aspect of the face , the analysis of the existing casts or photos from the youthof the patient with the natural teeth. Finally, the decision is taken together with the patient after we establish the expectations and his possible personal demandings. We should not forget that, through the increasingly modern methods of mass media spreading, the patient is more curious and informed, consequently more demanding. All these requirements must be weight and if achievable, they will be analysed by the medical team then discussed with the patient.

CLINICAL CASES

In all the situations of prosthetical reconstruction of the frontal maxillary group, the main aim is to obtain a natural aesthetic of the white or soft tissue in the context of the occlusal-articular functioning. There are situations when a central incisor sufferes aesthetically from colour alterings, due to endodontic treatments or to the restorative failures unadapted to the prosthetical principles: acrylic crowns, metal- aclylic crowns, metal ceramic crowns older than 10 years or incorrectly adapted in the cervical area, or failures in the veneering of the vestibulary face of the frontals. *(Fig. 1)*

In these cases a butt joint margin preparation of the natural teeth is imposed or a correct subgingival preparation of the frontals already unaesthetically covered. (Fig. 2).The preparation around the neck of the abutment and the attitude towards the free gum and interdental papilae is very improtant in the achievment of anatural passage from the red gum to the white face or our crown.(Fig. 3)

Figure no. 1. Unaesthetic appearance of the upper front group(Archive Dr. V. Nicolae)

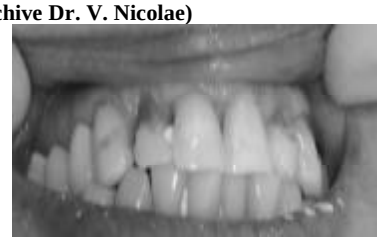

Figure no. 2. Prosthetic abutments prepared with threshold (Archive Dr. V. Nicolae)

[1]Corresponding Author: V. Nicolae, 44-46 Bl Victoriei street, Sibiu, România; e-mail: dento.medica@yahoo.com; tel +40-0721212878
Article received on 26.04.2010 and accepted for publication on 01.06.2010
ACTA MEDICA TRANSILVANICA September 2010; 2(3)301-303

Figure no. 3. Ceramic crown on zirconium oxide structure 1.1, with remarkable aesthetics. (Archive Dr. V. Nicolae)

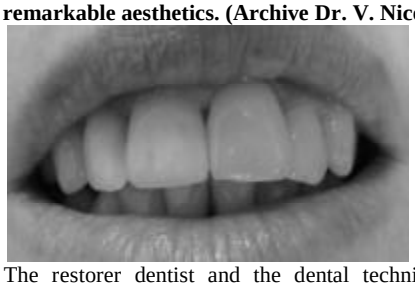

The restorer dentist and the dental technician and responsible for that white/red crossover from the shaped gum to the prosthetic crown which will cover the abutment.

The crowns, 8 years old, have caused stasis and a purple aspect of the gingical tissues and in the pasage from the red gum to the white face of the crown, the metal border was visible, which upsets the aesthetic perception of the patient and creates a visible handicap: his smile.

The crowns with composite veneerings do not last long , they get wasted in time, thus the borders of the metal crowns will be uncovered.

Meanwhile, the composite veneerings suffer from pigmentation through the aging of the material; in time, microporosities appear on the surface of the composite which retain the food pigments.

The presence of the metal borders in the cervix is more visible in the case of the patient with gingival smile when the level of the upper lip goes beyond the free edge of the cervix.

After the removal of the old prosthetic work, the conical prepared abutments are visible with the massive distruction of the crown, a completely unprofessional preparation.

In such situations, we are forced to reconstruct the abutments after Xray examination. Through the direct composite restoration and appliance of the root pins armed with glass fiber , the abutments have gained the desired prosthetic shape.

The abutments require a strong preparation with well calibrated borders around the cervix (1,5 mm) which out of aesthetic considerations have been done slighly subgingival.

The reconstruction of the two crowns has been done on a ceramic without a metallic component, but not through the pressing technology as known in the integral ceramic system , but through the CAD/CAM technology, based on the layer application of the ceramics of fluor apatitis on caps prepared through pressing techniques.

In the impression, the limits of the preparation must be marked with precision, thus all the data will be correctly tranferred to the dental technique laboratory *(Fig.4).* In the laboratory the provisional restoration is immediately created and it will be tranferred to the patient.

After the wax model of the cap, it is fixed and pressed in an oven from a ceramic type „1PS max CEM" constantly checking the precision of the marginal closing up.

Then the veneering and lamination of the dentinary, enamel and incisal structures follows with mmax CERAM until the modelling of the final shape.

After the final burning the shape and superficial structure have been optimised and the gloss after which it has been polished. For the acokplishment of the patient's demandings he is invited to take part in the final steps of the work. After the isolation of the prosthetic field with a rubber dam, the abutments are cleaned, skimmed and conditioned with acid then covered with adhesive. The polimerization in the adhesive cements is done with the photopolimerisable lamp. The crownd should not be bonded in the same time and the margin is closely checked for the removal of any cement remainings.

Figure no. 3. The polieter impression with the limits of the preparation precisely marked

The reconstruction of the superior centrals with zirconium structures computer made CAD/CAM. The precision and the productivity of these materials, as well as the technology, have evolved in the past years and they can satisfy even the highest aesthetical and functional demands of the patients. Almost every producer of the CAD/CAM systems (Lava, Cercon, etc), uses a certai type of zirconium for the preparation of the framework. For every type of framework there is a matching ceramics, which means that the structures must be covered with a certain ceramics. (Fig, 5, fig. 6, fig. 7, fig. 8)

Figure no. 5. Structures of zirconium and metal (Cr-CO) obtained by CAD-CAM technology. (Archive Dr. V. Nicolae).

The reconstruction of a frontal central incisor after its loss due to an endodontic failure finalised with the longitudinal fracture of the root. In this case there are problems connected to the bone loss and the asimmetries.

Even if the prosthetic restoration corresponds to the current technological demandings (high tech implants, optimal surgical techniques, zirconium abutments, ceramic crowns on zirconium), when we have bone loss and assimetry in the gingival border by comparisson to the natural tooth, an acceptable functionnal intergration is created but the aesthetic result is not satisfactory.

Figure no. 6. Different aspect of the brightness of two framework applied ceramics(Archive. Dr. V. Nicolae)



Here, when we talk about aesthetisc, we reffer to the passage between the red gum and the white tooth, the emergence level of the crown on the implant comparing to the cervical width of the similar natural tooth, to the black points and the papila level, the vestibulary excavation next to the implant. *(Fig. 9, 10, 11, 12).*

Figures no. 7 and 8. Upper front work group recovery through ceramic structure zirconium.(Archive Dr. V. Nicolae)

Figure no. 9. Sample structure of zirconium. (Archive Dr. V. Nicolae)

Figures no. 10 and 11. The final aspect of the work on the structure of yirconia ceramic. (Archive Dr. V. Nicolae)

Figure no. 12. Failure in the passage from the red aesthetics to the white one

CONCLUSIONS

Without doubt, more and more prosthetic cases, with or without implant solutionings become increasingly complex from the aesthetical, functionality and quality point of view, for the team consisting of the prosthetician, dental technician, implantologist, hygienist.

To obtain a remarkable result regarding the functionnal and the aesthetic, an imperative requirement is the team work where all the experience of the participants is manifested and put into practice.

REFERENCES

1. Rufenacht C.R.: Principii de estetică. Ştiinţă şi tehnică dentară. (Principi di estetica. Scienza e tecnica dentistica. Ed. Int. Mailand 1992)
2. Rufenacht C.R.: Principii de integrare estetică. Ştiinţă şi tehnică dentară. (Principi di integrazione estetica. Scienza e tecnica dentistica. Ed. Int. Mailand 2001)
3. Goldstein R.E.: Aspecte estetice în stomatologie (Estetica in odontoiatria. UTET Turin 2004)
4. Fradeani M.: Reabilitare estetică prin proteze fixe. Analiza estetică, abordarea sistematică a tratamentului protetic. (La reabilitazione estetica in protesi fissa. Analisi estetica, approccio sistematico al trattamento protesico Vol.1. (2004): kapitel 2: 35-56 Quitessenza editioni srl.).