

## THE BRANCHES OF THE AORTIC ARCH. THREE CASE PRESENTATIONS OF THE ANATOMICAL VARIANTS

C. MIHALACHE<sup>1</sup>, M. GORUN<sup>2</sup>, MANUELA MIHALACHE<sup>3</sup>

University "Lucian Blaga" of Sibiu

**Keywords:** aortic arch, brachiocephalic trunk, left common carotid artery, left subclavian artery

**Abstract:** The branches of the aortic arch, according to the classic anatomical description are represented by the brachiocephalic trunk (BCT) being the largest of the vessels, left common carotid artery (LCC) and left subclavian artery (LS). The origin of the LCC artery is more to the left close to the origin of the LS. However this configuration is only present in 80% of the cases, variations in the disposition of the 3 "classic" branches or the number of arteries arising from the arch can occur (4) The presence of anatomical variations is very close related to the abnormal development of the aortic arches, and development of the heart in the embryonic life. The paper presents 3 cases of variants in the classic configuration of the branches of the aortic arch. In 2 of the cases the left vertebral (LV) artery arises from the aortic arch, between the left common carotid artery and the left subclavian artery: one case in a 7 month spontaneously aborted human foetus, and one in an adult. In the third case, the left subclavian artery was the largest of the 3 vessels and the origin of the brachiocephalic trunk and left common carotid arteries are very close.

**Cuvinte cheie:** arc aortic, trunchi brahiocefalic, artera carotidă comună stângă, arteră subclaviculară stângă

**Rezumat:** Ramurile arcului aortic, conform descrierii anatomice clasice sunt reprezentate de trunchiul arterial brahiocefalic (TaBC), fiind cea mai voluminoasă ramură; artera carotidă comună stângă (CCS) și artera subclaviculară stângă (SS). Această dispoziție este prezentă în 80% din cazuri, variații ale configurației clasice a celor 3 ramuri sau variații privind numărul ramurilor pot fi prezente. (4) Prezența variantelor anatomice este foarte strâns legată de dezvoltarea anormală a arcurilor aortice, și dezvoltarea inimii în viața intrauterină. Această lucrare prezintă 3 cazuri de variații de la dispoziția clasică a ramurilor arcului aortic. În două din cazuri, unul la un făt în luna a 7 de gestație și unul la un adult, artera vertebrală stângă (VS) ia naștere de la nivelul arcului aortic, între emergența arterei carotide comune stângi și artera subclaviculară stângă. În al treilea caz, artera subclaviculară stângă reprezenta cea mai voluminoasă ramură a arcului aortic.

### INTRODUCTION

The aortic arch and the branches that arise from the aortic arch are subject to numerous variations; depending on the type of anatomical variation there can be no detrimental effects present for the subject, or hemodynamic consequences can appear due to a vicious formation.

There are many authors treating this subject, and numerous anomalies and variation in the disposition of the branches from the aortic arch are reported at different rates of incidence. In the past, a key role in uncovering anatomical anomalies and variants was through dissection, but nowadays these discoveries are made during complementary medical examinations.

Either way it is essential to know the anatomical configuration and the most frequent variants that may occur.

### EMBRIOLOGICAL REFERENCES

The development of the blood vessels is made during the process of vasculogenesis and angiogenesis, from which the dorsal and ventral aortas result, that are connected by the aortic arches. These arches develop in close relation with the evolution of the pharyngeal arches. The aortic arches originate from the aortic sack, the most distal portion of the arterial trunk. They have a transitory aspect; some will disappear completely;

rapidly changing the symmetrical disposition of the vessels into an asymmetrical form.(1)

The 3<sup>rd</sup>, 4<sup>th</sup> and 6<sup>th</sup> aortic arches are the largest and will form the great arteries of the body.

The aorta is formed by different structures of the embryonic arterial system. The ascending aorta is formed from the arterial trunk. The aortic arch develops from the aortic sack, together with the brachiocephalic trunk. The aortic arch from the origin of the common left carotid artery and the origin of left subclavian artery is formed by the 4<sup>th</sup> aortic arch.(1,8)

The 3<sup>rd</sup> aortic arch is responsible for the formation of the common carotid artery. The 4<sup>th</sup> aortic arch will give rise to different structures. On the left side a segment of the aortic arch, and on the right side the right subclavian artery.

Any segment of the embryonic aortic arch system can regress or persist abnormally, resulting in an extensive array of aortic arch variations or anomalies.

The 6<sup>th</sup> aortic arch is responsible for the development of pulmonary arteries, and the ductus arteriosus. (1,8)

### THE BRANCHES OF THE AORTIC ARCH IN LITERATURE

The aortic arch continues the ascending aorta, curves around the peduncle of the left lung, and measures about 25- 30 mm in diameter at the origin, and about 20-25 mm at the isthmus

<sup>3</sup> Corresponding Author: Manuela Mihalache, Faculty Medicine "Victor Papilian" Sibiu, 2A, Lucian Blaga street, Sibiu, România, e-mail: manuela.mihalache@ulbsibiu.ro, tel +40 (269) 21.23.20


Articol received on 29.06.2010 and accepted for publication on 27.09.2010

ACTA MEDICA TRANSILVANICA December 2010; 2(4)225-227

## CLINICAL ASPECTS

segment, after the issue of its large collateral branches. The BCT is the first branch from the aortic arch, and it is the largest. The BCT originates a little to the right from the midline of the body. The LCC is the second branch of the aortic arch, originating from the highest point of the arch. Its origin is closer to the origin of the BCT. The LS is the 3<sup>rd</sup> branch of the aortic arch, the most posterior, covered partially by the LCC.(4,6)

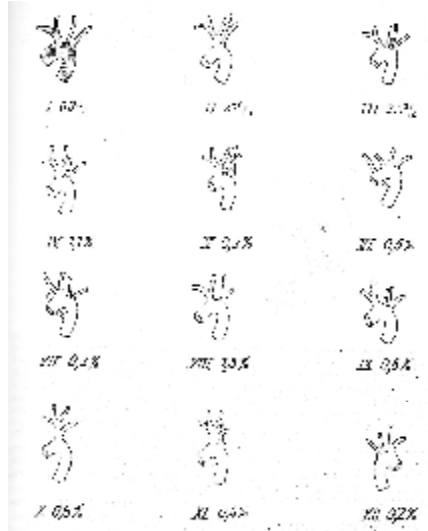
**Figure no. 1. The classic disposition of the branches of the aortic arch, heart in situ. 1. BCT, 2. LCC, 3. LS arteries**



The first anatomical description of an anomaly of the aortic arch was made in 1737 by Hommel (6). Since then there were described very many variations and anomalies. Nizankowski, C., Rajchel, Z. and M. Ziolkowski in 1975 described 25 possible combinations in origin and position of the branches from the aortic arch.(2)

Pop D. Popa admits 12 variants, the “classic” disposition being stated to be present in 65% of the cases.(6)

**Figure no. 2. Variants of the aortic arch, described by Pop D. Popa**



### MATERIAL AND METHOD

This paper is part of a larger study that tries to establish the incidence of the aortic arch variants and anomalies in the population of Sibiu county. We present relevant aspects of what we have found so far in our study.

The study is made on fresh cadavers, dissected during autopsy. The aortic arch together with the branches that emerge from it is prelevated and formol fixed. The aspect and diameter

of the aortic arch, the origin of the branches from the aortic arch and their diameter is inspected, measured and photographed immediately after the prelevation to avoid postmortem damaging of the tissues.

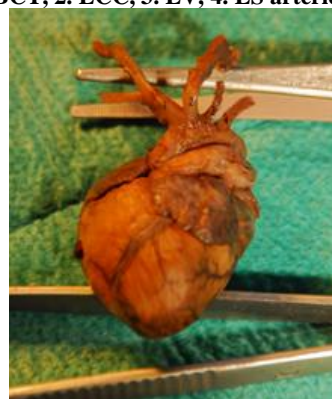In the study there were also dissected 14 formol fixed aborted human foetuses, between 6<sup>th</sup> and 7<sup>th</sup> month of gestation, with the purpose of finding similar variants. The fetuses were measured from vertex to coccyx to estimate the gestation age.

### RESULTS

#### • THE VERTEBRAL ARTERY - AORTIC BRANCH

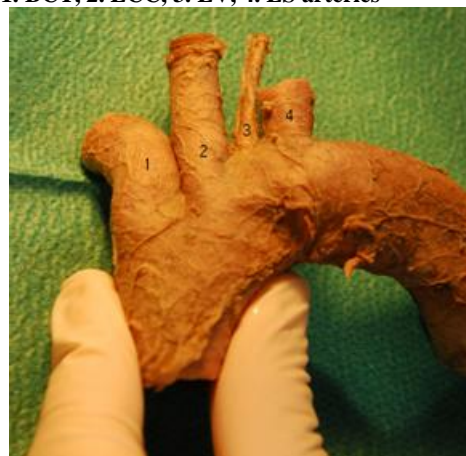The vertebral artery is normally issued from the subclavian artery, as the first large collateral branch. We discovered during dissection, in a 7<sup>th</sup> month of gestation aborted human foetus, the left vertebral artery arising from the aortic arch, between the origin of the LCC and LS. This is described in anatomical literature to be present in an incidence of 2,5 – 5% (2,5,6,7). Cases with right vertebral artery arising from the aortic arch are very rare.

**Figure no. 3. Fetal heart and aortic arch, 7<sup>th</sup> month of gestation. 1. BCT, 2. LCC, 3. LV, 4. LS arteries**



Also in one adult the LV artery originated from the aortic arch. The diameter of the aortic arch was 28 mm at the origin and 22mm in the isthmus segment. The BCT had a diameter of 14 mm, the LCC was 9mm in diameter and the LS 10 mm. The LV artery had a diameter of 3,7 mm.

**Figure no. 4. Aortic arch in adult showing the origin of LV artery 1. BCT, 2. LCC, 3. LV, 4. LS arteries**



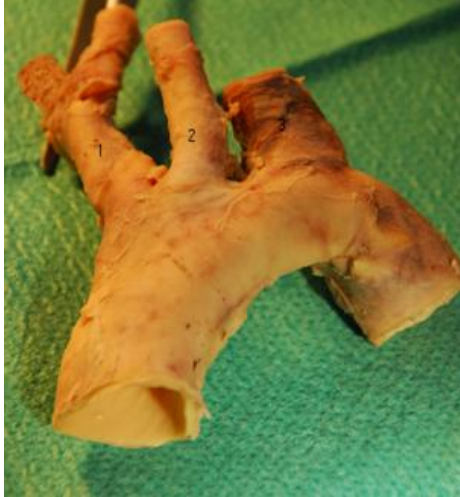#### • THE LEFT SUBCLAVIAN ARTERY THE LARGEST BRANCH

The largest branch of the aortic arch is the BCT. In one 47 year old male, the largest branch originating from the aortic arch was the LS artery. The BCT had 10mm in diameter.

## CLINICAL ASPECTS

The LCC artery was 7,5mm in diameter while the LS measured 13mm. The diameter of the aortic arch measured 23mm at the origin, and 20,5mm at the isthmus segment.

**Figure no. 5. The aortic arch showing the LS artery as the largest branch. 1. BCT, 2. LCC, 3. LS arteries**



### DISCUSSION

The cardiovascular system is the first organ system to reach a functional state. Due to its rapid evolution abnormalities and variations can occur. The complex formation process of the vessels originating from the aortic arch is very fragile and any segment of the aortic arch can persist or regress abnormally.

McElhinney and Goldmuntz incriminate genetic factors in the apparition of this kind of modifications. They identified a deletion of 22q11, being responsible for some cases of aortic arch anomalies.(3)

The vertebral artery can originate from the LS artery (classic description of the artery), the LCC artery or the aortic arch. The most frequent variation is that of the origin of LV artery from the aortic arch, being considered at an incidence of 2,5 – 5%. (2,5,6,7)

No representative data was found regarding the case in which the LS artery was the largest branch from the aortic arch.

### CONCLUSIONS

- Variations in the number of the branches originating from the aortic arch or abnormal morphology of the branches can be associated with alterations in the hemodynamic physiology,
- The anatomical disposition of the branches of the aortic arch, and being aware of the possibility of anatomical variants has serious importance in the medical procedures (surgical, complementary investigations)
- Although there are many reports of anatomical variants regarding the aortic arch, the complexity and multiple entities of variants makes it difficult to cover all the possibilities of branching in anatomical descriptions, that is why future studies of the variability of this segment of arterial system are essential.

### REFERENCES

1. L. Bareliuc, N. Neagu, Embriologie umană normală și patologică, editura Medicală, București 1987
2. Ronald A. Bergman, Adel K. Afifi, Ryosuke Miyauchi, Aorta: Arch and Thoracic part of the Descending Aorta, Illustrated Encyclopedia of Human Anatomic Variation:

- Opus II: Cardiovascular System: Arteries: Head, Neck, and Thorax (Nizankowski, C., Rajchel, Z. and M. Ziolkowski. Abnormal origin of arteries from the aortic arch in man. Folia Morphol. 34:109116,1975) <http://www.anatomyatlases.org/AnatomicVariants/Cardiovascular/Text/Arteries/Aorta.shtml>
3. Doff McElhinney, Elizabeth Goldmuntz, Abnormalities of the aortic arch, <http://www.orphanet.net/data/patho/GB/uk-aortic-arch.pdf>
4. Gray's Anatomy, The Anatomical Basis of Medicine and Surgery, 38<sup>th</sup> edition, Churchill Livingstone 1995
5. Il-Young Shin, Yong-Gu Chung, Won-Han, Shin, Soo-Bin Im, Sun-Chul Hwang, Bum-Tae Kim, A Morphometric Study on Cadaveric Aortic Arch and Its Major Branches in 25 Korean Adults : The Perspective of Endovascular Surgery, J Korean Neurosurg Soc 44: 78-83, 2008<http://www.ncbi.nlm.nih.gov/pmc/articles/PMC2588331/>
6. Pop D. Popa Sistemul arterial aortic – Patologie și tratament chirurgical, vol. I, Editura Medicală, București 1982
7. Sandra Morovic, Tatjana Skaric-Juric, Vida Demarin Morphologic and hemodynamic characteristics of vertebral arteries in men and women <http://hrcak.srce.hr/file/26965>
8. T.W. Sadler Langman's Embriologie Medicală, Editia a 10-a, editura medicala Callisto 2005