

## BRYAN-MORREY APPROACH – SURGICAL TECHNIQUE

A. B. CIUBARĂ<sup>1</sup>, B. F. PUHA<sup>2</sup>, O. ALEXA<sup>3</sup>

<sup>1,2,3</sup> Clinical Emergency Hospital "Sf. Ioan" Iași

**Keywords:** Bryan-Morrey approach, humerus distal fracture, surgical technique

**Abstract:** This article aims to offer an alternative to the classic transolecranon approach, that is used in the surgery of the distal humerus. This possibility for the access to the pathology of distal humeral blade is recommended by the AO (Arbeitsgemeinschaft für Osteosynthesefragen) school as an alternative for the transolecranon approach. Big clinics from Europe (1,2) use the Bryan-Morrey approach at the expense of transolecranon approach for distal humerus fractures, leading to the academic dispute on randomized studies. However, the choice of the approach remains to the surgeon preference. We will show in the following lines the surgical technique for this approach and we will try to expose some personal considerations about the advantages and disadvantages of this technique, regarding to the experience of 71 cases

**Cuvinte cheie:** abordul Bryan-Morrey, fractura de humerus distal, tehnici chirurgicale

**Rezumat:** Acest articol își propune să ofere o alternativă la abordul clasic, transolecranian, folosit în chirurgia humerusului distal. Această variantă de acces spre patologia paletii humerale este recomandată de către școala AO (Arbeitsgemeinschaft für Osteosynthesefragen), ca alternativă la abordul transolecranian. Clinici de renume din Europa (1,2) folosesc abordul Bryan-Morrey în fracturile humerusului distal în detrimentul abordului transolecranian, ajungându-se la dispute academice argumentate pe studii randomizate. Cu toate acestea, alegerea căii de abord rămâne la latitudinea preferințelor chirurgului. Vă vom prezenta în rândurile următoare tehnica chirurgicală și vom încerca să expunem câteva considerații personale privind avantajele și dezavantajele acestei tehnici având în vedere o experiență de 71 cazuri.

### THE AIM OF THE STUDY

This article aims to offer an alternative to the classic transolecranon approach, that is used in the surgery of the distal humerus. This possibility for the access to the pathology of distal humeral blade is recommended by the AO (Arbeitsgemeinschaft für Osteosynthesefragen) school as an alternative for the transolecranon approach. Big clinics from Europe (1,2) use the Bryan-Morrey approach at the expense of transolecranon approach for distal humerus fractures, leading to the academic dispute on randomized studies. However, the choice of the approach remains to the surgeon preference. We will show in the following lines the surgical technique for this approach and we will try to expose some personal considerations about the advantages and disadvantages of this technique, regarding to the experience of 71 cases.

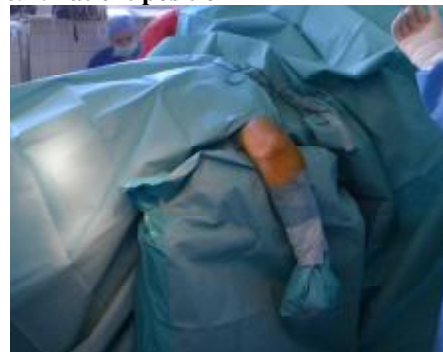### MATERIAL AND METHODS

In this study 71 cases were selected for this surgical technique. The patients' age was between 20 and 76 years and the average age was 44.8 years. The distribution on sexes was 2:1, 48 men and 23 women. There was no criteria used to choose the cases that was used Bryan - Morrey approach. The type of the fractures treated by this approach were A2.1, A2.2, A2.3, A3.1, A3.2, A3.3, C1, C2 and C3 (AO classification).

**Bryan-Morrey approach.** The patient can have regional anesthesia or general anesthesia, the authors preferring the last one. The patient is positioned on the surgical table in lateral or ventral decubitus (ventral preferably). The upper limb is suspended on support that is positioned to the fold of the

elbow. The forearm is flexed on the arm at 110° (fig.1)(3,4). The approach starts with a skin incision beginning at 14-16 cm above the olecranon tip and extends distal from the olecranon tip, intersecting it, with another 4-6 cm along the cubital ridge (fig.2).

Figure no. 1. Patient position



Cut the superficial fascia and subcutaneous tissues. Found the cubital nerve and isolate it (Fig. 3) with a compress soaked with saline (note: do not turn the nerve when the compress is inserted.) or with a surgical marker. Make a flap with an incision along the medial edge of the triceps muscle. The incision have to interest all the tissues, including the periosteum. The incision crosses the cubital bone from the medial to lateral. Make the desinsertion of the triceps muscle with a fine chisel (fig.4)(do not use the scraper).

<sup>1</sup>Corresponding Author: B. Ciubara, 7, Rufeni street, Iași, România; e-mail: abciubara@yahoo.com; tel +40-0744212518  
Article received on 29.11.2010 and accepted for publication on 02.05.2011  
ACTA MEDICA TRANSILVANICA June 2011; 2(2)273-275

## CLINICAL ASPECTS

Figure no. 2. Incizion

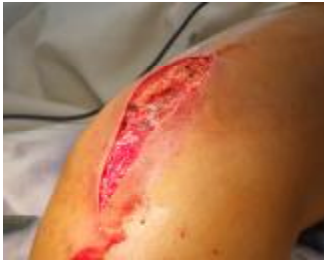

Figure no. 3. Preparation of the cubital nerve

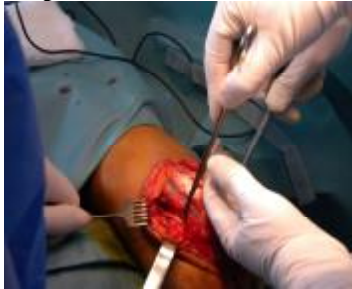

Figure no. 4. Desinsertion of the triceps muscle

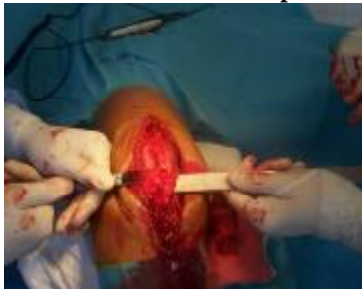

Figure no. 5. Joint view

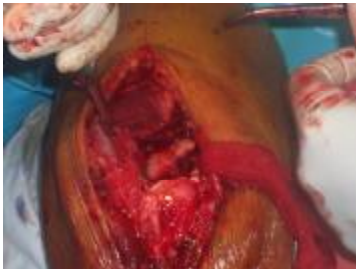
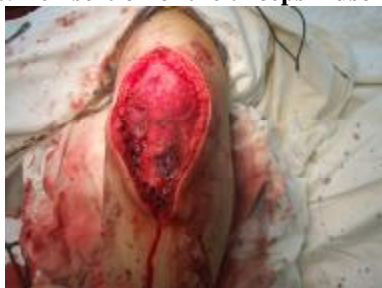
Figure no. 6. Reinsertion of the triceps muscle

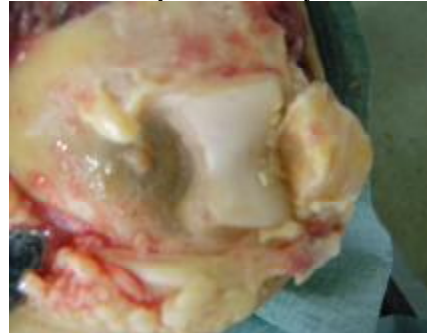


The flap should be raised with a fine portion of bone, to ensure a quality rehabilitation of the triceps muscle. Make the triceps reflection for obtaining the access to the distal humerus (fig.5,7). The approach can be completed with the osteotomy of the peak of olecranon (about 1 cm) (fig.8), to get a better view of the articular surface.

Figure no. 7. Triceps reflection

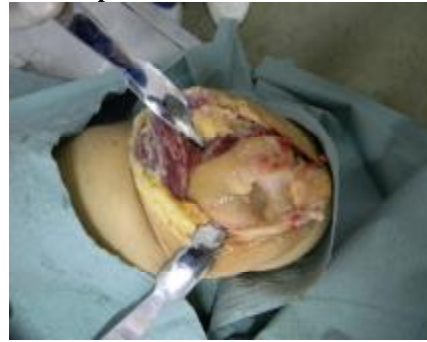

Figure no. 8. Olecranon peak osteotomy



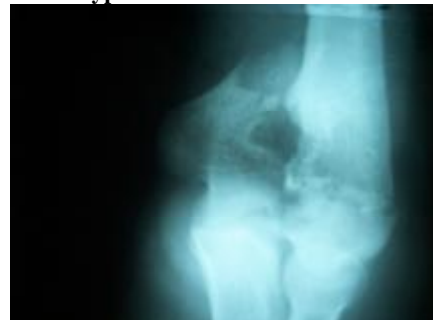After ORIF the triceps flap is tilted back and the edges are sutured with nonresorbable wires. The reinsertion is completed with the introduction of a clamp in the olecranon (respecting the anatomy) (fig.6).

### RESULTS AND DISCUSSIONS

Patients operated by this method had positive developments. There were respected the principles for the functional rehabilitation in the distal humerus surgery. Therefore patients have benefited by a splint immobilization with analgesic effect for 14 days, this time continuing the rehabilitation program specialist working office.

A case (Fig.9, 10) that had a C3 fracture that required bone substitute and temporary joint synthesis was immobilized with plaster splint for 2 weeks. After the suppression of the splint begin the functional rehabilitation.

Figure no. 9. C3 type fracture



Because of the multifragmentary aspect of the fracture the external column wasn't fixed (fig.11,12).

In a case with a type A2.2 fracture and diaphysal extension of fracture we encountered difficulties with the acces to the proximal fragment. Please note that this case has an impressive muscle mass which make relatively difficult the triceps reflection.

One case was excluded from the study because was found a secondary infection with unknown etiology.

## CLINICAL ASPECTS

Figure no. 10. C3 type fracture

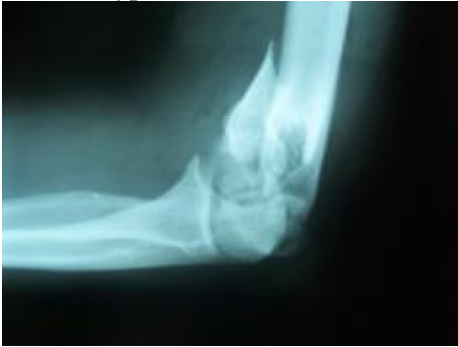

Figure no. 11. Postoperative results

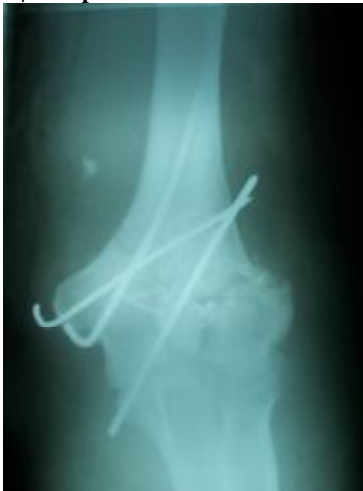
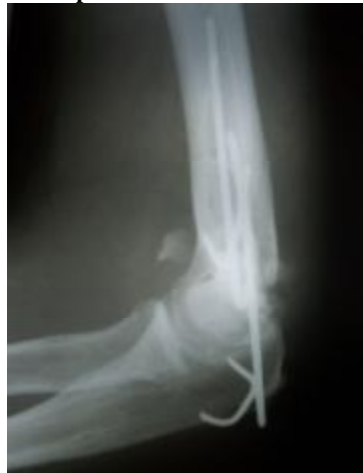
Figure no. 12. Postoperative results



Patients were regularly observed for 6 months. They were assessed at 2 weeks, 4 weeks, 3 months and 6 months postoperatively. It was noticed the patient's subjective assessment (pain, functional capacity-especially prehension) and objective assessment: flexion-extension, pronation-supination. The results were compared to those obtained in patients that were operated by transolecranon approach. It was noted that cases operated by Bryan-Morrey approach subjectively appreciate that functional rehabilitation was easy and objective we found at 3 months after surgery flexion, extension and pronation-supination were better recovered compared with cases operated by transolecranon approach.

In addition to these two ways to approach can be used the transtricipital approach. Please note that this approach can be

used only in fractures type A because the visualization of the joint surface is poor and also the internal access to the medial pillar is impossible. The choice of approaches is at the discretion of each surgeon, each of them have arguments and counterarguments. Therefore almost all authors agree that it would be good to avoid olecranon osteotomy because this is a further assault on the elbow joint, making the recovery process more difficult and longer.

### PERSONAL CONSIDERATIONS

The Bryan-Morrey approach is still current and should not be abandoned. The great advantage is that it avoids the olecranon osteotomy, which involves less osteosynthesis material. Quantifying postoperative pain on a subjective scale from 1 to 10, cases operated by this technique have described the pain around 2-3 and cases operated by transolecranon approach described the pain around 4-6. It results an easy rehabilitation and more comfort for the patients during the postoperative period.

Therefore, we recommend the use of this approach, according to AO classification, to the following types of fractures: A2.1, A2.2, A2.3, A3.1, A3.2, A3.3, C1, C2. For C3 type can be used this approach, but when the joint surface is multifragmentary this approach can be a disadvantage. This approach can be used also for the type B1 and B2 fractures (5), especially in fractures that have a large joint involvement. Do not use in B3 fractures. We do not recommend the using of this approach in cases with large muscle mass and diaphysal fracture extension.

### BIBLIOGRAPHY

1. Remia LF, Richards K, Waters PM., The Bryan-Morrey triceps-sparing approach to open reduction of T-condylar humeral fractures in adolescents: cybex evaluation of triceps function and elbow motion. *J Pediatr Orthop.* 2004 Nov-Dec;24(6):615-9.
2. Ruedi T, Murphy WM (2000) *AO Principles of Fracture Management.* Vol. 1. Thieme: Stuttgart-New York.
3. Brian RS, Morrey BF. Extensive posterior exposure of the elbow: a triceps-sparing approach. *Clin Orthop* 1982, 166 : 188.
4. Morrey BF. Limited and extensile triceps reflecting exposure of the elbow. In morrey BF, ed : *Master techniques in orthopedic surgery : the elbow*, NY, Raven Press limited, 1994 : 3-19.
5. Launay F, Leet AI, Jacopin S, et al (2004) Lateral humeral condyle fractures in children: a comparison of two approaches to treatment. *J Pediatr Orthop*; 24:385-91.