CORONARY SUBSTITUTION: 25 YEARS OF CLINICAL RECOIL

VALERIA COVRIG[1], ANCA FRĂȚILĂ[2]

[1]University „Vasile Goldis"Arad, [2]University „Lucian Blaga" of Sibiu

Keywords: *nopulp teeth, corono-radicular restauration, clinical behavior*

Cuvinte cheie: *dinți depulpați, substituție coronară, recul clinic*

Abstract: *Practitioners restore teeth with various degrees of coronary destruction to restore functionality. The most problems are raised by large coronary destructions or corono-radicular destructions. The history of restorative techniques dates back a long time. Almost to this day these techniques have been limited to Richmond's substitution crown. At the present time, due to clinical progress, but mainly to technical progress, the array of methods and materials used in restorations is considerable more varieted. In this article we are presenting a summary of our 17 year old experience in restoring teeth using cost or preformed D. C. R/s.*

Rezumat: *În activitatea clinică, practicienii restaurează dinți cu diverse distrucții coronare în vederea reabilitării morfofuncționale. Cele mai mari probleme le pun distrucțiile coronare mari sau corono-radiculare. Istoria tehnicilor de restaurare a acestor dinți este foarte veche. Aproape până în zilele noastre ea s-a rezumat la folosirea coroanei de substituție a lui Richmond. La momentul actual datorită progreselor clinice, dar mai ales tehnice, gama metodelor şi materialelor de restaurare a acestor dinți este foarte variată. În cadrul acestei lucrări mi-am propus să expun experiența noastră clinică rezultată în urma unui studiu de 25 de ani asupra dinților restaurați cu dispozitive corono-radiculare turnate şi prefabricate, metalice.*

INTRODUCTION

Practitioners in their activity restore teeth with different coronary destructions. Those that pose a particular challenge are teeth with large coronary destructions, or even coronal and root destructions teeth that underwent endodontical treatment (1.15). Restoration of these teeth is usually performed with cast or prefabricated root or coronal anchored devices that are designed to ensure retention of the final fixed prosthesis and transmit the occlusal strains to the remaining dental tissue. (3.16) The root portion of the devices is aggregated to the dental tissues that suffered destructions by: caries development, endodontic treatments (which are becoming less conservative), preparation of stump for DCR's, etc.. (2, 17) In addition, these tissues are subjected to fluid loss and dessication, fluid provided by the living pulp, thus, decreasing the amount of water in the dentin, which decreases elasticity and increases the amount of minerals. (4, 11) These are all prerequisites for root cracks and fractures during the aggregation of these types of devices or at later time during the functions and parafunctions. (14)

Many questions arise during the study of the literature regarding techniques to restore endodontically treated teeth.(5, 8). This led to the division of practitioners in three categories: some recommended the use of root aggregated devices in all cases because it would strengthen the tooth root, others totally disapprove to this idea, arguing that the technique requires an additional removal of tissue, creating fractures premises. (9, 13) A third category supports their role in the retention of fixed, long term restorations. (10, 12, 15) With this in mind we decided to undertake a comprehensive in vivo study on a number of 1260 clinical cases and 1860 devices, over a period of 25 years. The paper presents some suggestive cases from the studied group, starting from the diagnosis to treatment indication to the manufacturing and aggregation technique of a wide variety of root anchored devices. Most of the cases were successful cases, others were cases of failure.

CASE PRESENTATION

Clinical case no. 1

Patient P.I., 26 years old, arrived at the dental office in 1997 with a massive coronary lesion of the lateral incisor (2.2.) and satisfactory prosthetic and odontal restorations. After checking the quality of the endodontic fillings, the indication for a cast metal root anchored device and a cast mixed metal-composite crown was given. The coronal part of the root was prepared according to classical techniques, the removal of the altered dentin was done with Peeso burs and an anti-rotation slot was also conformed. (Fig.1.1).

Figure no. 1. 1. No 1 clinical case. 1. Tooth 22 prepared for cast metal root anchored device.

The device was conformed cast using the self-curing acrylic mockup (Duracryl, SPOFA) (Fig. 1.2). The device was

[1] Corresponding Author: Covrig Valeria, University "Vasile Goldiş", Arad, Dentistry Medicine Faculty, the Discipline of Dental Prosthetics Arad, Romania; e-mail: covrig.valeria@gmail.com; tel +40-0752284252
Article received on 02.05.2011 and accepted for publication on 21.08.2011
ACTA MEDICA TRANSILVANICA September 2011; 2(3)456-461

sandblasted. Cementation was performed with zinc phosphate cement (Harvard). The final restoration made of Cr-Co alloy, plated with diacryliccompositeresin (Chromazit) (Fig. 1.3)..

Figure no. 1.2. The cast metal root anchored device (conical with a rounded tip)

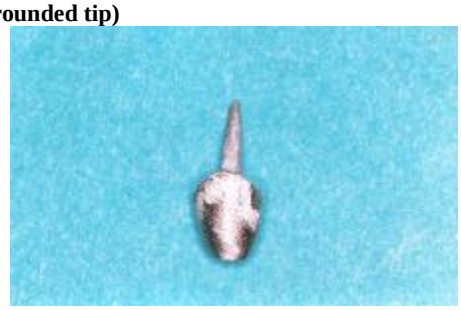

Figure no. 1.3. Final fixed diacrylic composite resin prosthesis

Clinical case no. 2

Patient ME, 40 years old, came with massive coronary lesions of teeth 12, 21, 22 and 23 which were restored with multiple cast metal root anchored devices. We preferred this solution because of the large coronary destructions caused by the excessive forces created by teeth grinding.

Figure no. 2.1. Case report no. 2. Multiple cast metal devices "in situ"(12,21,22,23)

Figure no. 2. 2. Temporary device

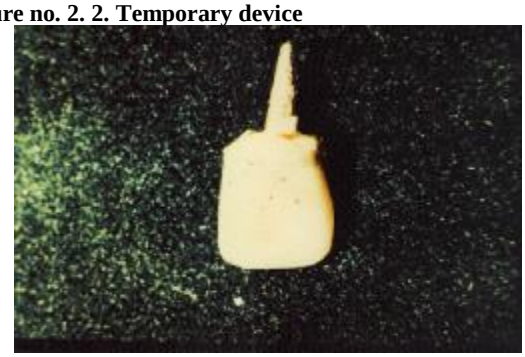

Figure no. 2.3. Self Cure acrylic fixed prosthesis with two RD sites

Clinical case no. 3

Patient VA, 36 years old, came in 1986 for upper jaw rehabilitation. The following clinical examination revealed the existence of a Kennedy class I edentulous space, unsatisfactory partially rehabilitated, with a fixed prosthesis made of self-curing acrylate, multiple dental lesions, marginal periodontitis and reverse occlusion relations for the front incisor 12. After pulp extraction, for 12 we cast a angulated device in hope of resolving the inverted occlusal relations (Fig. 3.1). Were performed conservative, operative and periodontal treatment, and two fixed provisional prosthesis to test the new occlusal relationship, later on preparing the final metal-acrylic fixed prostheses.

Figure no. 3.1. Clinical case # 3, 12 with angular metal cast D.C.R.

Clinical case no. 4

Patient MM, age 27, arrived in the office in 1989 for rehabilitation of single toothbilateral edentulous spaces (Fig. 4.1). To protect the vitality of pulp in the right mandibular arch we prepared a bridge type restorationwith a cast metal crown on tooth 47 and an inlay in tooth 45, which presented an ocluzo-proximal carious lesion. For the lower left arch, where tooth 35, had a correct root canal filling we prepared a cast metal inlay with a root portion which had an occlusal slot for the additional inlay of the fixed bridge. (Fig. 4.2). The posterior tooth (37) has a cast metal crown (Fig. 4.3).

Figure no. 4. 1. No. 4 Case report Class III Kennedy edentulous arch, massive coronary destruction of tooth 35

Figure no. 4.2. Cemented Inlay post

Figure no. 4.3. Final fixed partial prosthesis, in situ''

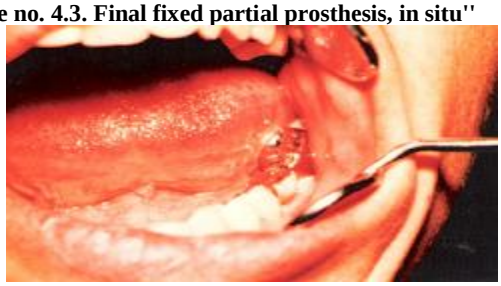

Clinical case no. 5

Patient PC, 35 years old, came in 1988 for fixed prosthetic rehabilitation of the left maxillary for aesthetic purposes (Fig. 5.1). After removal of the metal-acrylic fixed prosthesis on 25 with extension 26, a root anchored device is observed. The X-ray examination shows that it is short, but well preserved.

To extend the shortened lower dental arch after extractions, a ceramic dental implant was placed and covered immediately with a fixed crow.(Fig. 5.2, 5.3).

After 10 years, the implant and the root anchored device were mobilized. The implant was removed, the post was reinserted and cemented with a glass ionomer cement (Ketac-Cem, ESPE) over which a fixed porcelain-fused-to-Metal prosthesis was made.(Fig. 5.4).

Figure no. 5.1. Clinical Case no.5 Unaesthetic fixed bridge that was later removed

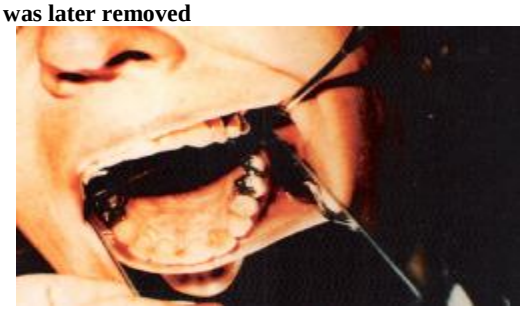

Figure no. 5.2. Prosthetic fieldafter removal of the prosthesis and applying of a ceramic implant

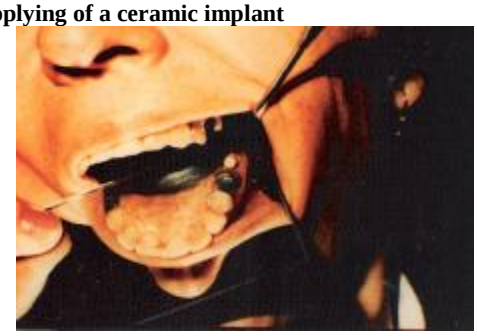

Figure no. 5.3. 25 and radiographic evidence of implant after 5 years

Figure no. 5.4. After 10 years, with a fixed metal-ceramic prosthesis

Clinical case no. 6

Patient PI, 25 years old, came in 1997 for fixed prosthetic rehabilitation of the superior rightarch. The clinical examination showed the following: 15 with a perforatedmetal crown and 16 with a high degree of coronary destruction incorrectly restored. Endodontic treatment is appropriate. The Molar is restored with two prefabricated threaded devices and Polofilcomposite (Voco) (Fig. 6.1, 6.2). The final restoration is metal-composite (Chromasit) with a metal occlusal surface, because the patient has bruxism (Fig. 6.3)

Figure no. 6.1. Case report no. 6 Cast D.C.R. (15) and a corono-root restoration with Dentatus device and composite resin (16)

Figure no. 6.2. Dentatus devices kit (gold plated)

Figure no. 6.3. Final fixed prosthesis

Clinical case no. 7

Patient BV, 32 years old, came in 1986 for a single tooth edentulous space in the left inferior jaw. On examination were noticed massive coronal lesions in teeth 35 and 37 with gangrenous aspect, and the absence of 36. The gangrenous proceses were treated and the teeth were restored with prefabricated Dentatusdevices and a composite material (Culmat, Bona Dent) (Fig. 7.1). Final fixed prosthesis was made of Cr-Co alloy and plated with acrylate (Fig. 7.2).

Figure no. 7.1. Case report no. 7. 35 and 37 restore Dentatus devices and Culmatcomposite material

Figure no. 7.2. Final fixed restoration.

Clinical case no. 8

Patient Î.I., 50 years old, with a prosthesis made in 1995. 13's restoration with a prefabricated Dentatus device and Culmatcomposite and a fixed metal-acrylic bridge (Fig. 8.1, 8.2).

Figure no. 8.1. Case report no. 8, 13 restored with Dentatus and Culmat composite resin.

Figure no. 8.2. The appearance of the final prosthesis

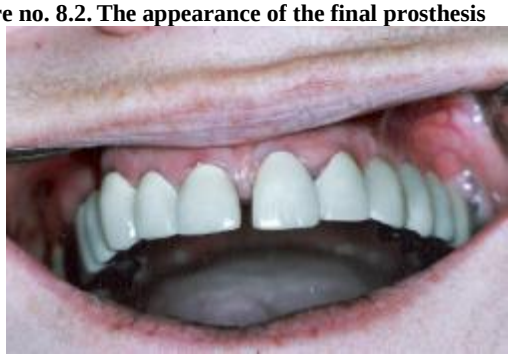

Clinical case no. 9

Patient PS, 35 years old, came in 1999 for dental treatment and prosthetic rehabilitation. On examination we found the existence of multiple dental lesions, marginal periodontitis and reduced size edentulous gaps inadequately rehabilitated. (Fig.9.1). After removal of mandibular fixed prosthesis made of Gaudent (35 and 37), 37 molar was restored with silver amalgam and Dentatus posts, using a copper ring as a conformation matrix (Fig. 9.2, 9.3).Dental injuries and periodontitis were treated, and mandibular arch was rehabilitated.

Figure no. 9.1. : Case report no. 9. Mandibular appearance before treatment

Figure no. 9.2. 37 molar with two cemented Dentatus posts

Figure no. 9.3. Silver Amagam restored stump

Clinical case no. 10

Patient HS, 62 years old, came in 2002 for prosthetic **rehabilitation. The edentulous maxilla presents a Kennedy**

Class I gap, inadequately rehabilitated with a fractured lateral incisor (22) with the opening of the pulp chamber. The mandible has a subtotal edentulous ridge.

Pulpectomy and root fillings are made of 12 and a restoration of the stump with the Para-Post device and a composite resin (Fig. 10.1, 10.2, 10.3). Later on we prepared a mixed prosthetic restoration (Fixed metal-composite frontal bridge with the following stumps: 12, 11, 21, 23, 24, and a distal partial acrylic denture), and an overdenture in the mandible (Fig. 10.4).

Figure no. 10.1. 12 tooth crown fracture and a prefabricated Para-Post device, cemented with Ketac-Cem.

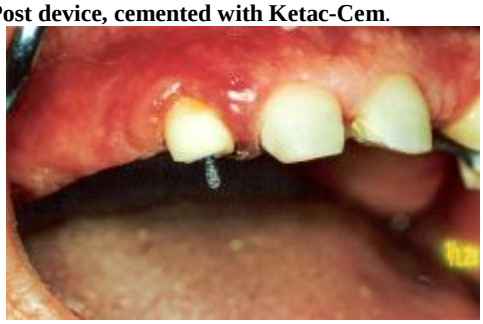

Figure no. 10.2. Para-Post milling devices for appropriate root socket conformation

Figure no. 10.3. 3 **Composite restored abutments**

Figure no. 10.4. Final Prosthesis

Clinical case no. 11

Patient BI, 31 years old, arrived in 2005 for the rehabilitation of the frontal area of the jaw. After removing a broken fixed acrylic prosthesis, we found large coronal destructions to the teeth 11 and 12 but a correct endodontic filling (Fig. 11.1). We decided to restore the teeth with prefabricated devices Para-Post, which were cemented with Ketac-Silver (ESPE). The same material was used to rebuild the coronary abutment (Fig. 11.2). The material is cement, so it has the adhesive qualities of ionomerecements, but it has inclusions of silver, which increases its hardness. The final prosthesis is fixed on teeth 11, 21 and 22 and is made of Cr-Co alloy plated with self-curing acrylic resin (Fig. 11.3).

Figure no. 1.1. Case report no. 11 teeth 11 and 12 with massive coronary destructions (with endodontic treatment)

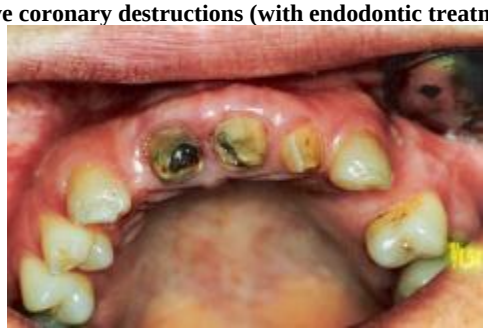

Figure no. 11.2. Abutments restored with Para Post devices and Ketac-Silver

Figure no. 11.3. Final fixed prosthesis

RESULTS AND DISCUSSIONS

Among the 1860 patients investigated over a period of 25 years, 1260 had metal root anchored devices, 870 cast metal and 390 prefabricated. Among the 870 cast metal devices in the group of studied patients, 620 were aggregated to single root teeth and 250 to multiple root teeth.

We noticed a couple of frequent occurring aspects. These are the accentuated tapered preparation of the tooth, short length preparations, large diameter of the preparation, and deviations during the preparation. All these aspects can lead to root fracture. This is complemented by a smaller percentage of devices that were too thin or too long or made of alloys that are not so resistant (silver, gaudent). The percentage of devices correctly made was relatively small. However, the percentage of tooth fractures, detected by us, is also small. Among the 390 prefabricated devices, 250 were Dentatus type, the remaining came from other categories. Among these 200 were placed in the mouth in single root teeth and the rest were placed in pluri-

radicular teeth. For 19 teeth treatment indication was not correct. Frequent deviation from the root canal was found. Another aspect that we discovered was that very often the device length was under 2/3 of the total root length (41 cases). The most frequent device fractures occurred in the gingival portion of the dievices. Only 30 devices were placed correctly.

CONCLUSIONS

To prevent root fracture of endodontically treated teeth, restoredwith cast metal root anchored devices we drew the following conclusions:

- The indication for this type of restoration must be correct. • One must preserve as much tooth root and crown structure as possible.
- Roots with 1 mm thinner walls will be extracted.
- One must correctly prepare the root socket and recocomend an X-ray examination of the preparation.
- The length of the device must be 2 / 3 of root length (less for curved roots, or more if dealing with short roots).
- The diameter of the device must not exceed one third of the diameter of the root.
- The best shape or the cast metal devices is cylindrical-conical.
- For circular devices one must use anti-rotational sockets. • The device must have good neck support on a large area of dental tissue.
- It is recommended to have a rough device surface
- On the sides of the DCR one must create overflow cement sockets
- Cementing technique may not be brutal.
- To use alloys with the same elasticity as the dentin as not to overburden the tooth.
- Final restoration-tooth junction must exceed the device with a minimum of 2 mm, or the device must have a cervical collar.
- The restoration must integrate seamlessly into the dental arch and additional strain shouldn't be placed on it by premature contacts

BIBLIOGRAPHY

1. Andreescu C., Cherlea. V. Tehnica restaurărilor coronare cu ajutorul pivoturilor parapulpare şi intraadiculare. Ed. Cerma, Bucureşti, 1999.
2. Bodea R., Nica I., Gaşpar D., Stratul S., Mateiaş M. Susceptibilitatea la fractură a dinților cu tratamente endodontice. Studiu experimental. Zilele Stomatologice Bănățene, Timişoara, Aprilie 1998.
3. Bratu D., Bratu EM., Antonie S. Restaurarea edentațiilor parțiale prin proteze mobilizabile, Ed. Medicală Bucureşti, 2008.
4. Christensen GJ. Posts and cores: state of the art. JADA, 129: 96-97, January 1998.
5. Cohen B.I., Pagnillo M.K., Deutsch A.S. and Musikant B.L. Fracture strengths of three core restorative materials supported with or without a prefabricated split. J. Prosthet Dent., 78(6): 560-565, December 1997.
6. Dietschi D., Romelli M. and Goretti A. Adaptation of adhesive posts and cores to dentine after fatigue testing. Int. J. of Prosthodont, 10(6): 498-507, 1997.
7. Evans D.B. and Orien W.J. Fracture strength of glass infiltrated-magnesia core porcelain. The International Journal of Prosthodontics 12 (1): 38-44, 1999.
8. Gonthier S., Behin T. and Dupas P.H. Making a direct post and core in less than 15 minutes. J. Prosthet. Dent., 76(1): 102-103, July 1996.
9. Isidor F., Brondum K. and Ravnholt G. The influence of post lenght and crown ferrule length on the resistance to cyclic loading of bovine teeth with prefabricated titanium posts. The International Journal of Prosthodontics, 12(1): 78-82, 1999.
10. Marxkors E., Marxkors D., NeumeyerS. and Ahlers H. OptiPost ein Optimiertes Wurzelstiftsystem. Quintessenz, 48(2): 261-278, 1997.
11. Morton D. and Aquilino S.A. Fabrication of multiple posts and cores using a thermoplastic material and an indirect technique: A clinical report. J. Prosthet. Dent., 78(6): 542-543, December 1997.
12. Rinke S. and Hulis A. Postendodoutische Seitenzahnversorgung. Quintessenz, 50(10): 1047-1073, 1999.
13. Rosenstiel S.F., Land M.F. and Holloway J.A. Custom cast post fabrication with a thermoplastic material. J. Prosthet. Dent., 77(2): 209-211, February 1997.
14. Sadan A., Elliot R. and Raigrodsky A.J. Treatment planning extensively brokendown mandibular molars for post-and-core fabrication. Quintessence International, 29(6): 351-355, 1998.
15. Smith C.T. and Schuman N. Restoration of endodontically treated teeth: A guide for restorative dentist. Quintessence International, 28(7): 457-462, 1997.
16. Stockton L.W. Factors affecting retention of past systems: A literature review. J. Prosthet. Dent., 81(4): 380-385, April 1999.
17. Tulunoglu I.F. and Gorduysus O. A simple method for the restoration of fractured anterior teeth. J. Prosthet. Dent., 78(6): 614-615, December 1997.
18. Wu M.K., Pelian Z., Kontakiotis E.G. and WesselinkP.R. Microleakage along apical roat fillings and cemented posts. J. Prosthed. Dent., 79(3): 264-269, March 1998.
19. Wippert A., Biggel A. - Präzise Gusstechnik bei Implantatkombiarbeiten**,** Zahntech Mag. 9, 7-8, 2005, p. 2464-2472.