

## DISORDERS OF THE PERMANENT TOOTH ERUPTION IN CONNECTION WITH A CASE REPORT

I. M. FĂGEȚAN<sup>1</sup>, ADELA - ELENA VOICESCU<sup>2</sup>

<sup>1,2</sup>S. C. Dinu & Făgețan S.R.L. Sibiu

**Keywords:** odontoma, inclusion, odontogenic tumor, radiographic examination

**Abstract:** Disorders of the eruption may be caused by multiple factors. The tooth inclusion can cause accidents and complications with extremely varied clinical manifestations. In this article is presented the inclusion of 4.1. and 4.2. produced by compound odontoma. Although odontomas are generally included in the category of calcified odontogenic tumors, most authors admit that it is appropriate to consider these malformations rather than true neoplasms. OMS continues to frame them in the category of benign odontogenic tumors, the subgroup with epithelium and odontogenic ectomesenchyme, with formation of dental hard tissues. The first cases reported as compound odontoma in 1854 and 1858. The term "odontoma" was introduced by Broca in 1868. The etiology of odontomas is not precisely explained, it was assumed that local trauma or infection can cause odontomas. Solving the presented case was made by surgery excision of the odontoma and of the included teeth.

**Cuvinte cheie:** odontom, incluzie, tumoră odontogenă, examinare radiografică

**Rezumat:** Tulburările de erupție pot fi cauzate de factori multipli. Incluzia dentară poate determina accidente și complicații cu manifestări clinice extrem de variate. În acest articol este prezentată incluzia 4.1. și 4.2. produsă de prezenta odontomului compus. Deși odontoamele sunt în general incluse în categoria tumorilor odontogene calcificate, majoritatea autorilor admit că este adecvat a considera aceste leziuni mai degrabă malformații decât neoplasme adevărate. OMS continuă să le încadreze în categoria tumorilor benigne odontogene, subgrupul cu epiteliu și ectomezenchim odontogen, cu formare de țesuturi dure dentare. Primele cazuri de odontom compus au fost raportate în 1854 și respectiv 1858. Termenul de "odontom" a fost introdus de către Broca în 1868. Etiologia odontoamelor nefiind explicată cu exactitate, s-a presupus că traumatismele locale sau infecțiile pot provoca odontoame. Rezolvarea cazului prezentat s-a realizat printr-o intervenție chirurgicală de excizare a odontomului și a dinților incluși.

### INTRODUCTION

Tooth inclusion represents submucosal or intraosseous retention of a fully developed tooth, beyond the normal period of eruption, or without having the tendency to erupt. In the etiopathogeny of dental inclusions are incriminated local causes (disorders that interest during the period of tooth development in the thickness of bone, tooth eruption obstacles, reduction of arcade space, osteosclerosis of alveolar process) or general factors (hereditary factors, toxic causes, chromosomal abnormalities, vitamin deficiency, metabolic disorders). Tooth inclusion is most frequently to permanent teeth and rarely at deciduous teeth. In most cases, clinical signs of dental inclusions go unnoticed for that individual and his family, sometimes even for the doctor. Whether outwardly through pathologic phenomena triggers their side, or the inclusion is discovered accidentally during a radiologic examination of the neighboring regions. Early detection, removal and proper treatment of the causes, based on a diagnosis established early, prevent further complications.

### THE AIM OF THE STUDY

In this article is presented the inclusion of 4.1. and 4.2. produced by compound odontoma.

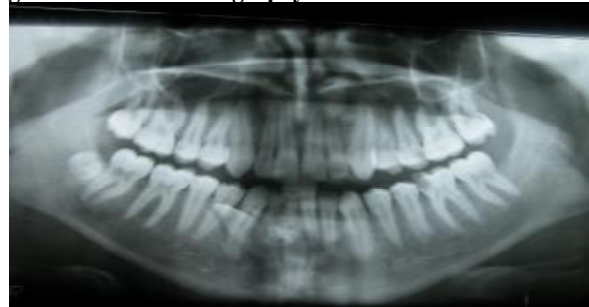
### MATERIAL AND METHODS

We had in observation and treatment a 16 years old

male patient, it was observed in clinical consultation the persistent of 8.1, 8.2 on arch. Following the radiographic examination, was been revealed he inclusion of 4.1 and 4.2 and the presence of some radiopaque formations, establishing the diagnosis of odontom compound. Radiopaque formations were observed on the OPT radiography in both jaws, in mandibular region between 3.3. and 4.3. and in maxilla at the apex of 2.2.

This diagnosis was later confirmed by histological examination of the lesions after their surgical removal.

Figure no. 1. OPT radiography



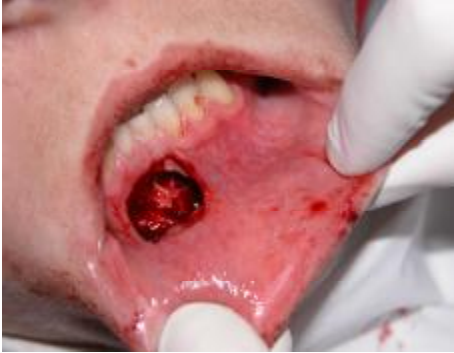Radiographic aspects of odontoma are characteristic. The compound odontoma shows calcified structures resembling teeth in the center of a well-defined

<sup>1</sup> Corresponding Author: I. M. Făgețan, 6, Șerbota street, Sibiu, România; e-mail: imfagetan@yahoo.com; tel +40-0745605540  
Article received on 28.12.2010 and accepted for publication on 21.04.2011  
ACTA MEDICA TRANSILVANICA September 2011; 2(3)439-440

## CLINICAL ASPECTS

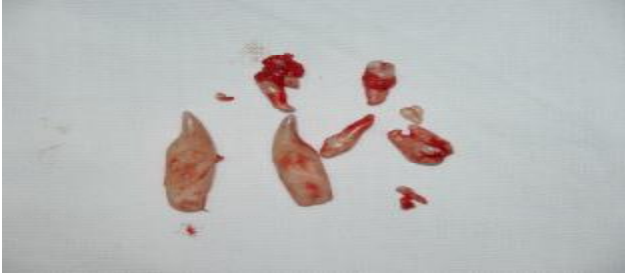radiolucent lesion. A periodontal and pericorony space characteristic of unerupted teeth is seen around each tooth.

**Figure no. 2. Clinical aspects after excision**



Inclusion is due to the presence of a tumor consisting of isolated adult dental tissues and diffuses. By surgical intervention, we achieve the tumor and the included teeth removal.

**Figure no. 3. Odontogenic tumor and removed teeth (4.1.; 4.2.)**



Surgery was performed under local anesthesia, postoperative evolution was favorable.

## RESULTS AND DISCUSSION

Odontoma is considered the most common type of odontogenic tumor, most often associated with teeth, Kaugars et al. found that at least 47.6% of cases presented and included teeth. Chang et al. investigating 80 cases of odontomas, found that 79% were associated with 80 teeth, of which 71 permanent teeth, two deciduous teeth and 7 supernumerary teeth.

Odontomas may be responsible for disturbances of tooth eruption abnormalities in their position. The tumor grows slowly and expansive, rarely can reach considerable size causing significant deformation of the jaws, with pronounced facial asymmetry. In their evolution, central odontomas (intraosseous) corrode cortical bone, ulcerate gingival mucosae and erupt in the oral cavity. Once erupted, the odontoma is predisposed to infection, develops a carious process and during the time may form abscesses.

It is generally a tumor of the child, adolescent and young adult. The treatment is simple, postoperative evolution is favorable, with no complications. Depending on the inclusion conditions, orthodontic surgical redress can be attempted, conservative surgical method that consists in discovering the tooth crown and anchoring it in order to redress and traction slowly, gradually, until the tooth resume his normal position on the arch. Orthodontic-surgical recovery success depends on good cooperation between the orthodontist and maxillo-facial surgeon, in early phase of establishment of the diagnosis.

Our case was not suitable for this type of intervention, because the indication in the presence of odontoma is to remove included teeth together with the tumor mass.

## CONCLUSION

Early diagnosis followed of immediate application of an appropriate treatment is the only way to prevent infectious complications, jaw deformities and disorders of eruption.

## BIBLIOGRAPHY

1. Bucur Al. (sub redacția) Compendiu de chirurgie oro-maxilo-facială, Patologia erupției dentare, pag. 105-140;
2. Mărgăritescu C., Simionescu Cristiana Tumori și pseudotumori maxilare, 2010; pag. 250-280;
3. Amado-Cuesta S., Gargallo-Albiol J., Berini Aytes L., Gay-Escoda C. Review of 61 cases of odontoma. Presentation of an erupted complex odontoma. Med Oral. 2003; 8: 366-73;
4. Wai Hei To E. Compound composite odontome associated with impacted canine. Case report. Australian Dental Journal 1989; 34 (5): 414-16;
5. Budnick St. D.. Compound and complex odontomas. Oral surg. 1976; 42 (4): 501-6.