THE CONSEQUENCES OF EARLY LOSS OF THE SIX YEAR MOLAR ON THE DENTO-MAXILLARY SYSTEM DEVELOPMENT

ANCA FRĂȚILĂ [1], MARIANA SABĂU[2], DIANA MÂRZA[3], C. BOITOR[4], ALINA CRISTIAN[5], ALINA SOBOTEAC[6], O. BOITOR[7]

[1,2,3,4,5,6,7] "Lucian Blaga" University of Sibiu

Keywords: *6 year molar, extraction, precocious*

Abstract: *The article presents a clinic-statistical study conducted over a period of five years on a group of 198 patients aged between 21 and 40, whose six-year molars were extracted in early childhood. In the study are presented the consequences of early loss of these teeth, on the development and functions of the dento-maxillary system.*

Cuvinte cheie: *molar de şase ani, extracție, precoce*

Rezumat: *Articolul prezintă un studiu clinico-statistic efectuat pe o perioadă de cinci ani pe un lot de 198 de pacienți cu vârste cuprinse între 21 şi 40 de ani, ai căror molari de şase ani au fost extraşi timpuriu în copilărie. Sunt prezentate consecințele în timp ale pierderii precoce a acestor dinți asupra dezvoltării şi funcțiilor aparatului dento-maxilar.*

INTRODUCTION

We chose to study this subject because we found in the current practice the high incidence of dental coronary lesions at the six-year molars from an early age, at about three to four years after eruption. The six year molar is the most affected tooth by dental caries from all the permanent teeth, being named by Kunzel (1988) like the problem child of infant stomatology (1). These large carious lesions evolve rapidly with coronary amputation and occurrence of inflammatory periapical processes that make the molars to be irrecoverable since from childhood. As incriminate causes: low addressability to a dentist for children of school age, especially the lack of knowledge by parents of molar eruption age for six year molars, poor oral hygiene and lack of appropriate tooth brushing skills of these children. Most parents note that in the child's mouth appear changes of deciduous teeth with the permanent ones only at the age of 7-8 years, when the incisors appear, but at that time the six year molars already erupted and present active carious processes, in the conditions in which the oral hygene starts only at this age. Other factors are the six year molar mineralization in a susceptible period with many metabolic changes (ninth month of pregnancy, first years of life), the early eruption of the permanent teeth associated with multiple caries on the temporary teeth, injured occlusal relief, the predominance carbohydrate in the diet (1) The consequences of the six-year molar extractions are linked with the moment of loss of the tooth, but all the age periods are complicated by some disadvantages (2). The extraction of six year molar draws the installation of morphological and functional changes associated with the disturbance of the masticatory and self-cleaning functions, and with the occurrence of dento-maxillary disharmonies.

CASE PRESENTATION

We performed a clinic- statistical and longitudinally-radiological study, initiated in 2007 with the final evaluation in 2011, on a sample of 198 adult patients aged between 21 and 40, who had early childhood six year molar extractions, from various causes (destroyed dental crown, short roots, diffuse osteitis, frequent acute exacerbation, collaboration difficult, systemic diseases, etc.). For each subject were recorded in individual records on the examination, personal data, dental status, radiographic aspects. Later data have been accumulated and processed using Excel.

a. Clinical and radiological aspects

The consequences of the six year molar extraction are compared to the moment in which the teeth loss happened.

Clinical case no. 1:

The first clinical case is a patient, who is 37 years old. The following extractions were performed in the childhood, as wieved in the radiological examination (Figure 1):

- Left maxillary arcade: the six year molar extracted at the age of eight years, followed by 2nd molar in part by translational displacement and partly by inclination of the crown, with the decrease in the edentulous space;
- Left side mandibular arcade: the six year molar extracted around the age of 9 years, the gap is now almost closed by the mesial inclination of the 2nd molar;
- Right mandibular arcade: the six year molar extracted at the age of 12 years, the gap is now reduced by the mesial inclination of the 2nd molar, but not enough to seal the space.

Figure no. 1: Paused dental arcades, interrupted by the modification of the limitrophe teeth position due to early extraction of the six year molar.

Clinical intraoral due to the massive coronary destruction in time of the 2nd left lower molar, we created on it a

[1] Corresponding Author: Anca Frățilă, 2A Negruzzi street, Sibiu, România; e-mail: fratila.anca@yahoo.com; tel +40-0722933510
Article received on 28.11. 2010 and accepted for publication on 20.06.2011
ACTA MEDICA TRANSILVANICA September 2011; 2(3)441-443

metal-ceramic microprosthesis which seals the 1 millimeter space, initialy presented. This type of restoration can not correct the reverse gear localized due to the 2nd molar because of it's vicious position appeared in time, because of the precocious extraction of the 1st molar (Figure 2).

Figure no. 2. The microprosthesis aggregate on the 2nd left lower molar in reverse gear

On the right inferior arcade (Figure 3) we observe clinically an edentulous space narrowing, which will be restored with difficulty, because it requires the creation of a crown with premolar morphology in a space reserved initialy to a molar, producing because of this modifications on the bite functions which should be present at the 1st molar and the Angle key level.

Figure no. 3. Edentulous space narrowing

Clinical case no. 2:

The second case report of a patient, who is 27 years old, whose six-year molars were extracted in childhood, around the age of 8-12 years. The occlusion of the pacient was severely affected by occlusal dysfunction having repercussions on the dento-maxillary functions, especially on the masticatory function.

The radiological examination reveals the absence of the four six year molars so (Figure 4):

- Right maxillary arcade : the mesialisation of the 2nd molar and the distalisation and the extrusion of the 2nd premolar, the extraction was performed at the age of 8 years;
- Left maxillary arcade: the mesialisation of the 2nd molar by a translation movement, the space being almost sealed; the extraction was performed at the age of 8 years;
- Left side mandibular arcade: an easy mesalisation of the 2nd molar, the space being reduced by about 5 millimeters; the extraction was performed at the age of 10 years;
- Right mandibular arcade: the 2nd right lower molar is not mesialisated (and because of the extrusion of the 2nd upper premolar to the edentulous ridge); the space for the 1st molar being presented; the extraction was performed at the age of 12 years.

Figure no. 4. Radiographic aspect on the ortopantomography

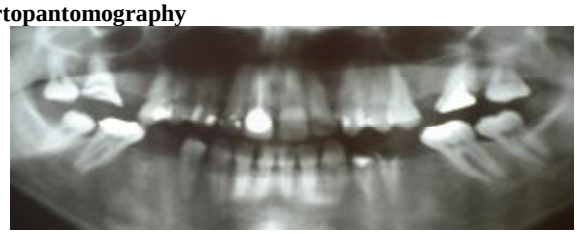

Clinicaly in the maximal intercuspidal we observed in the right side of arcade, the migration of the upper right premolar until almost in contact with the mandibular edentulous alveolar ridge (Figure 5), the closed space for prosthetic upper molar and lower 2nd molar in reverse gears.

Figure no. 5. The clinical aspect of the right hemiarcades in maximal intercuspidal

On the six year left lower arcade edentulous molar (Figure 6) we made a metal-ceramic aggregate bridge on the 2nd molar and on the two crown-radicular devices from the premolars. Morphologicaly, the bridge's body was reconstructed as a premolar, because it wasn't enough space to reconstruct a molar, the intermediary tooth was modeled as a premolar and the prosthetic construction enrolling in the arch shape and being occlusal functionalized.

Figure no. 6. Left arcade mandibular prosthetic restoration. Spaces are present between the canine-premolar following molar extraction six years early

b. Clinical and statistical aspects

- The results obtained from the study include the following aspects: most patients from the study, as the figure no. 7 shows (105 patients -53.03%), presented the edentation of two six year molars, 42 patients (21.21%) presented a single molar edentation, 31 patients (15.65%) presented three molar edentation and 20 patients (10.10%) presented the edentation of all six year molars;

Figure no. 7. Frequency of the number of extracted molars

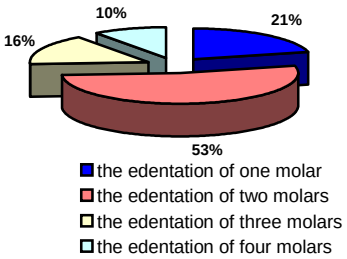

- the extractions were done mainly at the age of 8-9 years in 114 patients in the study (57%), followed by the age of 9-10 years - 63 patients (32%) and 10-12 years of age - in 21 patients (11%) as the figure reveals at number 8;
- most patients remain without prosthesis until adulthood (174 patients - 88%), with the migration in consequence of the teeth limiting the edentulous gap which leads to dento-maxillary system malfunctions (figure 9).

Figure no. 8. The age from where the extractions were performed

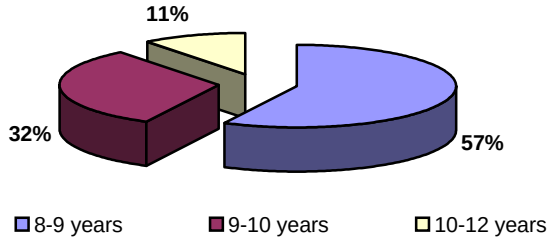

Figure no. 9. Prevalence of prosthesis in the studied group

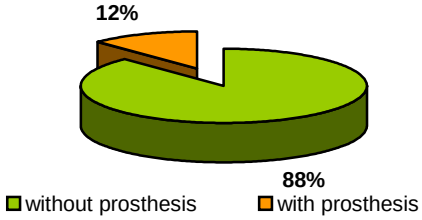

DISCUSSION

The precautionary principle and risk assessment are key factors of human health protection measures which have to be integrated into community health care. In most industrialized countries of Western Europe in the last 20 years, there is a strong regression of dental caries. The prevalence of dental caries has declined significantly in developed countries in Western Europe and North America (3). In the countries of Eastern Europe, this decrease of dental caries is not as important as in the other countries (4).

Carious disease has an impact on child growth and development, but also on the quality of child's life and of the future adult (5, 6). The survey from Cluj-Napoca on morbidity indicates the dental caries in first permanent molars showing that at the age of 6 years 47, 6% of children have dental molar caries located on the six year molar, and at the age of 12the procent is 85.23 % (1.7).

The moment of the six year molar irretrievable extraction must be chosen carefully according to a number of factors: the role of the six year molar maintaining the occlusal relationships, dental age, the general laws of teeth migration, the presence of dental-jaw disharmonies (8.9).

CONCLUSIONS

1. The early loss of the six year molars determines changes on the dento-maxillary system functions, masticatory functions especially, by affecting the occlusion from sagittal plane produced by the migration of the teeth limiting the edentulous gap.
2. If the edentation occurred around the age of 7-9 years then the dento-maxillary system changes are more extensive.
3. The twelve year molars limiting the edentulous gap suffer position wider modifications than the premolars.
4. Because most patients remain without prosthesis until adulthood, irreversible changes take place in the stomatognathic system.
5. The six year molar represents a crucial factor for the development of dento-maxillary system and it is therefore imperative to preserve the molar on the dental arch throughout life.

REFERENCES

1. Cocârlă E. Paediatric Dentistry, Ed. Medicală Universitară Iuliu Haţieganu Cluj-Napoca, 2000, 19-29, 58-60, 162-167, 170-176, 181-183, 191-195, 231-242.
2. Zarnea Livia, Pedodontie Ed. Didactică şi Pedagogică Bucureşti, 1993.
3. Adam A. Maxim, Adriana Bălan, Marinela Păsăreanu, Carmen Savin , Ana Petcu, Vasilica Toma, Dana Cristiana Rotaru. Revista Romană de Medicină Dentară, vol. X, nr. 1, pag. 7-19, 2007.
4. Szoke J, Petersen PE. Evidence for dental caries decline among children in an East European Country. Community Dent Oral Epidemiol, 2000; 28: 155-60.
5. Ralph E. McDonald, David R. Avery. Dentistry for the Child and Adolescent (8th Edition), ISBN 0323024505, Publisher Elsevier Science, Mar. 2004.
6. Skeie M.S., Raadal M., Strand G.V., Espelid I. Caries in primary teeth at 5 and 10 years of age: a longitudinal study. Eur J Paediatr Dent., 2004 Dec; 5(4): 194-202.
7. Păstrav M., Ţărmure V., Păstrav O., Cocarla E., The odontal status of the first permanent molar and the frecvency of dento-maxillary abnormalities in the second phase of mixed dentition. Study on a group of children in Cluj-Napoca, Clujul Medical, 2009, vol. 82, nr. 2, 275-278.
8. Sulaiman E. S. Al-Emran, Extraction of first permanent molars in the management of anterior open bite malocclusion, Saudi Dental Journal, 2001, 13 , 3.
9. Penchas J. et all. The dilemma of treating severely decayed first permanent molars in children: to restore or to extract. ASDC J Dent Child 1994, 61: 199-205.