

A VERY SERIOUS NEW DISEASE – EXTENDED DRUG-RESISTANT TUBERCULOSIS (XDR TB)

MIRELA MITREA¹, VICTORIA BIRLUTIU², M. DEAC³

¹ Pneumoptisiology Sibiu, ^{2,3} University “Lucian Blaga” of Sibiu

Keywords:

tuberculosis, extended chemo-resistance, primary resistance, non-compliance

Cuvinte cheie:

tuberculoza, chimiorezistență extinsă, rezistența primară, noncompliance

Abstract: Compared to germ sensitive tuberculosis (TB), in the case of multi-drug resistant (MDR TB) or extended drug-resistant tuberculosis (XDR TB) the prognosis is unfavourable, by prolonging therapy and its success is relatively limited. Early diagnosis and swift establishment of the target therapy according to the extended antibiogram are very important for the success of the therapy. Abandonment and improper therapy in most cases lead to therapeutic failure and premature death. This paper presents the case of a patient presenting primary resistance of XDR TB type, with therapeutic non-compliance and abandonment, evolution being unfavourable and resulted in premature death of the patient.

Rezumat: În comparație cu tuberculoza (TB) cu germeni sensibili, în cazul tuberculozei multidrogrezistente (TB MDR) sau cu rezistență extinsă (TB XDR) prognosticul este dezavantajos, prin prelungirea duratei terapiei iar succesul acesteia este relativ limitat. Diagnosticarea precoce și instituirea cât mai rapidă a terapiei și conform antibiografei extinse este foarte importantă pentru succesul terapiei. Abandonul sau terapia necorespunzătoare conduc în majoritatea cazurilor la eșec terapeutic și deces prematur. Lucrarea de față prezintă cazul unei paciente prezentând rezistență primară de tip TB XDR, cu non-compliance terapeutică și abandon, evoluția fiind înfaustă soldată cu decesul pacientei.

INTRODUCTION

Tuberculosis abducted about 1.7 million lives in 2009, without including those who died of TB while being affected by AIDS. (4)

More than 2 billion of the world population (a third) is infected with Mycobacterium tuberculosis, as stated by the World Health Organization (WHO) in April 2009, with extreme growth of resistant germs. (5)

In the world, according to a report published in the journal The Lancet in 2006, 19% of isolated TB strains were MDR and 2% XDR. (8)

In 2006, among the 9 million new cases diagnosed with TB, 490 000 were infected with multi-drug resistant germs. For 40,000 of patients it was the case of tuberculosis with extremely resistant germs (XDR TB - extended drug resistant tuberculosis). (5)

Recently it was proposed the term of XXDR-TB (Extremely Extended Drug Resistance) for cases resistant to all drugs of first and second line. (3)

According to the new WHO guidelines recommended patients it is required to monitor patients by association of both sputum smear microscopy and culture (rather than just of microscopy) in the case of patients with multi-drug resistant TB (MDR-TB) to detect failures as early as possible during therapy. (4)

Early recognition of MDR / XDR TB cases, by using methods for molecular detection of resistance, would substantially reduce the duration of ineffective conventional therapy in these cases, with administration of appropriate therapy according to individual resistance. (4)

Where normally a case of tuberculosis is treated for 2 months with quadruple therapy and then another 4 months with

2 of the 4 effective drugs (isoniazid, rifampicin-HR), in the MDR TB case it will be additionally assigned minimum 2 potent drug after the analysis of the extensive antibiogram, with the preparation of individualized treatment regimens.

For patients with MDR-TB, the minimum duration of treatment was extended by two months compared to previous guidance, to reflect the more successful therapy with its prolongation. Intensive treatment should therefore be at least 8 months, and for those who were not treated with second line tuberculostatics, the treatment should be extended to 20 months. The duration can be adjusted for some patients based on clinical and bacteriological response. Moreover, for patients with MDR-TB it is recommended the use of the latest fluoroquinolones and ethionamides. (4)

If XDR TB treatment is more difficult to set because in such cases resistance extends not only to established drugs of first line, Isoniazid (H) and Rifampicin (R), but also to the second line drugs, with resistance to Fluoroquinolones and to at least one of the injection Aminoglycosides like Kanamycin, Capreomicina or Amikacin (K Cap AMI). (2)

CASE PRESENTATION

We are presenting the case of the P.A. patient aged 18, originally from Braila County residing in Sibiu, the father died of TB in 2003 in Braila (unknown spectrum of resistance, so the patient followed chemoprophylaxis). The patient is hospitalized in Pneumopediatric dispensary in May 2005, being diagnosed by the general practitioner as suspect in the micro-radio-photographic control (MRF) routinely performed for employment.

Objective admission: General condition good, low grade fever 37.5 ° C, tissue connective-adipose

¹ Corresponding Author: Mitrea Mirela, 10, app.7, Oașa street, Sibiu, România; e-mail: mirela_m_mitrea@yahoo.com; tel +40-00731322178
Article received on 11.03.2011 and accepted for publication on 17.06.2011
ACTA MEDICA TRANSILVANICA September 2011; 2(3)329-331

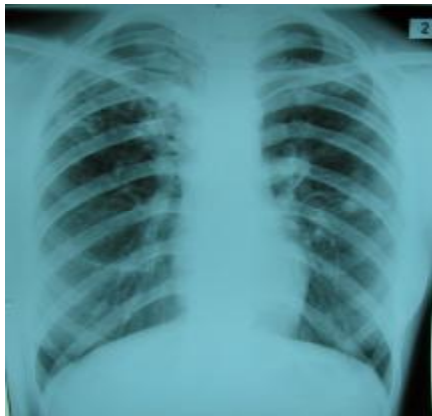
CLINICAL ASPECTS

underrepresented, body mass index (BMI) = 21.10 kg/m², pale skin, lung stethacoustic wet bronchial rough breathing in the upper half of the right hemi-breast, BP 110/70 mmHg. Patient is a non-smoker and does not consume alcohol.

Among laboratory examinations on admission we retain the anaemia (Hb = 10.8 g / dl, Ht = 33.9%, MCHC = 31.9 g%, ESR 28/hour, normal liver samples, intra-derma-reaction (IDR) 22/ I, BK sputum positive to microscopy and cultures (MC).

The radiographic appearance shows multiple fibronodular lesions subclavian right and parahilar left

Figure no. 1 Fibronodular lesions subclavian right and parahilar left



The result of the cultures received later will show primary resistance of HR type.

The case is interpreted as primary multi-drug resistant tuberculosis (MDR TB), forcing the setting of an individualized scheme with Pyrazinamide (Z), Ethambutol (EMB), Kanamycin (K), Protionamid (PTM) and Cicloserin (Cs) and sputum samples are sent to Marius Nasta Institute of Bucharest for sowing for extensive antibiogram. This will highlight primary resistance of XDR type (resistant to Isoniazid (H), Rifampicin (R), Streptomycin (S), Kanamycin (K) Protionamid (PTM) and Ciprofloxacin (CPX), PAS sensitivity Ethambutol (EMB) and Pyrazinamide, the patient being transferred to the "Center for treatment of patients with MDR TB" from the National Institute of Pneumology "Marius Nasta" Bucharest .

There is designed, according to extensive antibiogram, an individualized therapeutic regimen with Pyrazinamide, Ethambutol, PAS, Ofloxacin, Ethionamide, Cicloserin, Capreomycin 7 / 7 DOT, relatively well-tolerated treatment and is considered the first with high therapeutic chances. It was added vitamin B6 for prevention of neurological toxic phenomena, and to improve digestive complaints (epigastralgia, nausea and vomiting) there were administered symptomatic drugs with negativity on microscope in 3 months after admission. It is noticed during hospitalization the worsening of the anemic syndrome (on hospital discharge Hb = 9, 6g/dl, Ht = 28.90%) and lack of weight gain.

Although it was not obtained but microscopic negativity without confirmation by cultures, the patient insisted on discharge despite the recommendations of medical staff. This will be provided on condition of therapy continuation under direct observation in Pneumology Hospital in Sibiu, where she will present on hospitalization the poor general condition, pallor, fatigue, BMI = 18.93 kg/m². She presents on section uterine and worsening anemia (severe anemia Hb = 6.3 g%, Ht = 22.6 g %), which is why it shall be carried out a gynecological control, which shows incomplete miscarriage in the second month. An

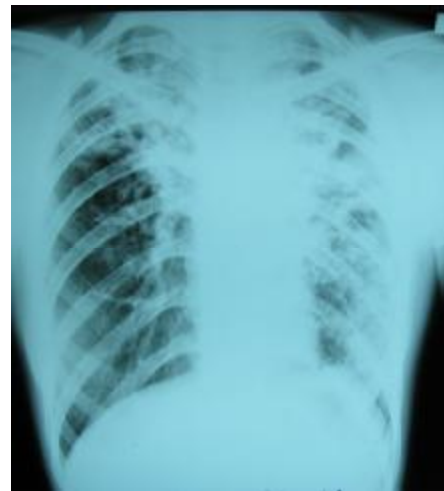uterine curettage must be carried out, and the administration of haemostatics and 1 unit red blood cell transfusion, with improvement of anemia (Hb = 9g%, Ht = 32%). Tuberculostatic therapy individualized according to the Bucharest schedule will be continued with satisfactory tolerability. In evolution, the patient develops psychosis phenomena, requiring cessation of Cicloserin with partial improvement.

Repeated hospitalizations will follow for clinical laboratory reevaluation and the therapy shall be continued according to the individualized schedule, except Cicloserin due to occurred adverse reactions, with persistent anemia, asthenia, adynamy, underweight (in evolution BMI 18kg/m²), the patient presenting, in the process, the adherence decrease to therapy, and then completely abandoning the therapeutic regimen.

The general condition at the last admission in July 2008 highlights hypoanabolic syndrome, cachexia (BMI = 16.49 kg/m²), profuse sweating, feverish, productive cough, marked mucocutaneous pallor, symptoms began based on therapy abandonment. It is noticed the worsening of radiographic appearance with fibrocavitary lesions expansion in both lung fields. (Fig.no 2)

The clinical, bacteriological and radiological aspects are progressively unfavorable, with poor outcome in treatment reinstated by the individual scheme. Therapy will again be abandoned by the patient after 5 months of reinstatement, death occurring during that year

Figure no. 2 Multiple inhomogeneous, macro nodular opacities with diffuse contour, extended in both lung fields



CONCLUSIONS

XDR TB infected patients need special clinical, paraclinical and therapeutic monitoring, the tuberculostatic therapy requiring a long period of time, the costs are enormous, and the chances of healing are much lower than with other types of TB. The treatment is lengthy, difficult and unpleasant for the patient.

Over the severity of the disease overlaps low tolerability to therapy and patient non-compliance. Non-compliance to therapy (failure of one or more drugs, omission of doses, repeated abandonment), lack of education of the patient, previous TB treatment, adverse effects, are included in the category of risk factors related to the patient.

In the case of our patient, all these factors led to treatment failure, completed unfavorably by worsening of general condition and death within 2 years after diagnosis, although initial estimates showed good chance of cure.

CLINICAL ASPECTS

The attending physician is at the same time a psychologist, a social worker and a doctor feeling the frustration caused by failure of patient rehabilitation.

BIBLIOGRAPHY

1. Bifani P, Mathema B, Kurepina N, Shashkina E, et al. The evolution of drug resistance in Mycobacterium tuberculosis: from a mono rifampin resistant cluster into increasingly multidrug resistant variants in an HIV-seropositive population. J Infect Dis 2008; 198: 90-4
2. Blondal K. Barriers to reaching the targets for tuberculosis control: multidrug resistant tuberculosis. Bull World Health Organ 2007, 85:387-90
3. Manuela Gheorghiu-Brânaru, MDR-TB(Tuberculoza multi-drog rezistentă) Disponibil la [http://www.tbnews.ro/MDR-TB-\(Tuberculoza-multi-drog/rezistentă\).html](http://www.tbnews.ro/MDR-TB-(Tuberculoza-multi-drog/rezistentă).html), Accesat 28.08.2011
4. Medscape Medical News WHO Guidelines for Drug-Resistant Tuberculosis Updated, Accesat 5.08.2011
5. Extensively drug resistant tuberculosis United States, 1993-2006. MMWR Morb Mortal Wkly Rep 2007; 56:250
6. Robert Koch-Institut. Tuberculose. In Eckmanns T (Hrsg.). Infektions epidemiologisches Jahrbuch für 2007. Berlin: Robert Koch Institut, 2008
7. Spiegelman MK. New tuberculosis therapeutics: a growing pipeline. J Infect Dis 2007; 196 (Suppl 1):S28-34
8. The tuberculosis X-Factor, The Lancet Infectious Diseases 2006, 6:679
9. World Health Organization. Global tuberculosis control. Available at: <http://www.euro.who.int/tuberculoza>. Accesat 10 august 2011