MASTOIDECTOMY VS TYMPANOPLASTY – A CONCEPTUAL RENAISSANCE. PREAMBLE TO AN ORIGINAL METHOD OF MASTOIDECTOMY

M. RĂDULESCU [1]

The Institute of Phono-Audiology and Functional Audiology ORL „Prof. dr. Dorin Hociotă”

Keywords: *Middle Ear, Mastoidectomy, Tympanoplasty*

Abstract: *The author proposes and conducts a critical analysis of two parallel concepts that have been dominating the suppurative middle ear surgery for the last 50 years: Mastoidectomy and Tympanoplasty. Its scope is to justify the appropriateness of proposing an original trepanation method of middle ear cavities.*

Cuvinte cheie: *ureche medie, mastoidectomie, timpanoplastie*

Rezumat: *Autorul îşi propune şi realizează o analiză critică paralelă a două concepte care domină domeniul chirurgiei supurative a urechii medii în ultimii 50 de ani: mastoidectomia şi timpanoplastia. Scopul acestei analize este de a justifica oportunitatea propunerii unui procedeu original de trepanare a cavităţilor urechii medii.*

INTRODUCTION

"Every surgical movement should be, like in a chess game, the result of a logical plan. Surgical disasters are usually the outcome of badly-conceived plans and therefore, the consequence of dangerous acts. Only the constant use of reasonable and logical principles, based on knowledge and experience, will enable the surgeon to react adequately, even when faced with the most unexpected situation".(1)

Is it beneficial to move the topographic system of reference points and surgical tactics of the middle ear trepanation procedures, known as *open technique*, from the *supra-retro-meatal area* to *the osseous meatus shaft ?* This is the main question we have tried to answer. It is not a theoretical answer here, but one based on practical experience. It is not a series of several laboratory experiments, but a long series of clinical and surgical observations, spread over almost two decades.

The temporal bone is one of the big skull gates. The main brain vessels and nerves for hearing, balance, taste, lacrimation and facial expression are passing through its petrous part.(2) This bone also contains the bony labyrinth with the receptors for hearing and for balance.

The petrous part is located in the center of the inner surface base of the skull, separating the temporal lobe of the brain (middle cranial fossa) from the cerebrospinal fluid cistern and the cerebellum (posterior cranial fossa).

The middle ear cavities cross the temporal bone along its longitudinal axis, starting from the nasopharynx to the mastoidian apophysis, separating the outer ear from the inner ear. These cavities are lined by a continuous mucous blanket along which inflammation and infection can spread, from the cavum to the endocranial spaces.

Our hearing level, sense of balance, face expression for emotions and sometimes even our life itself, depend on the integrity of this complicated and vulnerable bone.(2) In this article we'll talk precisely about this bone, because the aim of the surgical procedure discussed is to improve disorders resulting from inflammations and infections located there.

The temporal bone is a jewellery box of anatomical pieces of a great complexity. Its vital structures (which are on a tiny scale), as well as their complicated three-dimensional relations make oto-surgery, technically speaking, one of the most demanding surgical areas.(3) The trepanation and exenteration of the bone lesions, refer especially to mastoid cells (exenteration) and to petrous cells (possible only after trepanating the *antrum* and *aditus)*, and refer to the ***tympanic*** cavity and *protimpanum* only secondarily. Trepanation means to drill the bone in order to penetrate a cavity, which can be carved or which exists naturally in the structure of one bone, or a group of bones (eg skull trepanation). Thus, it can be stated that we are performing trepanation of axial middle ear cavities housed in the temporal bone, like *Antrum Mastoideum*, *Aditus ad Antrum* and *Attic* (*Epitimpanum* – the upper floor of the ***tympanic*** cavity).

The middle ear pneumatic cavity system is placed inside the temporal bone, based on a very simple structural principle, very easy to imagine and represent. It occupies or fills the *free* space between the two cortical types belonging to the temporal bone: 1). cortical *envelope* which is also of two kinds: *internal* and *external*, related to the rapport with the inner surface or outer surface of the skull base; 2). cortical *enclave* which is none other than the interface between the content of multiple channels and holes dug in the temporal bone, except the axial middle ear cavities (*Protimpanum*, ***Tympanic*** *Cavity*, *Aditus ad Antrum* and *Antrum Mastoideum*) (figures no. 1, 2), on one side, and that free space (spongeous bone), on the other side.

It is astonishing how a volume which does not exceed 27 cubic centimeters of generic bone, is the space where so many surgical procedures, which are totally different from one another, can be performed.

Many oto-surgeons have adopted a *transcortical* approach for chronic otomastoiditis because they have followed and developed the procedure described by the promoter of modern oto-surgery named *Hermann Hugo Rudolf Schwartze (1837–1919)*. In other words, they have done trepanation starting from the *supra-retro-meatal point* (Figure no. 3). The

[1]Corresponding Author: Marian Rădulescu, The institute of Phono-Audiology and ORL Functional Surgery – prof. dr. Dorin Hociotă – 21, Mihail Cioranu street, Sector 5, Bucureşti, telefon: 0788414497; e-mail: focaargintie@yahoo.com
Article received on 02.02.2011 and accepted for publication on 21.05.2011
ACTA MEDICA TRANSILVANICA September 2011; 2(3)498-501

bony acoustic meatus and the membranous acoustic meatus have been preserved with great care. Today, in celebration of nearly 140 years since *Hermann Hugo Rudolf Schwartze* (Figure no. 4) published his work entitled *The artificial opening of the mastoid process (1873)*, mastoid trepanation for *Simple* or *Cortical Mastoidectomy* is also performed in a *transcortical* manner as the genius initiator of this operation did it. This procedure is still topical both as technique and indication.

Another significant part of oto-surgeons were those who have founded the *Radical Mastoidectomy*, starting with *Ludwig Christoph Stacke (1859–1918)*, the disciple of *Hermann Schwartze*. They have done *subcortical* trepanation, i.e they penetrated first an axial cavity (*Attic* or *Aditus ad Antrum*), located in front of the *Antrum Mastoideum* and then lifted the external walls until the *Antrum*. Then, they widened the *Antrum cavity* towards the lateral wall, until they reached the mastoid cortex (which was lastly lifted), to end the procedure. This is known as *backward* or *retrograde* or *Stacke procedure*. Today it is also called *inside-out Mastoidectomy*.

The author's personal procedure, which we refer to in this article, is applied essentially to the *Radical Mastoidectomy* or the *Modified Radical Mastoidectomy*.

We defined or delineated the field of chronic inflammation or suppuration of the middle ear, for which, these two operations are the only rational treatment. The procedure we will discuss, addresses to the largest share in the field of otologic pathology, namely *chronic middle ear inflammation*. The share refers to the prevalence of the disease in the whole population. Otologic pathology is a field that still needs improvement, in terms of the entire foundation and full definition of concepts and principles. Next, we'll see that there are yet some other indications of this new technique. We will now mention only the tumor pathology of the external ear, middle ear and temporal bone.

In one word, the reaming operation of the bony acoustic meatus, is the primary procedure which we will discuss, and it can be applied only in those Mastoidectomy techniques which involve the ablation (lifting, demolition, excision) of the posterior wall of the external bony acoustic meatus.

There will be many people who will question the necessity of performing a new procedure to execute an operation which was devised a century ago, in the presence of the following circumstances: 1). all the procedures that are practiced today have been judiciously selected over almost a century; 2). nowadays mastoidectomies are replaced or improved by modern tympanoplasties, supported by today's technology.

As a response to this, it can be stated that we are currently in a proverbial position: *not to see the forest for the trees* or *bird in the hand is worth two in the bush* or even *count one's chickens before they are hatched*.

In other words, paradoxically, what is good, useful, tested, safe and has been acquired through the efforts of several generations of oto-surgeons is being recommended more rarely, used both incompletely and incorrectly, and furthermore, in spite of this paradoxical situation, finally, this procedure is the last and the only means we have to save what can still be saved after repetitive failures of such modern surgical techniques.

Giving up the colloquial language, we could say that, the otologic principles, that have proven their appropriateness over eight decades by practice, have been overlooked. On the other hand, another set of principles followed in a short time, that contradicted the primary ones, and then eventually contradicted themselves, leaving behind a huge state of confusion, in which the mirage of modern technology closes a vicious circle. Oto-surgeons are locked in this circle, turning a blind eye to the fundamental principles and under the illusion that they are contributing to the scientific and practice progress.

Back to answer the question above, we state that *the reaming procedure of bony external auditory meatus* used to perform a *Radical Mastoidectomy*, strictly follows the classical principles, which as long as they have been respected, have assured the control of chronic middle ear inflamation with maximum safety. Today the need is felt acutely to revive these principles in oto-surgeons consciousness.

What does *Staging (James L. Sheehy and J. A. Crabtree) (1973)* eventually mean as the final step in the evolution of the *Combined Aproach Technique Concept (1963) – William Fouts House (1923 –)* and *James L. Sheehy (1918 – 2006)* – being itself a top of contemporary technical progress for mastoid and tympanic cavity surgery? It means recognizing the deadlock if not the failure of this surgical technique. It means to admit from the outset that such modern intervention is not safe in achieving its objectives, i.e it doesn't guarantee the elimination of further complications. There is an absolutely paradoxical situation in the middle ear surgery, in terms of the criteria used to measure the progress. How can progress be evaluated? Logically, it is measured by post-operative results regarding the eradication of disease and the degree of hearing. Irrationally, therefore paradoxically, the criteria used to measure is both the technique and technology used in performing the surgery.

We must admit that today, the progress is invariably evaluated through the use of surgical microscope, high-speed milling, high power suction, focused illumination tools, biomaterials of latest generation, powerful antibiotics, and intensive care and general anesthesia, which are both at their current full potential.

We used above the noun *confusion* preceded by the adjective *huge*. Justification is needed. The confusion we are referring is generated by the semantics of two terms that are circulating today in oto-surgery, namely *Mastoidectomy* and *Tympanoplasty*. The etymological and historical analysis highlights those below clearly enough.

1). Acute middle ear suppuration which is always associated with hearing loss, found its remedy in *Cortical Mastoidectomy* or *Schwartze Operation*. It is admitted that after the widespread implementation of this operation (1873), thousands of children were saved of severe hearing loss; they were rescued from complications and even from death. It is a statement based on solid justification, namely on fundamental surgical principles, that any operation has two main objectives: treating the lesions and preserving the function.

2). Chronic middle ear suppuration, always associated with hearing loss, found its remedy in *Radical Mastoidectomy*. In the early period of the procedure, sanitation objective was considered much more important than the functional one. Moreover, the functional one was not even taken into account.

3). For the same disease, practice imposed as treatment, shortly after the period mentioned above, the technique of *Conservative Mastoidectomy*, in which the two fundamental goals of surgery found their logical balance, strictly respecting the primacy for the sanitation objective. This took place at the end of nineteenth century and at the early twentieth century. The functional goal was very well understood, as well as its secondary position toward the sanitation goal. The procedure continued to be called *Mastoidectomy* with clarifying adjectives to distinguish the *radical* from the *conservative* one. The term for *Tympanoplasty* has not been invented yet, but the concerns for preservation and improvement of hearing were consistent and well subordinate toward the sanitation goal. There were cases of hearing recovery even after *Radical Mastoidectomy* (later known as *spontaneous tympanoplasties*

and adopted by some oto-surgeons), however, we must admit that, after *Conservative Mastoidectomy*, recovery was met with an appreciable rate.

4). In 1950, *Horst Ludwig Wüllstein* of *Würtzburg (1906–1987)*, introduced the term *Tympanoplasty*, which referred to the functional purpose of a *Modified Radical Mastoidectomy*, but stressed that the sanitation is supposed to be the primary objective. The principles of *exposure*, *removal* and *exteriorization* of chronic infectious and inflammatory lesions of the middle ear [according to the definition of *Radical Mastoidectomy (1889)* by *Georg Ernst Ferdinand Küster (1839–1930)*, also valid for the *Modified Radical Mastoidectomy*] were respected. It needs to be emphasized that *the exteriorization goal* was abolished by covering the cavity with free skin grafts. Please note that there was an open cavity into the meatus, so the posterior bony wall was fully ablated. *Tympanoplasty* was therefore the final stage of the *Modified Radical Mastoidectomy* and consisted in grafting the tympanic membrane with free skin and in restoring the sound conduction mechanism in five ways, depending on the structures untouched by the disease or by the previous *Mastoidectomy*. In all of these situations, sanitation objective was dominant and required maximum level of performance, i.e the lesions were undisputedly removed if they were irreversibly damaged.

5). The term *Tympanoplasty* has aroused so much passion that after 50–60 years after its launch till present, has lost its original meaning. Consequently, it has abandoned its place as secondary objective in an intervention. More than that, it has usurped the authority of the first surgical aim – the sanitation, and this usurpation is the source of confusion mentioned above.

6). Tympanoplasty is now erroneously regarded and applied as a stand-alone procedure, even though sometimes the association with Mastoidectomy is mentioned, but on the basis of invalid criteria.

7). *Tympanoplasty* has become, from the second goal of a well-based intervention, a giant malign excrescence of *Mastoidectomy*, so that, if somehow the latter exists, it is not seen or explicitly talked about anymore. In most cases it is no longer taken into account; this condition is maintained by oto-surgeons' enthusiasm, fed in turn by the progress of technology.

8). In the historical phase of *Radical Mastoidectomy by all means*, the importance of the sanitation objective was exaggerated (a situation which fortunately lasted only a few years: (1889–1897). Nowadays the importance of the functional objective is exaggerated, a situation which has unfortunately been lasting for the last 50 years.

Figure no. 1. The structural principle of temporal bone. See how distance between the two cortical envelopes becoming larger, significantly increases the volume of diploic bone

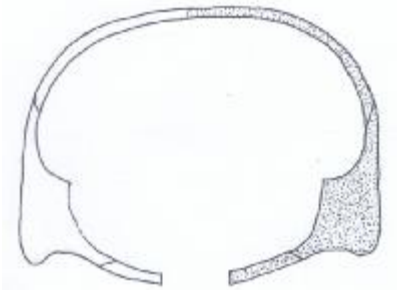

9). It is useful to question today's share for each of the three categories of oto-surgeons, identified by *Gordon D. L. Smyth (1929–1992)* of *Belfast* in 1963: 1). those who believe that *Tympanoplasty* is a good procedure or at least it has a future; 2). those who believe that the operation is not good and see no future for it; 3). those who are prepared to use modern techniques to repair a simple tympanic perforation.(4) Before answering this question, a classification by replacing the definition for the three groups of oto-surgeons will be provided: 1). overly progressives; 2). old fashioned (conservative); 3). opportunistic oto-surgeons. Today the first and the third categories have the largest share in detriment of the second category.

Figure no. 2. The structural principle of the temporal bone. See the cortical enclave of the otic capsule and how it's missing at the level of the axial middle ear cavities

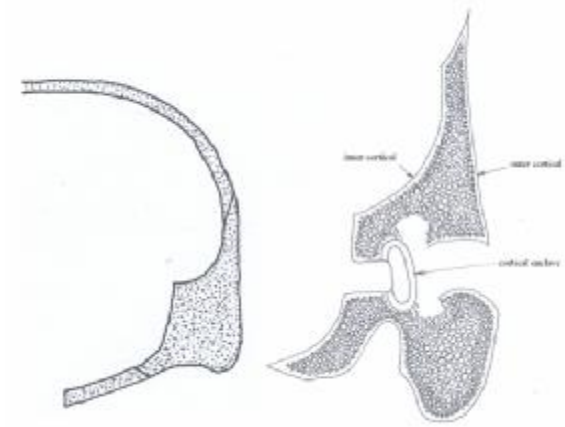

Figure no. 3. See antrum drilling from the supra-retro-meatic point in trans-cortical technique

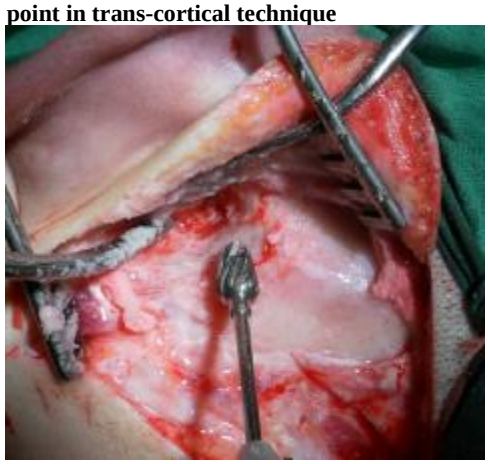

Figure no. 4. Hermann Hugo Rudolf Schwartze (1837–1919)



Figure no. 5. Sir Alfred Charles Ballance (1856–1936).

CONCLUSIONS

Having said that, we believe it has become clear that in terms of formal logic, the notion of *Mastoidectomy* is the dominant one, and in terms of surgical practice, *Mastoidectomy* is an operation in itself applied as a unique and rational treatment to a particular disease. On the other hand, *Tympanoplasty* is a subordinate concept to the one of *Mastoidectomy* and it is included in the sphere of the latter. By itself, Tympanoplasty cannot be a treatment for a particular disease.

Therefore, breaching these principles on a high scale, cannot be accepted. Techological progress applied with the purpose of preserving and improving by all means the hearing function , cannot serve as an excuse for a huge confusion.

It seems fair to us and sufficiently well founded to believe and to apply the classical principles of oto-surgery, because during their practice, they made possible the control of the treatment and evolution of the chronic suppuration and inflammation of the middle ear, with maximum safety. In other words, we consider very valid what the oto-surgeons have postulated up to *Sir Charles Alfred Balance (1856–1936)* (Figure no. 5) and what he masterfully synthesized has been fully proved in practice and by time. This point should be well understood. It's not a race against technology; on the contrary, we want to benefit from modern acquisitions, but only if valid theoretical principles are applied. The application of invalid principles should not be imposed only for the sake of technology as it is done nowadays.

Perhaps it was not the moment for such a trenchant discussion about the principles but it was made to highlight the topicality of the proposed subject despite the apparent anachronism. When any of these modern techniques fail, O*pen Technique* is used for solving these critical situations. *Open technique* is universally decreed as being the golden standard for middle ear cholesteatoma. To reiterate, this it is the only procedure verified by the test of time, for solving the chronic middle ear inflammation with maximum security.

Successful implementation of *Open Technique*, i.e good and very good postoperative results, both physical-sanitation and functional ones, depend not only on a number of incontrollable factors but also on a number of perfectly controllable factors, such as: the optimal surgical moment, the correctness and completeness of operative technique. The surgical procedure in discussion contributes significantly to improve the last two controllable factors listed above, this justifying its practical importance.

In the upcoming article, we'll describe the principle and the justification for this original procedure of *Modified Radical Mastoidectomy – External Acoustic Osseous Meatus Reaming*.

Acknowledgement

This paper is supported by the Sectoral Operational Programme Human Resources Development (SOPHRD), financed from the European Social Fund and by the Romanian Government under the contract number POSDRU/6/1.5/S/17.

REFERENCES

1. Fisch U., May J. Tympanoplasty, Mastoidectomy, and Stapes Surgery. Stuttgart; New York; Georg Thieme Verlag Thieme Medical Publishers; 1994. p. VII.
2. Cawthorne T. The Surgery of The Temporal Bone. Hunterian Lecture delivered at the Royal College of Surgeons of England on 1953 Feb 10; 403-23.
3. Jackler R.K. Foreword in Maurizio Barbara. Manual of temporal Bone dissection. The Hague, The Netherlands; Kugler Publications; 2002.
4. Smyth GDL. Prezent-day Concept of Tympanoplasty. Ulster Med J. 1963 Dec 32 (2): 160–167.
5. Ballance C.A. Essays on the Surgery of the Temporal Bone. London; Macmillan; 1919.
6. Hachmeister J.E. An Abbreviated History of the Ear: From Renaissance to Present. Yale Journal of Biology and Medicine. 2003 76: 81-86.)
7. House W.F., Sheehy J.L. Combined Approach Tympanoplasty. Archives of Otolaryngology 1963 78: 304
8. Mawson S.R. Disease of the Ear. Baltimore; The Williams and Wilkins Co; 1963.
9. Mawson S.R. Surgery of the Mastoid: the First Centenary. Proc R Soc Med. 1975 Jun 68: 391-395.
10. Maxwell E. The Evolution of the Mastoid Operation. Proc R Soc Med. 1967 May 60: 467-474.
11. Mollison W.M. Triumph and failures of the Mastoid Operation. A Brief Survey of the History of the Mastoid Operation. Proceedings of the Royal Society of Medicine. Section of Otology. 1929 Nov 1; 381–385.
12. Sheehy J.L., Crabtree J.A. Combined Approach Tympanoplasty – Staging. Laryngoscope 1973 83:.1574.