

# THE ROLE OF THE HIGH TIBIAL OSTEOTOMY IN UNICOMPARTMENTAL GONARTHROSIS

T. STANCIU<sup>1</sup>, M. SOPON<sup>2</sup>, I. BAIER<sup>3</sup>, A. LUPEAN<sup>4</sup>

<sup>1,2,4</sup>The Orthopedics – Traumatology Clinic – Sibiu, County Hospital Sibiu, <sup>3</sup>”Lucian Blaga” University, of Sibiu

**Keywords:**

unicompartmental  
gonarthrosis, high  
tibial osteotomy,  
unicompartmental  
prosthesis

**Abstract:** The aim of this study is to determine clinical and radiographs results in the treatment of unicompartmental gonarthrosis after medial tibial osteotomy with bone graft from the iliac crest associated with arthroscopy and knee débridement. Method: The study was performed in 19 patients treated with exploratory arthroscopy and articular débridement followed by medial opening tibial osteotomy in the proximal third with a bone graft stabilized with plate and screws or cramps. The pre and postoperative factors analyzed within this study are: age, KSS score, Alhback score, preoperative and postoperative knee varus and valgus alignment, ligament stability degree, immediate and late adverse events and patient satisfaction with the procedure. Conclusions: After investigations, we consider that high opening tibial osteotomy with bone graft from the iliac crest associated with débridement arthroscopy is an alternative in the treatment of the unicompartmental gonarthrosis, favoured by the precision of the arthroscopic diagnosis.

**Cuvinte cheie:**

gonartroza  
unicompartmentală,  
osteotomie înaltă de  
tobie, proteza  
unicompartmentală

**Rezumat:** Scopul acestui studiu este de a determina rezultatele clinice și radiografice în tratamentul gonartrozei unicompartmentale după osteotomia tibială medială cu greșă osoasă din creasta iliacă, asociată cu artroscopie și emondaj al articulației genunchiului. Metoda: Studiul a fost efectuat pe un număr de 19 pacienți. Factorii preoperatori și postoperatori analizați care intră în acest studiu sunt: vârsta pacientului, scorul KSS, scorul Alhback, gradul de deviere în valgus și varus al genunchiului pre- și postoperator, gradul de stabilitate ligamentară, complicațiile postoperatorii imediate și tardive plus gradul de mulțumire al pacientului. Concluzii: În urma investigațiilor efectuate considerăm că osteotomia de deschidere înaltă de tibie cu greșă osoasă din creasta iliacă asociată cu artroscopie cu emondaj articular este o alternativă în tratamentul gonartrozei unicompartmentale, favorizată de precizia diagnosticului artroscopic.

## INTRODUCTION

Gonarthrosis is a degenerative disease, as a result of a functional unbalance between the resistance of the articular structures and the mechanical stress exercised on them, generating a progressive wear of the cartilage in the maximum compression areas.

There are 3 stages in the evolution of the knee arthrosis phenomenon:

1. Only one articular compartment arthrosis (unicompartmental gonarthrosis);
2. Bi- and tricompartmental arthrosis;
3. Severe lesions arthrosis which generates an important and invalidating articular flexibility.

In the case of a normal knee about 60% of the weight is transmitted through the medial compartment, and the rest of 40% through the lateral compartment. (3) The treatment of gonarthrosis can be done by pharmaceutical, non-pharmaceutical means and surgical treatment.(7)

There are several methods for surgical treatment which vary from articular débridement arthroscopy to knee total arthroscopy. These methods can be grouped according to the following principles:

1. Surgical interventions to correct the inferior limb axis;
2. Surgical interventions to eliminate knee articulation;
3. Arthroplasty (unicompartmental, bi- or tricompartmental).

Among all the possible treatments the osteotomy is the only etiologic treatment method of gonarthrosis. This method allows rehabilitating the mechanic axis of the knee, and the long term positive results depend on the 2 to 8 degrees anatomic valgus made (1). In order to obtain a higher success rate, osteotomy is recommended in the unicompartmental cases of gonarthrosis.(4)

The effects of osteotomy can be: reduction of the intra-compartmental pressure by reorienting the articular surfaces, thus the pressure is transferred from the arthritic area to the healthy area of the articular cartilage; improvement of the metaphyseal and epiphyseal circulation, eliminating venous stasis and favoring the cartilage nutrition and its recovery in the affected area. (2).

## THE AIM OF THE STUDY

The aim of the study is to set the results of the treatment of unicompartmental gonarthrosis using high medial opening tibial osteotomy with bone graft from the iliac crest associated with exploratory arthroscopy and knee articular débridement.

## MATERIAL AND METHOD

The study is a retrospective one which took place between 2000 and 2004, on 18 patients, who underwent the treatment high medial opening tibial osteotomy with bone graft

<sup>1</sup>Corresponding Author: Stanciu Teodor Lucian; Clinical County Emergency Hospital of Sibiu Orthopedic and Traumatology Clinic, 2-4, C. Coposu street, cod 550245, Sibiu; Romania; e.mail: stanciuteodor@yahoo.com; tel: +40727307164

Article received on 08.04.2011 and accepted for publication on 26.07.2011

ACTA MEDICA TRANSILVANICA September 2011; 2(3)320-322

## CLINICAL ASPECTS

from the iliac crest associated with exploratory arthroscopy and knee articular débridement. All the subjects presented different degrees of medial unicompartmental gonarthrosis according to Alhback classification. For patient investigation there was an examination chart where the following aspects were analyzed pre-and postoperative: KSSS score (knee surgery society score), Alhback classification (frontal and profile radiographs), preoperative and postoperative knee varus and valgus alignment, ligament stability degree, immediate and late adverse events and patient satisfaction with the procedure.

The criteria considered for acceptance to the study were:

- gonarthrosis restricted to the internal compartment only;
- stable knee, no instability; knee flexion was limited to max. 90 degrees;
- there were no femoral –patellar manifestations; there were no pathologic manifestations at the level of meniscus; the obese patients were excluded from the study; special consideration was given to the vascular state of the treated inferior limb (severe obliterative chronic arteriopathy of the inferior limbs, severe venous thrombosis, varicose ulcer);
- the activity of the patient (the patients predisposed to obesity and sedentary life were advised for different treatment methods).

Taking into consideration that the patients accepted in the study presented no significant desaxation at knee level, the osteotomy treatment was meant mainly for the improvement of the metaphyseal and epiphyseal circulation, eliminating venous stasis and favoring cartilage nutrition and its recovery in the affected area. Thus, following opening osteotomy with bone graft a physiologic valgus of 6 to 10 degrees was not exceeded.

The initial surgical technique was the exploratory arthroscopy, used in a preoperative stage in order to assess the intra-articular lesions, associated, where necessary with sinovectomy of the affected compartments, partial, subtotal or total meniscectomy, periarticular osteophyte resection, shaving (removal) of the degenerated articular cartilage, and ablation of the foreign bodies associated with articulation rich lavage using saline solutions. (3)A corticospongious graft from the level of the ipsilateral iliac crest was harvested afterwards (followed by its adjustment according to the preoperative measurements). Then, a longitudinal approach at pes-anserinus level was done, at about 20 – 25 mm from the articular surface. Under radiological control a K wire is introduced parallel to the articular surface, and the osteotomy is conducted up to a level of about 1 cm from the lateral cortical of the tibia, followed by introducing the prepared graft. The graft was stabilized using a plate and screws. The position of the plate was confirmed intraoperative using intraoperative fluoroscopic control. The intervention was done under the tourniquet, and a drainage tube was mounted postoperative. Postoperative the patient was immobilized by means of cast plaster being banned from standing for 6 weeks. After the plaster was removed the patients followed an active recovery program focusing on the movements at the level of knee articulation to strengthen the muscles, without standing for a 3 months period after the surgery, depending on the radiological aspect of the osteotomy. The postoperative infection prophylaxis was done using second generation cephalosporins, given one dose in the preoperative stage and for 2-3 day in the postoperative stage. The venous thrombosis prophylaxis was done using low molecular weight heparins, Clexanne – 0.4 ml ampoule - 1 ampoule/day, subcutaneously, one dose in the preoperative stage and then postoperative during the hospitalization.

### RESULTS AND DISCUSSIONS

The study included 18 patients, 17 females and 1

male. The average follow-up period, starting with the surgery and up to the last check, expressed in months was 62.18 (the extreme values being 47 and 90 months). During the check we had a control radiograph of the knee (front and profile) and filled in a specific examining chart. The study was conducted on an average period of 5.18 years.

Most of the patients included in the study reported a reduction in pain along with an improved walking capacity: *Preoperative*: unlimited – 0 patients; over 1000 m – 10 patients; between 500 – 1000 m – 6 patients; under 500 m – 2 patients; *Postoperative*: unlimited – 7 patients; over 1000 m - 7 patients; between 500-1000m – 4 patients.

Thus, we registered an improvement of the KSS score reflecting the walking capacity of the patients, from a preoperative score of 34.44 to postoperative score of 42.77.

The movement amplitude increased in the case of 7 patients, remained unchanged in the case of 9 patients and reduced in the case of other 2 patients.

We registered pain reduction, going from a preoperative average value of 25 – to a postoperative average value of 38.125. The first stage, according to Alhback classification, could be seen during the radiographic exam of the knee in both the preoperative and postoperative stage, with a slight narrowing of the articular space at the level of the internal compartment of the knee articulation.

The total KSS scored increased from a preoperative average value of 64 (values between 58 and 70) to 80.5 (values between 67 and 99), which indicates the positive effect of high tibial osteotomy on knee functionality.

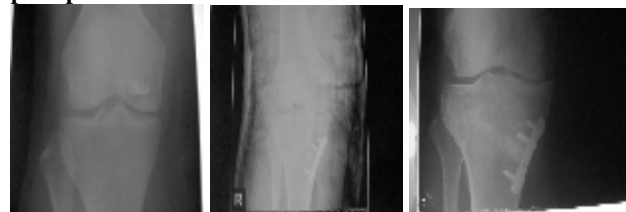
An important criterion taken into consideration during the study was patient satisfaction. Thus the postoperative results were: unsatisfied – 0 patients; satisfied – 4 patients; good – 9 patients and very good 5 patients.

There was only one postoperative event: a female patient who presented a hematoma at the level of the iliac crest, which later became infectious. Adopting a specific treatment (evacuation, drainage and antibiotic treatment according to the antibiogram) the evolution was a favorable one without influencing in any way the functional prognosis of the patient.

Further on we present 3 cases with preoperative and postoperative radiographs.

I. Female patient - B.I., aged 50, preoperative functional KSS score 70, and 42 months postoperative functional KSS score 90 with unlimited walking possibilities with a pain score of 50 (lack of pain). We mention that the patient presents a 10 degree extension deficit. (Figure 1)

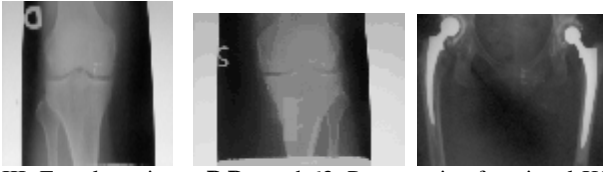**Figure no. 1. Patient B. I.a.Preoperative b. Immediate postoperative c. Control**



II. Female patient - M.D. Aged 49, this patient presents as well a congenital luxation of the hip, underwent a bilateral surgery, and was in her 59 months postoperative period, with a preoperative functional KSS score of 70, and a postoperative score of 99, 120 degree movement amplitude, with a walking capacity exceeding 1000 m, the limitation is in fact due to the pain felt at the level of the hips. (Figure 2)

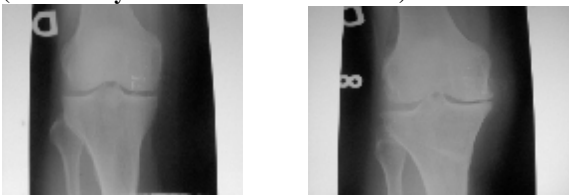
**Figure no. 2. Patient M.D. a. Preoperative b. Postoperative c. Bilateral hip arthroplasty**

## CLINICAL ASPECTS



III. Female patient - P.P. aged 63. Preoperative functional KSS score 60, and at 66 months after the surgery, the functional postoperative KSS score 70 with a walking capacity exceeding 1000 m, it is worth mentioning that in the preoperative stage the walking capacity was reduced to a 500-1000m distance, 120 degree movement amplitude and a pain score of 30 (a slight pain when climbing and walking), it is worth mentioning that in the preoperative stage this score was 10 (less than 500m). The osteosynthesis material was stopped postoperative a year after the surgery at the patient's request. (Figure 3)

**Figure nr. 3. Patient P.P. a. Preoperative b. Postoperative (after osteosynthesis material extraction)**



### CONCLUSIONS

The clinic and paraclinic data recorded in this study, show a favorable evolution in the case of patients treated using this method. The association of high medial opening tibial osteotomy with a bone graft from the iliac crest with exploratory arthroscopy and knee articular débridement, represents a treatment method which should be taken into consideration, as it is well received by patients, who present a low rate of postoperative complications; the method has lower costs as compared to other methods, as well. The main advantage of this treatment method is the necessity of only one osteotomy, without the risk of affecting the peroneal nerve. The accuracy of the surgical technique as well as the process of patient selection represents the most important factors in order to have an increased success rate after high tibial osteotomy.

*„Research done within POSDRU/6/1.5/S/26 project, co financed by the European Social Funds by means of the Sectoral Operational Program for the Development of the Human Resources 2007 – 2013”*

### BIBLIOGRAPHY

- Magyar, G.; Toksvig-Larsen, S.; Lindstrand, from the University Hospital, Lund, Sweden - Open wedge-osteotomy by hemicallotasis or the closed wedge technique for osteoarthritis of the knee - JBJS British May 1999, volume 81-B, number 3
- Billings, Annette, M.D.†; Scott, David F., M.D.‡; Camargo, Marcelo P., M.D.§; Hofmann, Aaron A., M.D. - High tibial osteotomy with a calibrated osteotomy guide, rigid internal fixation, and early motion, long term follow up -, JBJS American, January 2000, Volume 82-A, number 1
- Rees, J. L., Frcs; Price, A. J., Frcs; Lynskey, T. G., Frcs; Svård, U. C. G., MD; Dodd, C. A. F., Frcs; Murray, D. W., MD, Medial unicompartimental arthroplasty after high tibial osteotomy - JBJS British, September 2001, Volume 83-B, Number 7
- Marti, René K., MD, PHD; Verhagen, Ronald A. W., MD; Kerkhoffs, Gino M.M. J., MD; Moojen, Thybout M., MD, Proximal tibial varus osteotomy, JBJS, February 2001, Volume 83-A, Number 2
- Insall & Scott - Surgery of the knee – fourth edition , volume two 2006
- D. Antonescu - Elemente de ortopedie și Traumatologie –, București 1999
- E. Proca - Tratat de Patologie Chirurgicală –, Ed. Medicală 1988
- Campbell's Operative orthopaedic's -, ninth edition, edited by S. Terry Canale