

VERTEBROPLASTY IN THE TREATMENT OF OSTEOPOROTIC FRACTURES: OUR EXPERIENCE

M. SOPON¹, C. MATEI², I. BAIER³, A. LUPEAN⁴

^{1,2,4} Emergency Clinical County Hospital of Sibiu, ³ "Lucian Blaga" University of Sibiu

Keywords:

vertebroplasty,
osteoporotic vertebral
fracture, vertebral
pedicle, pediculul
vertebral

Abstract: The aim of this study is to emphasize the effects of vertebroplasty from the clinical point of view and the influence on the adjacent joints. **Materials and methods:** Between 2009 and 2010 we conducted 9 vertebroplasty procedures at the level of T12 to L3. To follow-up patients both before and after the surgery, besides the clinical examination, they were also taken spinal radiographs and MRI to examine the adjacent vertebrae and the zygapophyseal joints and determine the adjacent vertebral bodies. The vertebroplasty was done by bipedicular approach using general anesthesia. The vertebroplasty procedures efficiently reduce pain; the vertebroplasty procedures do not reconstruct the size of the body of the vertebra; in case of important wedge fractures there can be a progression of the kyphotic angle as the vertebral joints are worn out and influence the intervertebral discs

Cuvinte cheie:

vertebroplastia,
fractura vertebrală
osteoporotică,
pediculul vertebral

Rezumat: Lucrarea își propune să evidențieze efectul vertebroplastiei din punct de vedere clinic și efectul asupra articulațiilor adiacente. **Material și metodă:** În perioada 2009-2010 s-au efectuat un număr de 9 vertebroplastii cuprinse între T12 și L3. Pentru examinarea pacienților atât preoperator cât și postoperator s-au efectuat pe lângă examenul clinic al pacientului, radiografiile și examenul RMN ale coloanei vertebrale pentru examinarea vertebrelor adiacente, articulațiilor zigoapofizare și măsurători ale corpilor vertebrali adiacenți. Vertebroplastia s-a efectuat prin abord bipedicular sub anestezie generală. **Concluzii:** vertebroplastiile asigură o diminuare eficientă a durerii atât; vertebroplastiile nu refac înălțimea corpului vertebral; în țesăturile importante poate apărea o progresie a unghiului cifotic cu creșterea uzurii la nivelul articulațiilor vertebrale și cu influență asupra discurilor intervertebrale..

INTRODUCTION

Vertebroplasty is a mini-invasive procedure used to introduce transpedicular polymethylmethacrylate (PMMA) in the body of the vertebra, under radiological control. This used to be and still is a frequently used procedure for the treatment of the osteoporotic fractures. Osteoporosis is a more frequent diagnosis taking into consideration the extension of life expectancy. Osteoporosis affects a large number of the elderly population, with significant impacts on their health and financial status, if we are to take into consideration the economic aspects. Statistics show that in the United States of America in 2003 almost 10 million people were diagnosed with osteoporosis. Other 18 million people were known to have low bone mass with risks to generate osteoporosis or fractures. (1) Also, the studies in the USA show that more than 1.5 million vertebral fractures are due to osteoporosis, 500,000 of them being hospitalized, 800,000 of them are registered to the emergency room, 180,000 need medical home care. All these cost the American Medical System about 12 – 18 billion dollars. In Europe the costs are estimated at about 25 billion euro every year and it is foreseen that they will increase so as that in 2025 they will be about 31.8 billion euro for all types of osteoporotic fractures. (2) It is estimated that about 500,000 white females aged over 50 in the USA suffer from fractures of the vertebral body. (3) In Romania osteoporosis has began to be a real social problem. This is due mainly to bad alimentation of the elders, sedentariness and deficiencies of the geriatric medical care.

The vertebral cortical bone is made of a compact bone and the structure and the specific trabecular orientation generate maximum resistance with a minimal bone structure. (4) The vertebral trabecula in the case of young people are dense and form a 3D structure of horizontal and vertical trabecula. Once we get older the connectivity between trabeculas reduces and the trabecula get thinner, especially the horizontal ones. This leads to micro-fractures reducing the resistance of the vertebrae to the external stress, which reduces the strength of the body of the vertebra against the external stress. (5)

The osteoporotic vertebral fractures of the vertebral body at the level of the dorso-lumbar spine change the normal parameters of the spine curves which alter the spine equilibrium influencing the daily activities of the individual. (6)

THE AIM OF THE STUDY

The aim of the study is to show the benefits of vertebroplasty, as a mini-invasive surgical procedure, for the treatment of osteoporotic vertebral fractures.

MATERIAL AND METHOD

Percutaneous vertebroplasty represents a surgical procedure developed for the treatment of the osteoporotic vertebral fractures. The main advantage of this procedure is that it allows fast mobilization of the patient, reducing the pain significantly. This aspect can influence the adjacent vertebra with zygapophyseal joints. The study included 10 vertebroplasty procedures conducted between 2009 and 2010, located between

¹Corresponding Author: M. Sopon, Emergency Clinical County Sibiu, Clinica Ortopedice-Traumatologie, 2-4, C. Coposu street, cod 550245, Sibiu, Romania; e-mail: mirceasopon@yahoo.com; tel +40-0740170265

Article received on 28.12.2010 and accepted for publication on 22.03.2011
ACTA MEDICA TRANSILVANICA December 2011; 2(4)268-270

CLINICAL ASPECTS

T11 and L3. All patients underwent percutaneous, bipedicular approaches using the trocar under radioscopic control and general anesthesia. The Poly(methyl methacrylate) (PMMA) to be used is combined with Barium sulfate to get the necessary radio-opacity while this is injected in the body of the vertebra. The quantity of PMMA injected in each body of the vertebra ranged between 3 to 9 ml.

In order to follow-up patients both before and after the surgery besides the clinical examination, they were also taken spinal radiographs and MRI to examine the adjacent vertebrae and the zygapophyseal joints and determine the adjacent vertebral bodies. The height of the anterior edge of the fractured vertebral body, as well as of the suprajacent and subjacent vertebrae, were measured on the profile radiographs. On the profile radiographs we could also measure the Cobb angle formed by the affected vertebra and the suprajacent and subjacent vertebrae, both before and after the surgery. By means of the MRI we could follow the changes that took place at the level of the adjacent zygapophyseal joints (less than 1mm was considered normal, more than 1 mm was considered to be pathological), at the level of the intervertebral disc, at the level of the injected vertebral body, both before and after the surgical procedure. All fractures were the result of minor incidents. The surgical procedures were done within a 2 to 6 weeks period after the patients suffered the trauma, in the case of the patients who still reported pain symptoms after receiving specific treatment (rest, thoracolumbosacral orthosis, antialgic and anti-inflammatory treatment) as well as in the case of patients who did not present neurological manifestations.

RESULTS AND DISCUSSIONS

The study included 10 patients, out of whom 6 female patients and 4 male patients. The follow-up period extended up to 1 year after the surgical procedure.

The pain was evaluated using the VAS score (Visual Analogue Score), and it was determined before and after the surgery, as well as 1 year after the procedure. The VAS score registered significant improvements after the surgery and the values were still preserved a year later. Thus, if the average values ranged between 7 and 9 before the surgery, the average values were between 2 and 4 the very first day after the surgery, and 1 year later they were between 2 and 5. (Table 1)

Table no. 1 VAS and ODI scores: before the surgery, soon after the surgery and 1 year later..

	Before the surgery	After the surgery	One year later
VAS	7 - 9	2 - 4	2 - 5
ODI	50- 75%	-	45-50%

The evaluation of the patient's day-to-day activities was done using the ODI questionnaire (Oswestry Disability Index). This instrument was conceived to evaluate the limitations the individuals encountered due to the back pains in the case of 10 activities; using a scale of 0 to 5 (5 being the maxim pain value). The score is expressed using percentage, and shall be read as follows: 0-20% minimal incapacity; 20-40% moderate incapacity; 40-60% severe incapacity; 60-80% partial disability; 80-100% total disability. (7)

As a result of the measurements of the Cobb angle and the anterior edge of the vertebral body on the profile radiographs we could notice that in 9 of the cases there were no obvious changes when comparing the values registered before and after the surgery. There was one exception, though, where, after the surgery, the height of the vertebral body where the PMMA was injected decreased and at the same time the kyphotic angle increased from 15 to 25 degrees. In the case of the same patient

the MRI showed an increase value of the synovial fluid at the level of the adjacent zygapophyseal joints as well as a mild oedema at the interface between the PMMA and the spongy bone of the vertebral body. We have to mention the fact that in this case there were only 3 ml of PMMA injected in the vertebral body. (Figure 1) The patient does not present neurological manifestations, the VAS score is 7.5, the ODI score is 50%, and therefore the patient is kept under clinical observation

Figure no. 1 Radiograph and MRI - 1 year after the surgery

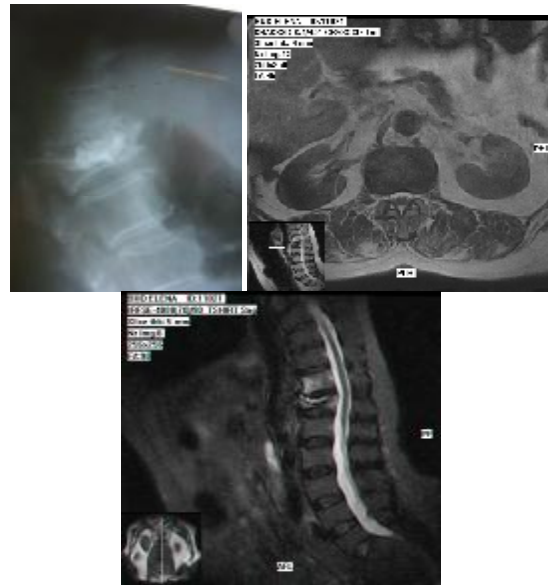
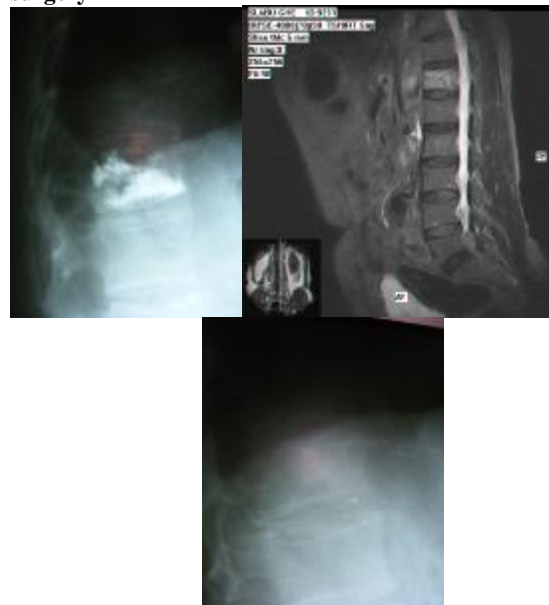

Figure no 2: Radiograph and MRI – before and after the surgery



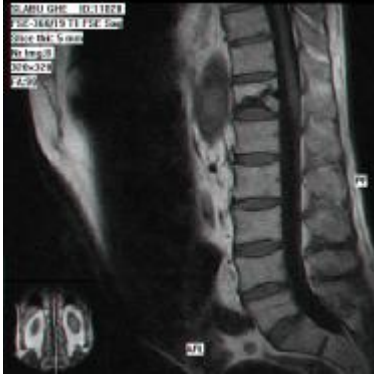In the cases where no decrease of the height of the vertebral body neither an increase of the kyphotic angle was registered, the MRI showed no changes at the level of the joints or the vertebral bodies adjacent to the affected vertebra. (Figure 2,3)

Thus, it is proved that vertebroplasty is an efficient procedure for the treatment of the osteoporotic vertebral fractures, significantly reducing the pain which allows a fast mobilization of the patient.

CLINICAL ASPECTS

We would like to emphasize that these results represent only the preliminary results as we are to conduct a further study on a larger group of subjects followed-up for a longer period of time, but for the moment the study shows our own experience in using this procedure in order to treat osteoporotic vertebral fractures..

Figure no. 3. RMN aspect at one year postsurgery



CONCLUSIONS

The vertebroplasty procedures ensure significant back pain decreases, both soon after the surgery and after a longer period of time, allowing the patient a better social life. The vertebroplasty procedures do not allow reconstructing the height of the vertebral body, and in the cases of important burst fractures of the vertebral body as well as those when a smaller quantity of PMMA is injected there can appear an increase of the kyphotic angle, influencing the adjacent vertebral articulations.

„Researches realized during the project POSDRU/6/1.5/S/26 cofinanced from the Social European Fond through the Operational Sectorial Development Programme of the Human Resources 2007 – 2013”

BIBLIOGRAPHY

1. Tony S. Keller, PhD, Deed E. Harrison, DC, Christopher J. Colloca, DC, Donald D. Harrison, DC, PhD and Tadeusz J. Janik, PhD - *Prediction of Osteoporotic Spinal Deformity* - SPINE Volume 28, Number 5, pp 455–462 ©2003
2. Gass M, Dawson-Hughes B *Preventing osteoporosis-related fractures: an overview*. Am J Med (2006) 119:S3–S11
3. Melton LJ III, Lane AW, Cooper C, et al. *Prevalence and incidence of vertebral Deformities*. Osteoporos Int 1993;3:113–9.
4. Mosekilde L. Vertebral structure and strength *in vivo* and *in vitro*. *Calcif Tissue Int* (Suppl. 1): (1993)S121–S125
5. Anthony D Woolf, Kristina Åkesson – *Osteoporosis*, Clinical Publishing, Oxford 2008
6. Hall SE, Criddle RA, Comito TL, et al. *A case-control study of quality of life and functional impairment in women with long-standing vertebral osteoporotic fracture*. Osteoporos Int 1999;9:508–15.
7. Fairbank JC, Couper J, Davies JB, O'Brien JP. The Oswestry low back pain disability questionnaire. *Physiotherapy*. 1980 Aug;66(8):271-3 - The original description of the ODI. Fairbank J, Pynsent P. The Oswestry Disability Index. *Spine* 2000;25:2940–53