

SUBMANDIBULAR AND LATERO – CERVICAL PHLEGMON AS A RESULT OF A PERIAPICAL PATHOLOGY

M. I. FAGEȚAN¹, IRINA IVAN²

¹Octavian Oprean Dental Office, ²“Lucian Blaga” University of Sibiu

Keywords: phlegmon, drain, surgery, antibiotherapy, radiography

Abstract: The phlegmon is a diffused suppuration with an extensive character, with no suppurated collection. It is characterized by vascular thrombosis, extended necrosis and the presence of gaseous blisters. The sinderite tissue is infiltrated with sanguinolent serosity, rarely purulent, very fetid that often contains gas, due to the anaerobe germs. From a bacterial point of view, the phlegmon contains an unspecific flora, but is extremely polymorph. The American authors define these clinical forms of infection that are extremely severe, by the terms: “cellulites”, acute cellulites or “malignant cellulites”, which can be confused with the term “cellulites”, a term we use to define a serosity inflammation that can be reversible. The general condition is marked by the presence of the toxic-septic syndrome.

Cuvinte cheie: flegmon, drenaj, chirurgie, antibioterapie, radiografie

Rezumat: Flegmonul este o supurație difuză cu caracter extensiv, în care nu există o colecție supurată. Se caracterizează prin tromboză vasculară, necroză extinsă și prezența bulelor gazoase. Țesuturile siderate sunt infiltrate cu o serozitate sanguinolentă, rareori sangvinopurulentă, foarte fetidă adesea conținând gaze, din cauza germeilor anaerobi. Din punct de vedere bacteriologic, flegmoanele conțin o floră nespecifică, dar extrem de polimorfă. Autorii americani numesc aceste forme clinice de infecții extrem de severe cu termenii de “celulită”, “celulită acută” sau “celulită malignă”, fapt ce poate produce confuzii cu termenul de “celulită”, noi desemnând până în prezent inflamația de tip seros, care poate fi reversibilă. Starea generală este marcată de prezența sindromului toxico-septic.

INTRODUCTION

The phlegmon is characterized by the progressive evolution, severity of general phenomena, especially toxic-septic, irregular pulse and temperature and organic lesion on a distance. From an etiopathogenic point of view, the phlegmon has the same local-regional causes as the abscess, but in the appearance of this particular form of suppuration there are also: low resistance of the area with earlier organic deficiencies, debilitating diseases, therapy with immunosuppressive, over-exertion, or a wrongly conducted treatment with antibiotics. The gravity and the fast evolution of the diffused septic process impose an energetic and precocious treatment, by associating surgery with drug treatment, to sustain the general condition, but also the treatment with antibiotics.

CASE STUDY

The following clinical case study presents the importance of determining and removing the factors that are causing it and applying a medical treatment accordingly.

The toxic-septic shock appears in an infectious context, after bacteria invade the vascular bed, and the acute vascular insufficiency settles in, as well as the cytotoxic effect due to the results of the inflammatory mediators that have a very important role in the pathogenesis of the toxic shock.

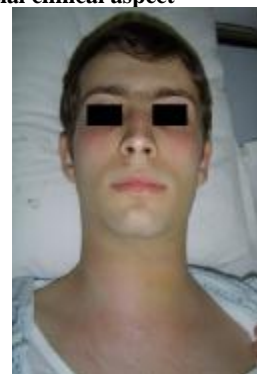The clinical picture of the toxic-septic shock is represented by the presence of a local or general infection, cyanotic/marbled extremities, tachycardia, hypotension/dyspnea, agitation, convulsion, fever, coma, cardio-respiratory collapse.

The evolution of the toxic-septic shock has three phases: the phase of the warm hypotension (compensated shock) represented by hyperthermia, warm and dry teguments,

tachycardia, hypotension, anxiety. The second phase is the “cold hypotension” (decompensate shock): moist and cold teguments, cyanotic extremities, hypotension, tachypnoea. The third phase is that of the “irreversible shock” represented by hypothermia, collapsed blood pressure, confusion, and coma.

I had under observation an 18 years old patient, male, with toxic-septic syndrome, first admitted in the infectious diseases section and later transferred because it was determined that the starting point was dento-paradontal.

Figure no. 1. Initial clinical aspect



The mandibular space is situated in the posterior floor of the mouth, and is limited by the fascian muscle, superficial cervical platysma and teguments, and upper-median from the mucosa of the floor of the mouth, the milohyoid and hyoglossal muscle.

The space contains the submandibular gland, lingual nerves and hypoglossal, lymph nodes, facial and lingual arteries

¹Corresponding author: I. M. Făgețan. Str. Șerbota, Nr. 6, Sibiu, România, E-mail: imfagetan@yahoo.com, Tel: +40745 605540
Article received on 25.06.2012 and accepted for publication on 23.08.2012
ACTA MEDICA TRANSILVANICA December 2012;2(4):300-301

CLINICAL ASPECTS

and veins, lax conjunctive tissue and the proximal part of the Warton canal.

The patient started the treatment with antibiotics (Imipenem) but without favourable results, and after the clinical and paraclinical exam, it was noticed on the Rx OPT an infectious, periapical process on the 3.7.

Figure no. 2. Initial paraclinical aspect

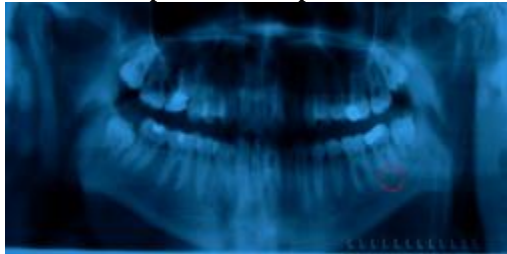
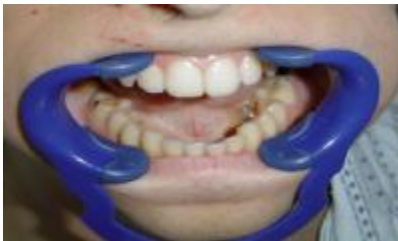

Figure no. 3. Endooral exam



During a specialized examination in the BMF (Bucamaxilo-facial) section, the presence of a submandibular and lateral cervical left side phlegmon was noticed.

Clinically, the suppuration starts with the tumefaction of the submandibular loja that has a rapid evolution and a massive growth in volume. The covered teguments do not show signs of acute inflammation, but in advanced cases they become grey-purple, marbled and with blistering that are necrosing slowly.

Palpation with both hands show pain and phlegmon durity "wood phlegmon" without areas of fluctuation. If it is an advanced phase, then gaseous crepitation may occur.

The oral exam is difficult to perform because of the thrismus, and during the inspection you can see pale, atonic tissue, infiltrated in a sanguinolent serosity or sometimes sanguino purulent, very fetid, that often contains gases because of the anaerobi germs. The tongue is increased in volume, tumefied, and pushed down the throat. The patient has signs of hypersalivation, painful deglution, halitosis, accentuated trismus and functional disorder. The general state is altering in the two first days and starts a toxic-septic character.

The positive diagnose is established according to objective clinical signs and the toxic septic state of the patient.

The differentiated diagnose is established with the infected submandibular lithiasis, suppuration of the submandibular space malign tumour of the oral floor of the mouth or metastasis submandibular adenopathy.

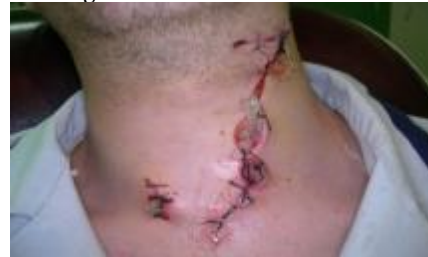Surgical treatment

A surgical urgent treatment was initialized by incision and draining of all the affected areas, applying draining tubes in which antiseptic pumping are performed over 7 days. The crectotic tissue and the causing teeth was removed and a therapy with antibiotics was started (Amoxicilin, Gentamicin) according to the antibiogramme together with the volume rebalancing. (when admitting blood pressure - 80/40 mmHg; AV 120).

The local treatment is completed by a general one that involves administering antibiotics with a larger area of action, vitamins.

A favourable evolution of the disorder is represented by the appearance of pus, growing of the fever, and the disappearance of the toxic-septic phenomena. As the purulent secretion diminishes, the draining tubes can gradually be left aside or replaced by thinner tubes of polyten that help maintaining the draining paths and also allow the opened spaces to heal.

Figure no. 4. Surgical treatment



Conclusions

From a frequently seen pathology, in the absence of a corresponding treatment, one can go to deep suppuration and even death, determining and removing the causing factor. It is important to correlate all the data, to establish all treatment possibilities and then to choose the adequate treatment procedure. Each patient represents a particular case, in this case an immunosuppressant field.

BIBLIOGRAPHY

1. Burlibaşa C. Chirurgia orală și maxilofacială; 1995. p.332-337.
2. Bucur A. Chirurgia orală și maxilofacială; 2007. p. 296-301.
3. Donoff BR. Manuel de chirurgie orale et maxillo-faciale, Masson et Cie, Paris; 1990.
4. Timoşca G, Burlibaşa C. Chirurgie buco-maxilo-facială, Edit. Didactica și Pedagogica, Bucuresti; 1983.
5. Rotaru Al. Urgențe, riscuri și dificultăți în practica stomatologică, Edit. Dacia, Cluj-Napoca; 1992.
6. Popescu V, Burlibaşa C. Tehnici curente de chirurgie stomatologică, Edit. Medicală, Bucuresti; 1966.
7. Ployet MY, Borderom JC, et al. Les cellulites faciales aigues; 1988. p. 533-573.
8. Topazian RG, Goldenberg MH. Management of infection in the oral and maxillofacial regions; 2002. p. 231-236.
9. Moraru I, et al. Anatomie patologică, Edit. Medicală, Bucuresti; 1980.
10. Hine WK, Levy M. A text book of oral pathology; 1983. p. 129-135.