

# COMPLICATIONS AFTER ESWL IN THE TREATMENT OF RENO-URETERAL LITHIASIS

THEODOR NICOLA<sup>1</sup>, SEPTIMIU VOIDĂZAN<sup>2</sup>, DENISA MONCEA<sup>3</sup>, MARIA MIHAELA OPRÎȘ<sup>4</sup>, VIRGIL OȘAN<sup>5</sup>

<sup>1,2,4,5</sup>University of Medicine and Pharmacy Tîrgu-Mureș, <sup>3</sup>County Emergency Clinical Hospital Tîrgu-Mureș

**Keywords:** ESWL, hematoma, infection, complications

**Abstract:** Introduction: Approximately 80-90% of reno-ureteral calculi have an indication of being solved by Extra Corporeal Shock Wave Lithotripsy (ESWL). Like any therapeutic procedure, extracorporeal lithotripsy may be accompanied by complications. Most are minor complications, but in a lower percentage, major complications can occur. Hematoma is the most serious complication of extracorporeal lithotripsy, fortunately with a low incidence. Acute pyelonephritis (PNA) occurs either due to a pre-existing urinary infection, or by the release of germs inactivated into calculi during fragmentation. Material and method: We used a retrospective study on a group of 1659 patients for which were performed 2287 ESWL treatments by Siemens Lithostar. We note the major complications that occurred after the ESWL treatment and the predisposing factors for complications. Results: Major complications (renal and perirenal hematoma, acute pyelonephritis) represented a percentage of 11.03% of all complications, respectively only 2.05% of all the investigated patients. Our data shows that the presence of hypertension in the patients with urolithiasis is a risk factor for hematoma after treatment (OR: 7.07, CI: 2.48-20.1, p-0.0001). The presence of urinary tract infections before lithotripsy is a risk factor for the occurrence of pyelonephritis after ESWL (OR: 6.9, CI: 2.7-17.3, p-0.0001). Conclusions: Major complications after ESWL appeared in very small percentages. The chances for the lithiasic and hypertensive patient to develop renal hematoma post ESWL, and also for the patient with urinary infection to make post ESWL pyelonephritis, are large.

**Cuvinte cheie:** ESWL, hematom, infecție, complicații

**Rezumat:** Introducere: Aproximativ 80-90 % din calculii reno-ureterali au indicație de rezolvare prin litotriție extracorporeală (ESWL). Ca orice procedură terapeutică, litotriția extracorporeală poate fi însoțită de complicații. Majoritatea sunt complicații minore, dar într-un procent mai redus pot să apară și complicații majore. Hematomul constituie cea mai gravă complicație a litotriției extracorporeale, din fericire cu o incidență scăzută. Pielonefrita acută (PNA) survine fie pe fondul unei infecții urinare preexistente, fie prin punerea în libertate a germenilor inclavați în calcul în timpul fragmentării. Material și metodă: S-a apelat la un studiu retrospectiv pe un lot de 1659 de pacienți pentru care s-au efectuat 2287 tratamente ESWL cu ajutorul litotritorului Lithostar Siemens. Am urmărit complicațiile majore care au apărut după efectuarea tratamentului ESWL, precum și factorii favorizanți pentru apariția complicațiilor. Rezultate: Complicațiile majore (hematom renal și perirenal, pielonefrită acută) au reprezentat un procent de 11.03 %, din totalul complicațiilor, respectiv doar 2.05 % din totalul pacienților investigați. Din datele noastre rezultă că prezența HTA la pacienții cu litiază renală reprezintă un factor de risc pentru apariția hematoamelor după tratament (OR: 7.07; IC: 2.48-20.1; p-0.0001). Prezența infecțiilor de tract urinar anterior litotriției reprezintă un factor de risc pentru apariția pielonefritelor post ESWL (OR: 6.9; IC: 2.7-17.3; p-0.0001). Concluzii: Complicațiile majore după ESWL apar în procente foarte mici. Șansele pacientului litiazic și hipertensiv de a face hematom renal post ESWL, respectiv a pacientului cu infecție urinară de a face pielonefrită post ESWL, sunt mari.

## INTRODUCTION

In the last two decades, there has been a significant change in reno-ureteral lithiasis treatment, and currently, about 80-90% of reno-ureteral calculi have an indication of being solved by extracorporeal lithotripsy (ESWL).(1)

The success rate depends on the lithiasis characteristics (calculi size, location, composition, obstruction), clinical factors (severity of symptoms, patient expectations, associated infections) and technical factors (equipment available, costs etc.).(2)

Like any therapeutic procedure, extracorporeal lithotripsy may be accompanied by complications. Most are

minor complications (hematuria, renal colic, uncomplicated Steinstrasse), but in a lower percentage major complications can occur (renal and perirenal hematoma, acute pyelonephritis, complicated Steinstrasse), the latter requiring special attention and sometimes surgery to solve them. Extracorporeal lithotripsy complications are present in approximately 7% of patients.(3) Hematoma is the most serious complication of ESWL, fortunately with a low incidence. Most are small hematoma, subcapsular, often asymptomatic, discovered on routine ultrasound checks post-ESWL.

A small number of patients require selective embolization of an end arteries or surgical drainage solution, or

<sup>1</sup>Corresponding author: Theodor Nicola, Str. Ghe Marinescu, Nr. 50, Tîrgu-Mureș, România, E-mail: nicolatheodor@yahoo.com, Tel: +40745 920753  
Article received on 16.11.2011 and accepted for publication on 20.12.2012  
ACTA MEDICA TRANSILVANICA March 2013;2(1):275-278

## CLINICAL ASPECTS

even nephrectomy. There was a higher incidence of post-ESWL hematoma in hypertensive patients, and also in those with diabetes or anticoagulants.(4,5,6) Acute pyelonephritis (PNA), occurs either due to a pre-existing urinary infection, or by the release of germs in claved into calculi during fragmentation. Thus, pre-ESWL urine culture and antibiogram are required, and also prophylactic antibiotic treatment is indicated post-ESWL.(7)

### PURPOSE

The study aims at determining the prevalence of renal and subrenal hematoma, respectively pyelonephritis as major complications that can occur after practicing ESWL for reno-ureteral lithiasis in our unit.

### METHODS

We used a retrospective study by analyzing the records of the hospitalized patients in the Department of extracorporeal lithotripsy in Tîrgu-Mureş, between January 2010 and December 2011. 2056 patients were hospitalized, of which 1741 had calculi at different levels of the urinary tract. Of these, 82 were treated exclusively by auxiliary methods, remaining in study only 1659 patients for which were performed 2287 ESWL treatments by Siemens Lithostar.

We observed the major complications that occurred after ESWL treatment and the predisposing factors for complications. We have excluded from the patients with complications, those who had only post-ESWL hematuria and renal colic just as they appear in most patients. To highlight the potential complications, ultrasound and radiologic exam were performed 24 hours after the extracorporeal lithotripsy.

All interventions were performed in the Department of extracorporeal lithotripsy in Tîrgu-Mureş which is equipped with Siemens Lithostar lithotripter, a second generation lithotripter, with head of disintegration, System C, with direct contact between the treatment head and patient's skin. The device is based on electromagnetic effect, having a radiological system location and focusing of flat stones.

#### Statistical analysis

All statistical calculations were performed using the Graph Pad Software, San Diego, California, USA. Associations between the distribution of major complications and risk factors (presence of hypertension or urinary tract infections) were tested using the contingency tables and the Chi-square test.

We calculated the OR (estimated risk) to demonstrate the probability of developing complications according to the risk the factors mentioned. All the tests we have performed to the threshold of significance of  $p=0,05$ , and the statistical significance was considered for  $p$ -values less than the threshold value of significance.

### RESULTS

In the studied range, a group of 1659 patients were diagnosed with reno-ureteral lithiasis who underwent ESWL, and in whom 308 (18.5%) complications occurred. Major complications (renal and perirenal hematoma, acute pyelonephritis) accounted for a percentage of 11.03% of all complications, respectively only 2.05% of all patients investigated.

The distribution of patients according to gender and age groups is shown in table no. 1. Approximately 60% of the patients who underwent ESWL were male. The average age of the entire group was  $45.34 \pm 11.15$  (mean  $\pm$  SD), 77.9% of complications occurring in the age range between 31 and 60 years old.

**Table no. 1. Distribution of patients according to gender and age groups**

Variability		Total patients treated by ESWL no. (%)	Patients with post-ESWL complications: no. (%)	% of total patients' complications
Gender	Males	967 (58.3 %)	170 (55.2 %)	17.6 %
	Females	692 (41.7 %)	138 (44.8 %)	19.9 %
Age groups	20-30	185 (11.1 %)	41 (13.3 %)	22.2 %
	31-40	431 (26.0 %)	75 (24.4 %)	17.4 %
	41-50	371 (22.4 %)	67 (21.8 %)	18.1 %
	51-60	541 (32.6 %)	98 (31.8 %)	18.1 %
	61-70	116 (7.0 %)	24 (7.8 %)	20.7 %
	71-75	15 (0.9 %)	3 (0.9 %)	20.0 %
<b>Total</b>		<b>1659</b>	<b>308</b>	

ESWL procedure in the patients with complications was applied to 256 persons (83.2%) who had single stones and 52 people (16.8%) who had multiple stones (two or more stones).

308 patients had 364 stones, mostly located in the kidney, respectively 68.4% (249 stones). Complications of kidney stones: most were located in pyelon (47.4%), followed by stones located in the lower calyx (27.7%) and kidney stones depending on the location, the highest percentage of post-ESWL complications were identified for stones located in the pyelon (30.8%) (table no. 2).

**Table no. 2. Distribution of patients according to the location of kidney stones**

Location		Number of calculi treated by ESWL	Number of calculi in patients with complications	% of complications depending on the location of stones
Kidney	Calyx multiple calculi	187	13	6.9 %
	Superior Calyx	90	16	17.7 %
	Middle Calyx	74	9	12.2 %
	Inferior Calyx	516	69	13.4 %
	Pyelon	383	118	30.8 %
	PUJ	98	24	24.5 %
<b>Total kidney</b>		<b>1348 (67.4 %)</b>	<b>249 (68.4 %)</b>	<b>18.5 %</b>

Most of the ureteral calculi were located in the third upper ureter (49.5%) (table no. 3), and in relation to all ureteral stones treated with ESWL, most post-therapy complications were reported for those situated in the lumbar ureter (third upper ureter: 23.6%).

Calculi dimensions in complicated cases ranged between 0.3 and 20 mm (262 calculi less than 10 mm, 102 between 10 and 20 mm), with a mean of  $7.8 \pm 2.5$  mm.

In patients with complications, 430 ESWL sessions were practiced, in most cases one session was necessary (66.6%) for 27.4% of patients, two ESWL sessions were performed and in other cases, (5.9%), 3 or 4 ESWL treatments were applied.

The time for ESWL sessions ranged from 40-45 minutes, and the total pulse ranged between 3000 and 4000, with a predominance pulse intensity of 3000 (95.7%).

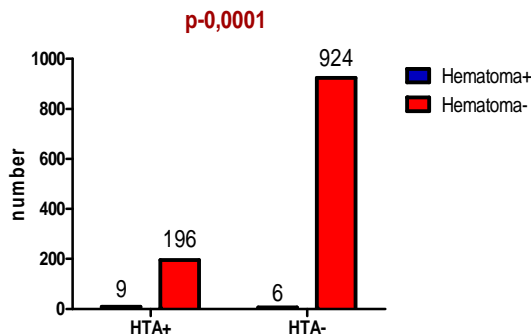
## CLINICAL ASPECTS

**Table no. 3. Distribution of patients according to the location of ureteral calculi**

Location		Number of calculi treated by ESWL	Number of calculi in patients with complications	% of complications depending on the location of stones
Ureter	Superior 1/3	241	57	23.6 %
	Middle 1/3	72	13	
	Inferior 1/3	340	45	
<b>Total ureter</b>		<b>653 (32.6 %)</b>	<b>115 (31.6 %)</b>	<b>17.6 %</b>

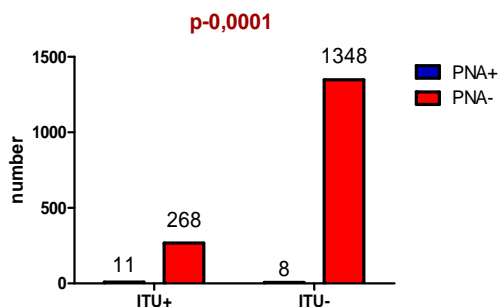
The complications after ESWL are directly proportional with the intensity of the shock waves, lithotripsy session number, structure and size of stones. Of all complications, only a percentage of 11.03% represented the major complications that have interested us (renal and perirenal hematoma or acute pyelonephritis). Of the patients with urolithiasis (1135), who were treated with ESWL, 205 had hypertension under medical treatment. Renal hematoma after ESWL occurred in 15 patients, 9 of whom were hypertensive. Our data shows that the presence of hypertension in the patients with urolithiasis is a risk factor for hematoma after treatment (OR: 7.07, CI: 2.48-20.1, p=0.0001).

**Figure no. 1. Distribution of post-ESWL hematoma in normotensive patients versus hypertensive patients**



Of all patients with reno-ureteral lithiasis (1635), who were treated by ESWL procedure, 279 presented urinary tract infection. Post-ESWL, 19 patients developed acute pyelonephritis. The presence of urinary tract infections before lithotripsy is a risk factor for the occurrence of pyelonephritis after ESWL (OR: 6.9, CI: 2.7-17.3, p=0.0001). The germs most frequently identified in the urinary infections were E. coli (17.3%), Proteus (13.4%) and Klebsiella (9.6%), but in many cases, we identified urinary infections of unspecified etiology.

**Figure no. 2. Distribution of post-ESWL acute pyelonephritis in the patients with urinary infection versus patients with sterile urine**



## DISCUSSIONS

Since ESWL is a noninvasive method of treatment, the other methods to resolve reno-ureteral lithiasis began to lose field in favour of ESWL.(8,9) Still, open surgery, percutaneous nefrolitotomia and endoscopic interventions are very important for calculi bigger than 2.5-3 cm and also, in resolving other complications that can occur post-ESWL. To highlight the potential complications, it is important to carry out an ultrasound and X-ray examination 24 hours after the extracorporeal lithotripsy. Any patient with reno-ureteral lithiasis is a potential candidate for extracorporeal lithotripsy and the careful evaluation of the numerous features of patients may increase the treatment success and especially decrease the rate of complications.(10)

With all the advantages it presents, extracorporeal lithotripsy is not without risks. It is known that renal hematoma may appear in hypertensive patients. For this reason, extracorporeal lithotripsy is contraindicated in the patients with untreated hypertension or uncontrolled by treatment, until the blood pressure achieves acceptable values.(5,11). Some studies show an incidence of subcapsular hematoma between 0.2-1.6% at an ultrasound examination performed after ESWL.(12,13,14,15,16)

In our study, 15 patients (0.9%) were identified with renal hematoma post-ESWL.

Among these, 12 were subcapsular renal hematoma of posterior valve, one of the anterior valve and one of the inferior pole. None required surgical drainage, only observation in time and conservative treatment. One patient presented a perirenal hematoma and he also required only observation and conservative treatment. Of all the patients with kidney stones treated by extracorporeal lithotripsy, 205 were diagnosed with hypertension and they were under medication for maintaining it in normal values. Some of these, 9 (4.4%) had renal hematoma post-ESWL. Thereby, the probability for the patients with kidney stones and hypertension to develop a renal hematoma post-ESWL is 7.07 times higher than in the normotensive patients with kidney stones.

In case of associated acute urinary infection, the extracorporeal lithotripsy is contraindicated. When lithiasis is followed by pyelonephritis, antibiotic treatment is required and to perform "cold" lithotripsy after the acute phase of infection.(5,17)

It is required to perform urine culture and pre- ESWL antibiogram. These allow us starting the antibiotic treatment in the patients with urinary infections with 24-48 hours before practicing ESWL. The antibiotic susceptibility testing allows us to quickly choose an antibiotic to be administered in severe cases of post-ESWL pyelonephritis.(5,18)

Among all patients in our clinic with reno-ureteral stones, who were treated with extracorporeal lithotripsy, 279 presented before, urinary tract infection. Of these, 11 had post-ESWL acute pyelonephritis. The chances of the patients with urinary stones and urinary tract infection are 6.9 times more likely to develop acute pyelonephritis after treatment than the patients with urinary lithiasis without associated urinary tract infection.

## CONCLUSIONS

1. ESWL represents the treatment of choice for kidney and ureteral stones less than 20 mm.
2. Major complications (renal and perirenal hematoma, pyelonephritis) can occur, but in very small percentages. In our study, these complications occurred in 2.05% of cases.
3. However, unrecognized and untreated properly in time can endanger the patient's life.

## CLINICAL ASPECTS

- The chances of the lithiasic and hypertensive patient to develop renal hematoma after ESWL, respectively the patient with urinary infection to develop post ESWL pyelonephritis are high.

### Acknowledgement:

*This paper is partly supported by the Sectoral Operational Programme Human Resources Development (SOP HRD), financed from the European Social Fund and by the Romanian Government under the contract number POSDRU 80641 and POSDRU 60782.*

### REFERENCES

- Sinescu I, Gluck G, et al. *Tratat de Urologie*, Ed. Medicală, București. 2008;2:1027-1132.
- Lingeman JE, Matlaga BR. Surgical management of upper urinary tract calculi. In: Wein AJ, Kavoussi LR, Novick AC, Partin AW, Peters CA, editors. *Campbell-Walsh urology*. 10th ed. Philadelphia: Saunders; 2010. p. 1375-1377.
- Oșan VG. *Urologie*, Ed. University Press, Tîrgu Mureș; 2003. p. 101-120.
- Ambert V, Chira I, Jinga V, et al. Complicațiile pe termen scurt consecutive litotriției extracorporale a calculilor pielocaliceali, *Revista Română de Urologie*; 2010. p. 9-2:33.
- Oșan VG, Simion C. Litotriția extracorporală în tratamentul litiazei reno-ureterale, Ed. University Press, Tîrgu Mureș; 2005. p. 15-131.
- Pastor NH, Carrión LP, Martínez RJ, et al. Renal hematomas after extracorporeal shock-wave lithotripsy (ESWL). *Actas Urol Esp*. 2009 Mar;33(3):296-303.
- Fujita K, Mizuno T, Ushiyama T, et al. Complicating risk factors for pyelonephritis after extracorporeal shock wave lithotripsy, *Int J Urol*. 2000;7-6:224-30.
- Kirkali Y, Mungan MU, Arslan G, et al. Is there still a place for surgery in the treatment of ureteral stones? *Acta Urol Belgica*. 1997;65(3):35-40.
- Paik ML, Wainstein MA, Spirnak JP, et al. Current indications for open stone surgery in the treatment of renal and ureteral calculi, *J Urol*. 1998;159:374-379.
- Ceban E. The treatment of the reno-ureteral calculi by extracorporeal shockwave lithotripsy (ESWL). *J Med Life*. 2012 Jun 12;5(2):133-8.
- Collado SA, Hugué PJ, Monreal García de Vicuña F, et al. Renal hematoma as a complication of extracorporeal shock wave lithotripsy. *Scand J Urol Nephrol*. 1999 Jun;33(3):171-5.
- Domínguez Molinero JF, Arrabal MM, Miján Ortiz JL, et al. Renal hematomas secondary to extracorporeal shockwave lithotripsy. *Arch Esp Urol*. 1997 Sep;50(7):767-71.
- Dhar NB, Thornton J, Karafa MT, et al. A multivariate analysis of risk factors associated with subcapsular hematoma formation following electromagnetic shock wave lithotripsy. *C J Urol*. 2004 Dec;172(6 Pt 1):2271-4.
- Orozco Fariñas R, Iglesias Prieto JI, Massarrah Halabi J, et al. Renal hematoma after extracorporeal shockwave lithotripsy in a series of 324 consecutive sessions with the DOLI-S lithotripter: incidents, characteristics, multifactorial analysis and review. *Arch Esp Urol*. 2008 Oct;61(8):889-914.
- Gallego Sánchez JA, Ibarlucea González G, Gamarra Quintanilla M, et al: Renal hematomas after extracorporeal lithotripsy with the lithotripter "lithostar multiline de Siemens". *Arch Esp Urol*. 2007 Jun;60(5):565-8.
- Kostakopoulos A, Stavropoulos NJ, Macrychoritis C, et al. Subcapsular hematoma due to ESWL: risk factors. A study of 4,247 patients. *Urol Int*. 1995;55(1):21-4.
- Qi H, Luo C, Liu C. Treatment of urosepsis induced by extracorporeal shock wave lithotripsy: analysis of 4 cases. *Nan Fang Yi Ke Da Xue Xue Bao*. 2012 Oct;32(10):1523-4.
- Vakalopoulos I, Paraskevopoulos S, Radopoulos D. Is urinary tract infection after shock wave lithotripsy an aggravating factor for renal damage? *Arch Esp Urol*. 2010;63(6):454-459.