

PRINCIPLES AND MINIMALLY INVASIVE TREATMENT TECHNIQUES USED IN THE CURRENT TREATMENT OF DENTAL CARIES

GHEORGHE CORNEL BOITOR¹

¹“Lucian Blaga” University of Sibiu

Keywords: dental caries, minimally invasive preparation, risk factors

Abstract: The traditional treatment of dental caries gives great importance to achieving certain types of cavities in all patients, regardless of the risk of carious disease. This requires a major sacrifice of the healthy tissues, regardless of whether these injuries are hollow or not. Unlike the classic concept, the modern concept of treatment is based as a priority on the maximum conservation of the hard tooth structure integrity and influencing factors that can cause early wound healing or passivation or the surcease of the other wounds.

Cuvinte cheie: caria dentară, pregătire minim invazivă, factori de risc

Rezumat: Modelul tradițional de tratament al cariei dentare acordă o importanță deosebită realizării unor tipuri de cavități la toți pacienții, indiferent de riscul la boală carioasă. Acest fapt presupune un sacrificiu important de țesuturi sănătoase, fără a ține cont dacă aceste leziuni sunt cavitare sau nu. Spre deosebire de acest concept clasic, conceptul modern de tratament are la bază ca prioritate, conservarea la maxim a structurii dentare dure integre și influențarea factorilor care pot determina vindecarea leziunilor incipiente, respectiv stoparea sau pasivizarea celorlalte leziuni.

INTRODUCTION

The medical treatment of caries disease involves the determination of individual risk and preferably the establishment of a minimally invasive treatment according to the existing risk category.

The condition for healing enamel early lesions is keeping the integrity of organic texture (collagen fibril network).

The same importance is for dentin organic network, because at this level too, by stimulating remineralisation it can slow down / stop the progression of caries in dentin.

The concept of minimally invasive dentistry called by some authors „conservative”, imply the renunciation of the classical conservative treatment focused on building cavity and focusing the efforts on the health dental tissue economy and stimulating the remineralisation of the early lesions.

PURPOSE

We aimed at presenting the approach of some carious processes, developed on frontal incisors at an early stage, by the minimally invasive treatment method.

Techniques and minimally invasive treatment methods

Essentially minimally invasive treatment requires early diagnosis which allowed changing the classic cavity contour and achieving as conservative as possible. For this method, a set of cutters are used for specific temporary or permanent teeth. A set of firm Mills NTI (Germany) is shown in figure no. 1.

The patient, C.A., aged 15 years old is coming to the dental office by own initiative, accusing discrete colour changes in the two upper central incisors.

The initial appearance of the patient is shown in figure no. 2.

Figure no. 1. Drill set for the minimal invasive preparation

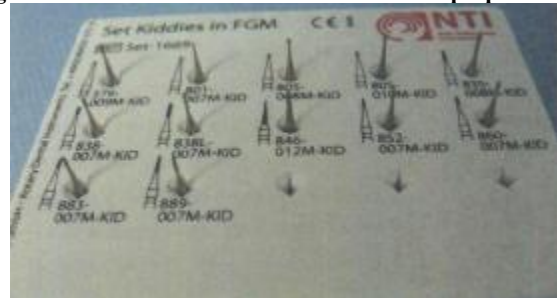
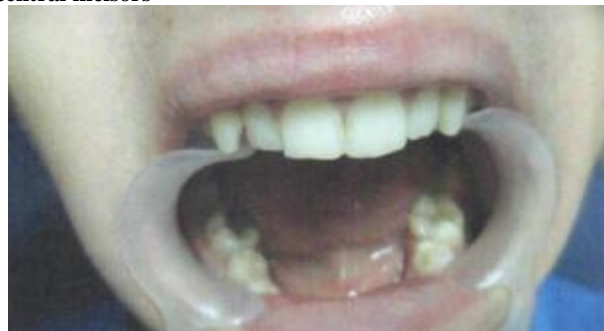

Figure no. 2. Initial aspect with discreet colour change at the central incisors



If the caries location is on the proximal sides of the front teeth, the minimally invasive technique includes the following options to address:

- oral or vestibular approaching, depending on location through a hole of slot type or finger glove type;

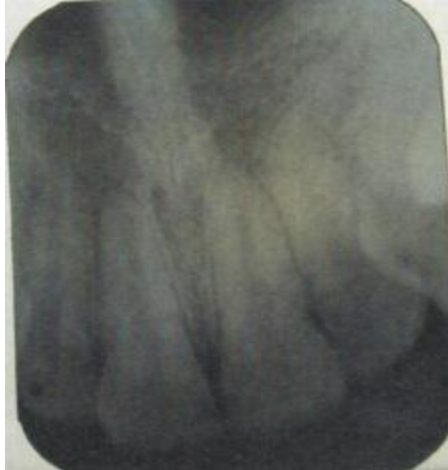¹Corresponding author: Boitor Gh. Cornel, Str. Amnaș, Nr. 7A, Sibiu, România, E-mail: boitorcornel@yahoo.com, Tel: +40740 175420
Article received on 12.02.2013 and accepted for publication on 15.04.2013
ACTA MEDICA TRANSILVANICA June 2013;2(2):269-270

CLINICAL ASPECTS

- addressing from the proximal side, when the neighbouring tooth is missing, resulting a simple cassette cavity.

Since the lesions were not directly approachable, I used complementary examination with common retro-alveolar radiography. The extending carious process is shown in the radiological image in figure no. 3.

Figure no. 3. Radiographic aspect of decay processes



To prepare cavities in this case, I chose to remove the minimum layer from 0.25 to 0.50 mm of enamel incisal third marginal ridges (due to the particular location of the carious process) with a pear-shaped diamond cutters.

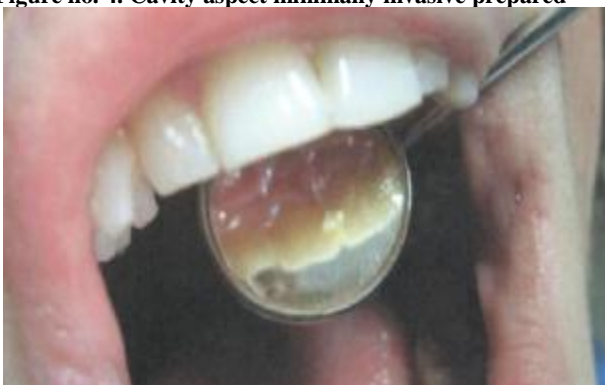After the enamel removal stage, with a globular cutter of hard materials blades, I have acted in the carious process direction to the feeling of "falling into a hole".

Altered dentin excision was performed at conventional globular speed drills of appropriate size. I did not want to increase the beam angles of the cavity walls, but a rigorous removal of the affected dentine mainly the enamel-dentine limit.

Marginal enamel was bevelled with spherical diamond cutter at conventional speed to achieve adhesive filling by well-known techniques.

Minimally invasive prepared cavities aspect is shown in figure no. 4.

Figure no. 4. Cavity aspect minimally invasive prepared



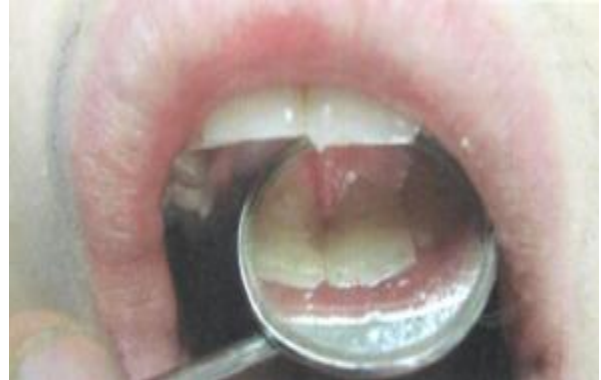After cavity conventional toilet with hydrogen peroxide, I moderately dry it and hybridized the dental wound with adhesive composite kit Point 4 (Kerr Hawe).

As a basis, I used the firm's composite fluid Kerr Point 4 flowable and then, by adhesive method, I applied lasting curing filling material corresponding to colour shade.

The final aspect of restoration is shown in figure no. 5.

For longer maintaining the treatment results, the patient was counselled regarding the control of the risk factors to caries.

Figure no. 5. Final aspect of the accomplished restoration



Conclusions:

In the case of patients with caries at medium or low risk, the minimally invasive technique can be applied that provides a minimum cavity preparation with a few tools. Using bioactive materials (slow release fluoride), it provides additional security for this technique. In patients at high risk for caries, it is recommended the two-step approach.

The first step is to conduct a brief training cavities followed by the development of glass ionomer cement restorations, to stabilize the caries disease (fluoride ion release reduces the risk) and the control of the microbial factor. Then, it comes the second stage of treatment, which will remove the ionomer cement which will be finalized after minimally invasive cavity preparation and will clog the cavity with lasting restorative materials.

BIBLIOGRAPHY

1. Ericson D. The concept of minimal invasive dentistry, *Dent Update*. 2007;34 (1):12-14.
2. Summit JB. Conservative cavity preparations. *Dent Clin North Am*. 2002;29:46(2):171184.
3. Peters MC, et al. Minimally invasive operative care: I. Minimal intervention and concepts for minimal invasive cavity preparations. *J Adhes Dent*. 2001;3(1):7-16.
4. Peters MC, et al. Minimally invasive operative care: II. Contemporary techniques and materials – an overview. *J Adhes Dent*. 2001;3(1):17-31.
5. Tyas MJ, et al. Minimal intervention dentistry: a review, FDI Commission Project 1-97, *Int Dent J*. 2000;50(1):1-12.
6. Ericson D, Kidd E. Minimally invasive dentistry – concepts and techniques in cariology. *Oral Health Prev Dent*. 2003;1(1):59-72.