

SURGICAL CONDUCT REGARDING THE MALIGNANT CERVICAL ADENOPATHIES. TYPES OF NECK DISSECTIONS

ALBERTINA STĂNILĂ¹, DAN SABĂU², MIHAI RUSU³, ANCA FRĂȚILĂ⁴, MARIANA SABĂU⁵

^{1,2,3,4,5}“Lucian Blaga” University of Sibiu

Keywords: malignant cervical adenopathies, neck dissection, cervical lymph nodes, tumour process

Abstract: The prognosis of tumours in the OMF region is greatly affected by the status of the cervical nodes; therefore the presence of malignant cervical adenopathies causes a much lower survival rate than in the patients without these enlarge lymph nodes.(1,2) In terms of therapeutic conduct, surgery provides insights into the regional extension of the tumour, but also the best alternative treatment of the therapeutic curative behaviour.

Cuvinte cheie: adenopatii maligne cervicale, evidare ganglionară, ganglioni limfatici cervicali, proces tumoral

Rezumat: Prognosticul tumorilor din regiunea OMF este influențat considerabil de statusul ganglionilor cervicali, așadar prezența adenopatiilor cervicale maligne determină o rată a supraviețuirii mult mai scăzută comparativ cu pacienții care nu prezintă aceste adenopatii.(1,2) Din punct de vedere al conduitei terapeutice, chirurgia oferă perspective asupra extinderii regionale a tumorii, dar în același timp reprezintă cea mai bună variantă de tratament a conduitei terapeutice curative.

Neck dissection is an essential surgical procedure for local treatment that involves excision of the primary tumor and of the loco-regional extension, in our case the extension is represented by a malignant cervical lymphadenopathy (lymph nodes along with the submandibular gland, superficial and middle cervical fascia, muscles, vessels, fat tissue etc.).

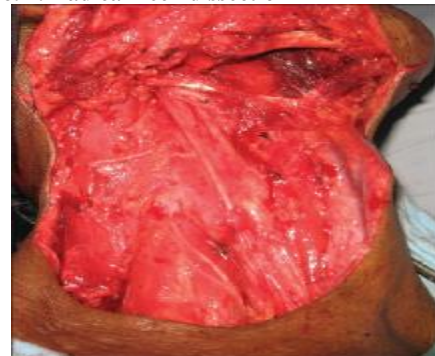The classification of the neck dissection techniques is achieved primarily by lymph nodes groups to be removed,(4) and secondly according to the anatomical structures to be preserved, such as the spinal accessory nerve, the sternocleidomastoid muscle and the internal jugular vein etc.

The standardization of the neck dissections techniques assumes the existence of four major categories, namely:(2,3)

1. Radical neck dissection
2. Modified radical neck dissection (subtype I, II, III)
 - subtype I (conservation: spinal nerve);
 - subtype II (conservation: spinal nerve, the internal jugular vein);
 - subtype III (preservation of the spinal nerve, the internal jugular vein and the sternocleidomastoid muscle).
3. Selective neck dissection:
 - supraomohyoid neck dissection;
 - lateral (jugular)neck dissection;
 - postero-lateral neck dissection;
 - anterior neck dissection;
4. Extended modified radical neck dissection or extended selective neck

Radical neck dissection is the essential therapeutic conduct for malignant cervical adenopathies which realize complete removal of the node groups from the neck levels I-V and of non-lymphatic structures, the spinal nerve, the sternocleidomastoid muscle and the internal jugular vein.(2,5)

Figure no. 1. Radical neck dissection



This type of neck dissection removes completely the lymphatic fat tissue from the clavicle to the mandible, respectively from the anterior margin of the trapezius muscle (posterior) to the midline of the neck, but also retains some cervical lymph node groups such as the parotid, suboccipital, retropharyngeal, paratracheal or superior mediastinal lymph nodes, failing to achieve their removal.(3)

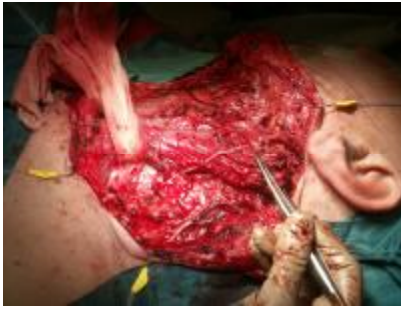Modified radical neck dissection keeps one or more structures that do not belong to the lymphatic system such as the spinal nerve, sternocleidomastoidian muscle, internal jugular vein and at the same time removes the submandibular, submental, jugular superior, middle and inferior lymph nodes as well as the lymph nodes located around the lower part of the spinal accessory nerve and along the transverse cervical vessels, are removed the same lymph nodes groups as for radical neck dissection.(2,3,5)

¹Corresponding author: Albertina Stănilă, Str. Aleea Mirăslău, Nr.13, Șelimbăr, Sibiu, România, E-mail: sas_albertina@yahoo.com, Tel: +40757 060347

Article received on 17.01.2013 and accepted for publication on 22.03.2013
ACTA MEDICA TRANSILVANICA June 2013;2(2):222-223

CLINICAL ASPECTS

Figure no. 2. Modified radical neck dissection



Selective neck dissection refers at removal of the primary tumour according to the process topography, only of the lymph nodes groups involved.(3) It presents 4 subtypes:

- **-supraomohyoid neck dissection:** particularly appropriate for neoplasms with primary starting point oral cavity, which requires strictly removing the lymph nodes groups I, II and III;
- **-lateral (antero-lateral) neck dissection:** suitable for tumour processes with primary starting point, hypopharynx, oropharynx and larynx, targeting cervical lymph nodes levels II, III, IV;

Figure no. 3. Selective neck dissection in continuity with the oral cavity

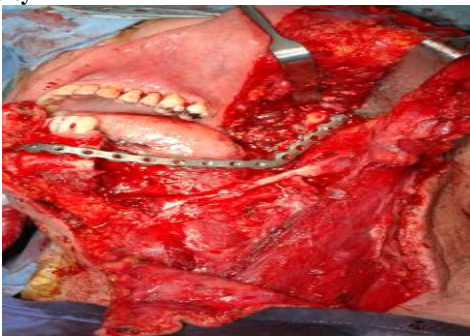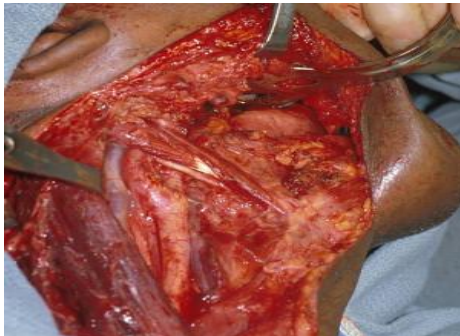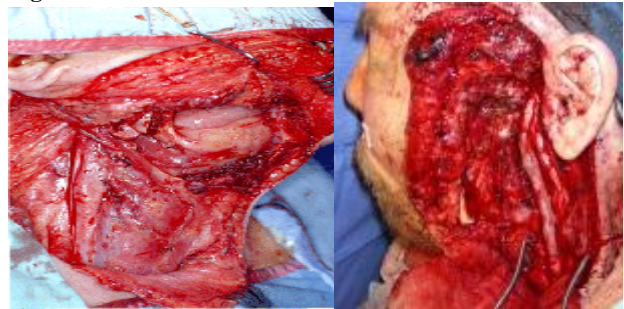


Figure no. 4. Selective neck dissection



- **postero-lateral:** indicated for neoplasm with primary starting point the scalp of the posterior region of the head, it refers to lymph nodes levels II, III, IV, V and the suboccipital, retroauricular lymph nodes and of the cervical triangle nodes, the posterior limit of the dissection is being represented by the anterior margin trapezoid muscle;
- **anterior:** indicated for tumour processes with primary starting point the thyroid gland, refers to the removal of the lymph nodes that are strictly on the level VI cervical (the prelaryngeal and pretracheal nodes, the thyroid region and the tracheoesophageal tract region) the lymph nodes ranged from the hyoid bone to the sternal notch, lateral to the sheath of the large vessels

Figure no. 5. Extended radical dissection



The extended modified radical neck dissection or extended selective neck involves the removal of the additional lymph nodes groups or non lymphatic structures which were not included in the classic radical neck dissection, such as upper mediastinal, paratracheal lymph nodes etc.(2,5)

Conclusions:

The standardization of the neck dissection techniques aims at maximizing the therapeutic results obtained and at facilitating their reporting. Each patient requires personalised treatment scheme, based on the primary tumour process location and the stage and location of the metastasis in the lymph nodes.

Because of the early postoperative local and remote complications that generate a high percentage of morbidity, frequently occurring complications after radical neck dissection, the trend in the recent decades is to practice selective neck dissection which is a cervical neck dissection limited strictly to primary tumour process and to lymph node groups specifically involved.(4)

REFERENCES

1. Cardesa A, Slootweg PJ. (Eds.). Pathology of the Head and Neck, ISBN-10 3-540-30628-5 Springer Berlin Heidelberg New York.
2. Ashok RS. Radical Neck Dissection, Operative Techniques in General Surgery. 2004;6(2):72-82.
3. Avilan JG, Herranz J, DeSanto LW, Gavilan C. Functional and selective neck dissection, TMP ISBN 1-58890-016-9, GTV ISBN 3 13 124631 6, USA.
4. Lucioni M. Practical guide to Neck Dissection, ISBN 978-3-540-71638-9 Springer Berlin Heidelberg New York.
5. www.entdev.uct.ac.za/index_files/Page650.htm.