TICK-BORNE ENCEPHALITIS SIMULTANEOUSLY WITH LYME DISEASE, COMPLICATED WITH BRONCHOPNEUMONIA

VICTORIA BÎRLUŢIU[1], RAREŞ MIRCEA BÎRLUŢIU[2]

[1] *"Lucian Blaga" University of Sibiu*

Keywords: *coinfection-tick encephalitis-Lyme disease*

Abstract: *We present the case of a man of 34 years, with professional risk of tick bites that was admitted to the Infectious Diseases Department of Sibiu County Hospital with acute meningoencephalitis with a biphasic evolution, with positive IgM serology for tick-borne encephalitis and Lyme disease, complicated by bronchopneumonia.*

Cuvinte cheie: *coinfecţie-encefalita de căpuşă-boala Lyme*

Rezumat: *Prezentăm cazul unui bărbat de 34 ani, la risc de muşcături de căpuşă profesional, internat în secţia Boli Infecţioase a Spitalului Clinic Judeţean Sibiu cu meningoencefalită acută, cu evoluţie bifazică, cu serologie IgM pozitivă pentru encefalita de căpuşă şi boala Lyme, complicată cu bronhopneumonie.*

INTRODUCTION

Tick-borne encephalitis (TBE) is caused by a flavivirus with three subtypes: Siberian, European and Russian Spring Summer encephalitis virus, they are transmitted to humans through the tick bite, species Ixodes ricinus or persulcatus, there are sporadic cases described in Europe and in the eastern part of Asia. In 2006 numerous cases have been reported in Russia, Poland, Germany, Lithuania and Slovenia. The type of clinical picture developed is meningoencephalitis, sometimes associated with myelitis and a severe evolution in half of cases occured in adults with possible neuropsychiatric sequelae and risk of death in 1% of cases. The evolution is biphasic, with general symptoms accompanied by asymptomatic period (1), then in the second week meningocerebral manifestation appear like tremor, cerebellar ataxia, disorders of the state of consciousness, spinal cord impairment, paralysis of the respiratory muscles, cranial nerves- oculomotor, glossopharyngeal, facial, vestibulocochlear paralysis. May be associated with other transmitted diseases by tick bite, a particular situation that we intend to present is the coinfection of TBE-B.burgdorferi.

CASE PRESENTATION

Male patient, 34 years old, from the rural environment, livestock breeder, is admitted through the Emergency Department on 22 June 2012, 10 days after the onset of progressive fever (unmeasured), headache, loss of appetite, afterwards vomiting, for which he carried out on its own initiative an outpatient treatment with antipyretic, pain reliever without improvement, therefore he requests to be admitted. The patient denies any chronic disease, is a smoker of 30 cigarettes/day, from the age of 12 he occasionally consumes alcohol, he denies insect stings.

The physical examination shows a patient with alteration of general condition, fever 38.6^{0}C, with pale skin, first degree of dehydration, stetacustic bilateral basal lung emphasized murmur without rales, respiratory rate (RR) 26/min, SaO_2 93%, HR 72 / min, BP 120/80 mmHg, white tongue, painless abdomen on palpation, with signs of meningeal irritation: neck stiffness, outlines Kernig, Babisnki bilateral present and osteotendon hyperreflexia.

Laboratory examination: leukocytes: 8ooo/mm^3, erythrocytes 4.7 mil/mm ^{3}, HGB =14.8g/dl, HCT=42%, MCV=89.6 fL, MHC=31.5 pg, MCHC=35.2g/dl, PLT= 114000/mm^3, NEU 76.5%, LYM 17.7%,MONO=5.8%, CRP<6mg/dl, fibrinogen 395.9mg/dl, glucose=92mg/dl, BUN(Blood Urea Nitrogen) 25mg/dl, creatinine 0.75 mg / dL, SGOT 22U/L, SGPT 19U/l, QT =12,0 sec (85,2%), INR =1,03, APTT =29,4 sec, Sodium =134,0 mEq/l, Potassium =4,39 mEq/l, Chlorde =97,1 mEq/l.

Bilateral fundus examination: bilateral optic cup excavated symmetrical, outlined, normally coloured, retinal vessels with normal aspect.

Lumbar puncture has been performed, obtaining a clear, hypertension cerebrospinal fluid with 83 elemente/mm3, 100% represented by lymphocytes, proteinorahie was 0.77 mg/dl, 61 mg/dl glicorahie, 113.2 mEq/L clorurorahie, on growth medium there was no development of germs.

There have been taken samples for TBE and Lyme disease serology-which were positive.

Hydroelectrolytic disturbance treatment has been initiated, cerebral depletion treatment was performed, antibiotics were administerd until obtaining the bacteriological examination, have been administered also steriodal antiinflamatory, proton pump inhibitors, symptomatic treatment; under treatment the evolution was favourable and rapid, the patient requested to be discharged on the fourth day of hospitalization.

After 2 days from discharge headaches, emesis reappear, the patient was brought back to the emergency room the next day, when suddenly aphasia and right hemi-body motor deficit was installed. At physical examination the patient shows a rapid alteration of general condition, cardiopulmonary between normal limits, hepatomegaly at 1cm, persistent neck

[1]Corresponding author: Victoria Bîrluţiu, Str. Lucian Blaga, Nr. 2A, Sibiu, 550169, România, E-mail: victoriabirlutiu@yahoo.com, Tel: +40269 212320
Article received on 06.04.2013 and accepted for publication on 29.07.2013
ACTA MEDICA TRANSILVANICA September 2013;2(3):270-271

stiffness, right diminished osteotendinous reflexes, right Babinski sign (+), mixed aphasia, right deficit motor.

Cranial CTscan was performed: cranial MDCT examination native and with iv contrast was performed, with contiguous sections that do not shows infra or supratentorial focused lesions. Median structures were in normal position. Asymmetrical and normotensive ventricular system. Vascular structures were more pericerebral dilated. Without hematic intracranial densities, without localized or diffused areas of edema without mass effect. Conclusions: pericerebral vascular hyperemia

Lumbar puncture was repeat obtaining clear, slighty hypertensive CSF with 9 elemente/mm3, proteinorahie 0.73 g/l, clorurorahie 115.6 mEq/L, glicorahie 87 mg/dL and no development of germs.

Other laboratory examinations: leukocytes: 10200-7960/mm^3, erythrocytes 5.35-4.56 mil/mm ^{3}, HGB =16.4g-13.6/dl, HCT=47.5-40.6%, MCV=88.8-89.0 fL, MHC=30.7-29.8 pg, MCHC=34.5-33.5g/dl, PLT= 198000-251000/mm ^{3}, NEU 43.4%, LYM 46.1%,MONO=8.7%, BASO 0.3%, EOS1.5%, glucose=7-992mg/dl, BUN(Blood Urea Nitrogen) 26-16mg/dl, creatinine 0.72-067 mg / dL, ESR 55mm/h, fibrinogen 411.8-478.7 mg/l, CPK 89U/l, SGOT 16-52U/l, SGPT 40-133U/l, Bilirubin(total)0.37mg/dl, amylase 46U/l Sodium =135,6 mEq/l, Potassium =4,13 mEq/l, Chlorde =96,5 mEq/l.

Urinalysis (UA): density 1015, LEU25/ul LEU, KET 5 mg/dl, sediment: rare leukocyte, frequent flat epithelial cells, rare crystals of calcium oxalate.

Abdominal ultrasound: liver, gall bladder, kidney, pancreas, spleen between normal limits, no fluid collection in the peritoneal cavity.

Under antibiotic therapy with ampicillin 8g/day+ ceftriaxone 4g/zi, dexamethasone, cerebral depletion treatment, antifungal therapy, PPIs, symptomatic treatment, aphasia and the motor deficit improves in the next 3 days after admission, at the end of the first week of hospitalization the patient became febrile with rare and irritating cough, in parallel with the development of fluid type bilateral basal dullness and evolving crackles rales disseminated in both lung fields.

Pulmonary radiography initially shows the clouding of the costodiaphragmatic sinus then on left lower lobe localized in the posterior and lateral segment opacities with fine drawings of air bronchogram on the profile image, imprecisely defined, inomogen "padded" looking with medium intensity, more obvious on oblique incidence (subsegmentar condensation process). Right perihilar opacity imprecisely defined with the same characteristics. Bilaterally emphasized peribronhovascular interstice and levelled up heart and prominent left middle heart arch (see figures no. 1, 2).

Figure no. 1. Chest radiograph with bilateral infiltrates

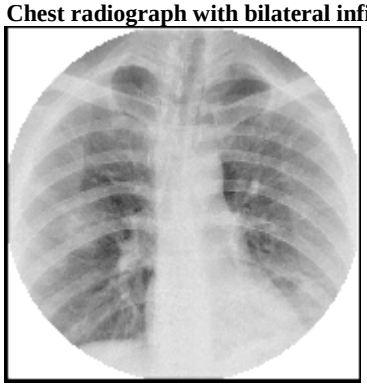

Figure no. 2. Chest radiograph clouding of the left costodiaphragmatic sinus

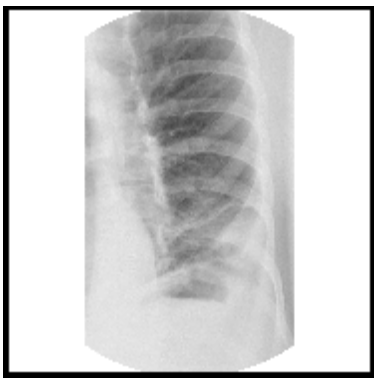

Blood cultures collected and bacteriological examination of sputum was sterile. The antibiotic therapy was escalated associating meropenem with vancomycin, iv antifungal therapy becoming afebrile and imagistic improvemt, the patient was discharged after 23 days of hospitalization

The serological results and CSF examination confirmed the presence of IgM antibodies for TBE and from serum analyze pozitiv IgM for B burgdorferi.

DISCUSSIONS

The biphasic evolution type of our case was suggestive for TBE considering the ocupational risk of exposure. Surprising was the concomitance of borreliosis at this patient that was probably responsible for the biological changes-thrombocytopenia, hepatocytolisis syndrome; we can not sustain the possible involvement in impairment meningocerebral in the absence of examining the CSF for B. Burgdorferi for which the therapeutic attitude (antibiotic therapy) was beneficial. The occurrence of bronchopneumonia as the cardiac involvement are described in the literature for the association with TBE.(2) In our case, the improvement after association of vancomycin suggested a staphylococcal etiology, without having any bacteriological evidence

The patient did not return to his check up, his health condition is good, he did not consider to be necessary the reassess.

REFERENCES

1. Amato-Gauci AJ, Zeller H. Tick-borne encephalitis joins the diseases under surveillance in the European Union, Eurosurveillance. 2012;17(42).
2. Mandell G, Bennet J, Dolin-Mandell R. Douglas and Bennett's Principles and Practice of Infectious Diseases, seventh edition. 2010;2:2147-49.