

CLINICAL CASE OF A TRANSTHORACIC APPROACH USING BOȚIANU'S PROCEDURE IN THE TREATMENT OF HIATAL HERNIA

TIMUR HOGEA¹, OANA LUCACIU², ALEXANDRU MIHAIL BOȚIANU³, PETRE VLAH-HOREA BOȚIANU⁴

^{1,2,3,4}University of Medicine and Pharmacy Tîrgu-Mureș

Keywords: hiatal hernia, 8 stitches, gastroesophageal reflux disease (GERD), gastric volvulus

Abstract: Surgical management of hiatal hernias and complex gastroesophageal reflux disease (GERD) requires a tension free repair with reliable reflux control. The authors would like to emphasize their own technique patented by Professor Boțianu, performed through a left thoracophrenotomy. Through this simple and quick technique and without using a synthetic mesh thus avoiding rejection, the whole ensemble is fixed under the diaphragm.

Cuvinte cheie: hernie hiatală, 8 fire, boala de reflux gastro-esofagian, volvulus gastric

Rezumat: Managementul chirurgical al herniilor hiatale și a refluxului gastroesofagian necesită o corecție fără tensiune cu un control adecvat al bolii de reflux. Autorii își prezintă propria tehnică operatorie patentată de profesorul Boțianu, ce folosește ca și cale de abord toracofrenotomia stângă. Prin această tehnică simplă și rapidă, fără a folosi material protetic, evitând astfel respingerea grefei, întreg ansamblul este fixat sub cupola diafragmatică.

INTRODUCTION

A hiatal hernia is a defect in the anatomy of the gastroesophageal junction, thus structures which are normally confined within the abdomen move through the hiatal orifice in the thorax.(1) A hiatal hernia is often associated with gastroesophageal reflux disease (GERD), but it can be present without it.(2,3,4,5) There are 4 types of hiatal hernias currently described, in our clinical case, the patient was diagnosed with type IV (a very large defect in the gastro-esophageal membrane through which the stomach, but also other viscera may migrate to the mediastinum).(6,7) In our clinical case, the greater omentum, the transverse colon and the whole stomach lied in the supradiaphragmatic position, from its rotation the stomach developing a volvulus.

Figure no. 1. Type 4 hiatal hernia (an upside-down stomach)



A hiatal hernia may be repaired either by an abdominal or a thoracic approach. The indications of the thoracic approach are: cases with severe lesions (which can be treated only through a direct intrathoracic exposure of the esophagus and the hiatal orifice); relapsed hiatal hernias; obese patients; a tight Szatzky ring (requires a wider releasing of the thoracic esophagus for properly descending it in the abdomen); massive and thoracic bonded hiatal hernias (require a larger dissection of the thoracic esophagus); patients undergoing

surgical procedures in the supra-mesocolic compartment.(8,9,10,11)

PURPOSE

The authors intend to emphasize their own technique invented by Professor Boțianu, which stands out by its simplicity and quickness.(12)

METHODS

We would like to present our patient, D.I. of 66 years old, (observational sheet: 16788/2012) diagnosed with ischemic cardiomyopathy, congestive heart failure, medium tricuspid insufficiency, medium secondary pulmonary hypertension, chronic obstructive bronchopulmonary disease, essential hypertension, permanent atrial fibrillation, chronic hepatitis of unknown cause and a heavy smoker, which reports an insidious onset of the current disease with dyspnea, unproductive cough and dysphagia accompanied by gastroesophageal reflux. In time, the symptoms got more severe with the development of a subocclusion syndrome, aggravation of dyspnea for which the patient is hospitalized in our clinic. Preoperative chest radiographs and barium meal show multiple supradiaphragmatic hydroaeric levels which are projected over the hearts shadow also occupying the retrocardiac space, suggesting a massive hiatal hernia with the migration of the stomach and of the transverse colon in the thoracic cavity.

Figure no. 2. Preoperative barium meal



¹Corresponding author: Timur Hogeia, Str. Gloriei, Nr. 14, Ap. 48, Tîrgu-Mureș, România, E-mail: hogeia.timur@yahoo.com, Tel: +0753 651861
Article received on 02.04.2013 and accepted for publication on 20.06.2013
ACTA MEDICA TRANSILVANICA September 2013;2(3):318-321

CLINICAL ASPECTS

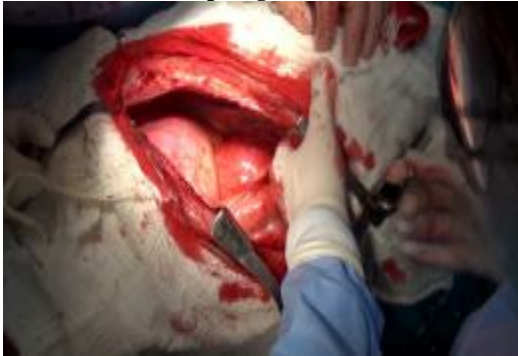Preoperative CT scan confirms the diagnostic with 175 mm maximum diameter of the herniary sac and a 131 mm vertical extension.

Preoperative gastroscopy shows the esogastric junction at 34 cm, multiple superficial erosions and a segmented volvulated stomach without being able to highlight the pylorus.

Being diagnosed with left intrathoracic giant hiatal hernia, intrathoracic gastric volvulus, intrathoracic transverse colon and greater omentum, the patient undergone surgery through a transthoracic approach using the „8 stitches” technique invented by Prof. Boțianu with the following surgical steps:

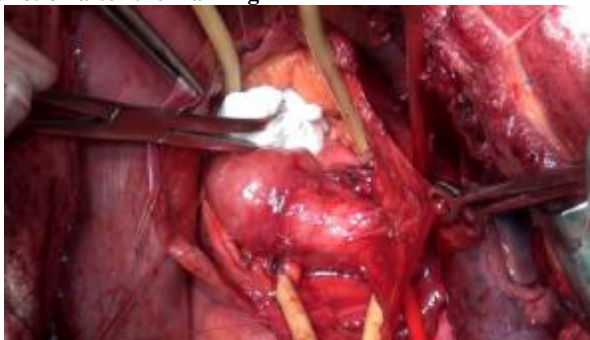- Low left posterolateral thoracotomy through the VII-th intercostal space. We found a generalized pachypleuritis which required a Fraser Gourd pulmonary decortication.
- We found a giant sectorial diaphragmatic relaxation which exceeds the left inferior pulmonary vein almost reaching the left superior pulmonary vein. The diameter of the relaxation measures 18x20 cm.

Figure no. 3. Massive diaphragmatic relaxation



- We performed a wide radial phrenotomy with the sparing of the phrenic nerve, thus exposing 2/3 of the volvulated stomach (caught in adhesions), the greater omentum and a loop of the transverse colon.
- With the help of a mesh, we protect the abdominal viscera, which herniated through the sectioned diaphragm. From this point on, the anesthetist must ensure a maximal relaxation for the next surgical steps to be performed in maximum security.
- We progressively dissect the inferior esophagus, the gastroesophageal junction and the posterior part of the stomach and we mark them separately with Fouchet probes.

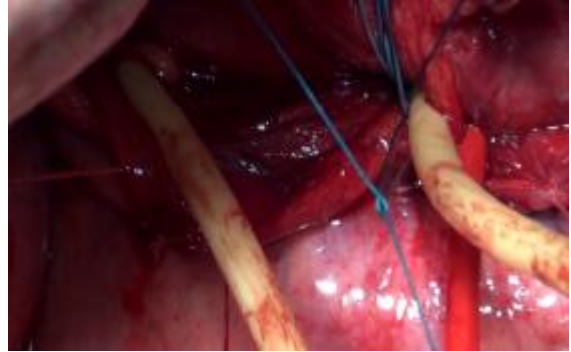Figure no. 4. Great visibility of the gastroesophageal junction after the marking



- Retroesophageal loading of the left and right diaphragmatic poles using the 4 stitches.

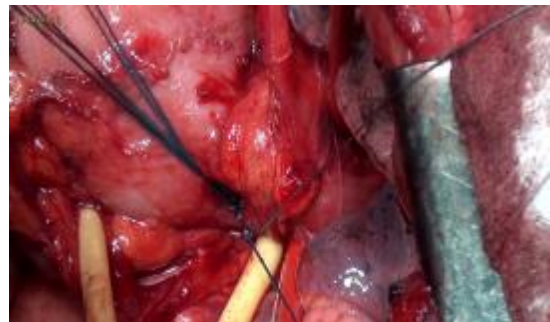
- Retroesophageal ligation of the 4 stitches that were passed through the left and right diaphragmatic poles. After this first ligation we obtained the recalibration of the hiatal orifice. The stitches are marked separately.

Figure no. 5. The first ligation of the 4 stitches and the reconstruction of the hiatal orifice



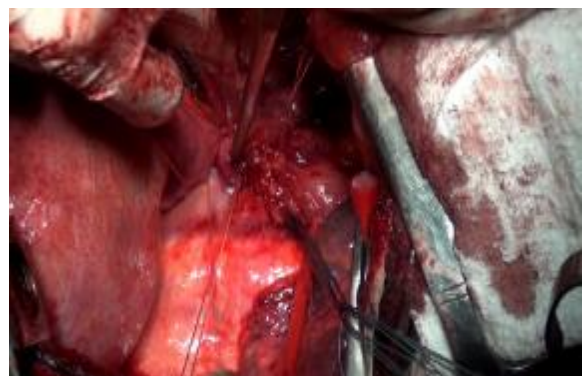
- Passing the same 4 stitches through the left esophageal border and through the right border of the gastric fornix.
- The devolvulated stomach, the inferior esophagus and the transverse colon are repositioned in the abdomen.
- The second ligation of the 4 stitches thus restoring the His angle and the subdiaphragmatic fixation of the hole ensemble.

Figure no. 6. The stomach is carefully examined to avoid another volvulus



- A 5 layer phrenoplication also invented by Prof. Boțianu using „U” stitches under the mechanical protection of the abdominal viscera. The stitches are ligated in the reverse order in which they were inserted.(13)

Figure no. 7. The subdiaphragmatic ensemble is carefully protected



CLINICAL ASPECTS

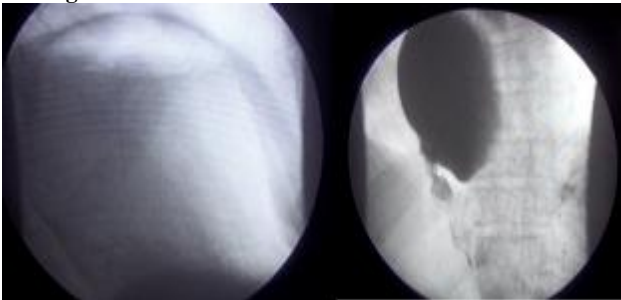
- Above the phrenoplication line the anterior and posterior flaps previously obtained are reinforced with „U” stitches. Even if the first layer of stitches fails this second layer maintains the subdiaphragmatic position of the entire ensemble.
- The two flaps are laid medial, crossed between them and ligated both between them and the diaphragm, thus obtaining in the middle of the diaphragm (the peak mechanical stress point), a 5 layer diaphragmatic reinforcement.
- Standard Mathey Evrest thoracic drainage.
- Closure of the thoracic wall in anatomical plans.

RESULTS

Immediate postoperative chest radiographs showed a full reexpansion of the lungs with the stomach and the transverse colon located completely in the abdominal cavity.

Postoperative course was difficult with the persistence of nausea, dysphagia and vomiting. The barium meal showed a relaxed gastric volvulus. Under these circumstances, a second intervention was necessary, this time through an abdominal approach, but was postponed due to the associated cardiovascular pathology.

Figure no. 8. Postoperative barium meal - the whole ensemble is located under the diaphragm and the recurrence of the gastric volvulus



DISCUSSIONS

There are many surgical procedures known today, which are used in the treatment of hiatal hernias that allow a tension free repair with reliable reflux control. It requires a good relaxation to be achieved by the anaesthetist and as a drawback, if a gastric volvulus is still present after the first intervention a second surgical procedure is required through an abdominal approach this time, which can be performed in the same day or in a different session.

We emphasize our own technique patented by Prof. Boțianu, which in our opinion has the following advantages:

- Through the thoracic approach, we obtained a perfect exposure of the lesion.
- Uses a wide radial phrenotomy, thus providing maximum security of the abdominal viscera.
- Using horizontal „U” stitches, we obtained a firm grip to the diaphragmatic tissue.
- We obtained a 5 layer diaphragmatic reinforcement at his peak mechanical stress point.
- The reinforcement is not obtained by using a synthetic material, thus avoiding the graft rejection.
- By using a wide radial phrenotomy the associated abdominal lesions can be easily resolved (in our case, the gastropexy for the gastric volvulus).
- Recurrence odds for another diaphragmatic relaxation are dramatically reduced by keeping the intact diaphragm to a minimum and as peripheral as it can.

- The novelty of Prof. Boțianu's procedure consists in using the same 4 stitches for the retroesophageal ligation of the two diaphragmatic poles and restoring the His angle through the ligation of the left esophageal border to the right border of the gastric fornix. By using this simple and quick technique, we recalibrated the His angle and stopped the gastroesophageal junction to slide above or under the diaphragm.

We also would like to mention the disadvantage of this procedure which consists in the failure of the gastropexy due to the abdominal adhesions, late diagnosis of the gastric volvulus, increased intraabdominal pressure. In this case, a second intervention is mandatory this time through an abdominal approach, which can be performed simultaneously using the same anesthesia or in another session. In the case of our patient where the abdominal approach could have been done simultaneously, the abdominal approach was postponed due to the associated pathology and the intraoperative risk assessment.

Another disadvantage consists in the involvement of two surgeons: a thoracic and a general one. This drawback disappears if the surgeon is both a general and a thoracic one.

CONCLUSIONS

Surgical management of hiatal hernias and complex gastroesophageal reflux disease requires a tension-free repair with reliable reflux.

For a general and thoracic surgeon, who is used to thoracotomies, the transthoracic approach offers optimal exposure, has lesser accidents, and if they happen, are easier to be repaired.

Those who apply the same principles regardless of approach –transthoracic or abdominal– such as good mobilization, hiatal reconstruction with buttressing, and tension free wraps with appropriate use of gastroplasty, have excellent results.

In this article, we presented a new method in the management of the hiatal hernia being aware of the other techniques available, underlying the fact that each individual surgeon has his personal preferences based on his skills and experience.

The authors emphasize their own technique through a thoracic approach, which uses the same 4 stitches for the recalibration of the diaphragmatic orifice and for the reconstruction of the His angle, fixing the whole ensemble under the diaphragm. The procedure is patented by Prof. Boțianu Alexandru, Discipline Surgery 4, University of Medicine and Pharmacy Țirgu-Mureș. The advantages of this procedure consist in the simplicity and the rapidity of the execution.

Acknowledgement:

This paper is partly supported by the Sectoral Operational Programme Human Resources Development (SOP HRD), financed from the European Social Fund and by the Romanian Government under the contract number POSDRU 80641.

REFERENCES

1. Sugarbaker DJ, Bueono R, Krasna MJ, Mentzer SJ, Zellos L. Adult chest surgery, NY, by the McGraw- Hill Companies, Inc., 2009, section IV, chapter 29.
2. Nebel OT, Fornes MF, Castell DO. Symptomatic gastroesophageal reflux: Incidence and precipitating factors, Am J Dig Dis. 1976;21:953-6.
3. Allison PR. Reflux esophagitis, sliding hernia and the anatomy of repair, Surg Gynecol Obst. 1951;92:419-431.

CLINICAL ASPECTS

4. Allison PR. The diaphragm. In Gibbon JH: The surgery of the chest, WB Saunders Company, Philadelphia. 1963. p. 280-282.
5. Cărpinișan C, Stan A. Patologia chirurgicală a toracelui, București, Ed. Medicală; 1971. p. 116-118.
6. Shields TW, LoCicero J, Ponn R,B, Rusch VW. General Thoracic Surgery 6th Edition, Lippincott Williams & Wilkins, 129:1675-1683.
7. Schwartz SI. Principles of Surgery, by the McGraw- Hill Companies, Inc.; 1997.
8. Horvat T. Tratat de chirurgie sub redacția Irinel Popescu, vol IV, Chirurgie Toracică, Ed. Academiei Române, București; 2008. p. 765-791.
9. Hinder RA. Surgical therapy for GERD: Selection of procedures, short- and long-term results. J Clin Gastroenterol. 2000;30:S48-50.
10. Barraya L, Chauvin P. Cure de la hernie hiatale avec suture des piliers en avant de l'oesophage, Ann Chir. 1971;25:1112:552-560.
11. Sabiston DC. Textbook of Surgery, WB Saunders Company, Philadelphia- London-Toronto; 1999. p. 791-832.
12. Boțianu A, Boțianu P, Ioniță A, Căreianu V, Baubec Gliga E. Procedeu pentru tratamentul chirurgical al herniei hiatale pe cale abdominală. Procedeu celor 8 fire, Jurnalul de Chirurgie Toracică. 1999;4(3):325-330.
13. Boțianu A. Procedeu pentru tratamentul chirurgical al relaxărilor și eventrațiilor diafragmatice, Jurnalul de Chirurgie Toracică. 1996;1(2):155-162.