PERIPROSTHETIC FRACTURES OF THE FEMUR COMPLICATING TOTAL HIP REPLACEMENT

TUDOR SORIN POP[1], ANCUȚA ZAZGYVA[2], SÁNDOR-GYÖRGY ZUH[3], ISTVÁN GERGELY[4]

[1,3,4]University of Medicine and Pharmacy Tîrgu Mureș, Clinic of Orthopaedics and Traumatology Tîrgu Mureș, [2]PhD candidate, University of Medicine and Pharmacy Tîrgu Mureș, Clinic of Orthopaedics and Traumatology Tîrgu Mureș

Keywords: *periprosthetic fracture, Vancouver classification, total hip replacement*

Abstract: *The increase in total hip replacement (THR) rates and rising life expectancy made periprosthetic femoral fractures after THR more common. In this study we evaluated the results of treating these types of fractures using the Vancouver group recommendations. We assessed a consecutive series of 39 periprosthetic femur fractures after THR (23 women, 16 men aged 66±7 years) treated by the same operative team between 2000 and 2009 and followed for a mean of 84 months (42-148). Fractures were classified according to the Vancouver system and treated non-operatively, with open reduction and internal fixation or with revision surgery. We obtained a 84.61% union rate with initial treatment that increased to 97.43% after the second procedure, with fracture union in the majority of cases with a stable implant and a 25.64% complication rate. Based on our results, we support the use of the Vancouver system as a treatment algorithm in these cases.*

Cuvinte cheie: *fracturi periprotetice, clasificarea Vancouver, artroplastia totală de șold*

Rezumat: *Creșterea numărului de artroplastii totale de șold (ATS) și a speranței de viață au condus la o creștere a frecvenței fracturilor periprotetice de femur. În acest studiu am evaluat rezultatele obținute după tratamentul acestor fracturi, utilizând recomandările grupului Vancouver. O serie consecutivă de 39 cazuri de fracturi periprotetice de femur după ATS (23 femei, 16 bărbați, vârsta medie 66±7 ani) tratate de aceeași echipă operatorie între 2000-2009, au fost urmărite în medie 84 de luni (42-148 luni). Fracturile au fost clasificate pe baza sistemului Vancouver și tratate prin metode ortopedice, reducere chirurgicală și osteosinteză sau prin revizia artroplastiei de șold. Am obținut o rată de consolidare de 84,61% după tratamentul inițial, respectiv 97,43% după a doua intervenție. Fracturile periprotetice cu un implant stabil au consolidat în majoritatea cazurilor. Rata complicațiilor a fost de 25,64%. Pe baza rezultatelor noastre susținem utilizarea sistemului Vancouver ca algoritm terapeutic în astfel de cazuri.*

INTRODUCTION

In a recent review, Schwarzkopf et al. listed some of the factors contributing to the increase in the frequency of periprosthetic fractures of the femur. They included the growing annual rate of total hip replacements (THRs) performed worldwide, the aging population, the growing number of patients living with a hip endoprosthesis in situ for more than 20 years, and the broader indications for THR, that now include younger patients.(1) The first periprosthetic fracture after THR was reported in 1954 – since then their incidence has constantly increased, currently being estimated at 4.1% and even higher after uncemented and revision THR.(2)

The management of periprosthetic fractures of the femurs is a difficult task that needs expertise in both revision and osseous trauma surgery. Treatment choice is influenced by fracture pattern and location, quality and quantity of bone stock, and the type and status of the prosthesis. Outcomes can also be affected by the patient's comorbidities. Still, regardless of the chosen treatment, there remains a high rate of postoperative complications.(3)

Different treatment algorithms and classification systems of periprosthetic femoral fractures after THR have been studied by many authors. A reliable and valid system, the Vancouver classification is now widely accepted. Besides information on fracture pattern, timing and location, and prosthesis stability, this system also takes into account the quality of the patient's osseous structure and the degree of bone loss.(4) When deciding on treatment, the most important factor is the stability of the femoral stem. Treatment options include non-operative management, open reduction with internal fixation using different types of osteosynthesis materials, and revision of the THR.

PURPOSE

In this study we aimed to assess a consecutive series of periprosthetic femoral fractures following THR that we treated according to the recommendations of the Vancouver group.

METHODS

Our study included 39 cases of periprosthetic fractures of the femur after THR treated in our clinic by the same operative team, between 2000 and 2009. Treatment method, complications and patient condition before and after surgery were recorded for all cases. Fracture characteristics, endoprosthesis stability, bone quality and osseous healing were evaluated using radiologic images. Patients follow up ranged from 42 to 148 months, with a mean of 84 months.

Fracture classification was done according to the Vancouver system, which was also the basis for choosing a treatment method from the following options: non-operative management, open reduction with internal fixation using

[1]Corresponding author: Ancuța Zazgyva, Str. Mihai Viteazul 31, Tîrgu-Mureș, România, E-mail: zazgyvaa@yahoo.com, Tel: +40745 612397
Article received on 27.11.2013 and accepted for publication 21.01.2014
ACTA MEDICA TRANSILVANICA March 2014;2(1):197-199

cerclage and/ or plates, with or without bone grafts, and revision surgery with an uncemented or cemented stem. On radiologic evaluation we determined femoral stem stability based on the criteria of Engh et al.(5) for the uncemented stems and the criteria of Harris et al.(6) in case of cemented stems.

RESULTS

The study included 23 female and 16 male patients. The average age at the time the fracture occurred was 66±7 years. Average time from THR to fracture was 67±9 months. The Vancouver classification of the fractures in the studied cases was as follows: 6 of type A, 18 of type B1, 12 of type B2 and 3 of type B3, with no type C fractures (figure no. 1).

Figure no. 1. Classification and treatment of the studied fractures (Vancouver system). ORIF – Open Reduction Internal Fixation

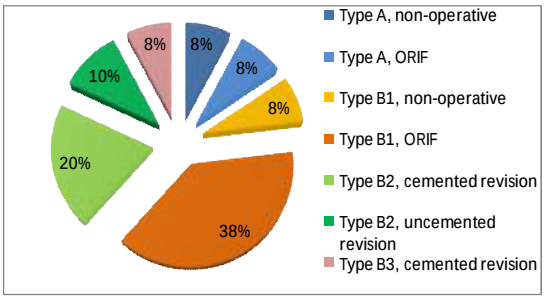

From the 6 cases of type A fractures, 3 were treated non-operatively and 3 by open reduction and internal fixation (ORIF), with trochanteric grip locking plate and cables (figure no. 2). All type A fractures united during follow up. Type B1 fractures were found in 18 patients – 8 with uncemented and 10 with cemented stems. Three of these cases were treated non-operatively and 15 with ORIF: cerclage cables in 8 cases (figure no. 3) and a plate device in 7 cases, with the use of structural and morselized allografts in 3 of the later. We noted fracture union after initial treatment in 15 patients (83.33%). The 3 failures – one in the non-operative group and two in the ORIF group – needed surgical intervention. We opted for plate fixation for these three cases, in two of which the use of structural and morselized allografts was mandatory. The grafts were stabilised with mesh and cables (figure no. 4). All fractures united without complications and had a stable component at the lastest follow-up. The type B2 group consisted of 12 patients (5 uncemented and 7 cemented stems), of which 8 underwent cemented revision and 4 were treated by revision of the femoral stem with an uncemented prosthesis, with supplementary cerclage fixation in all cases (figure no. 5). Primary treatment resulted in fracture union in 9 cases. From the rest of the three cases, two needed re-intervention using plate fixation and morselized bone grafts, while one patient had an established nonunion at the latest follow-up. Nine patients had stable implants at the latest follow-up and in three cases the femoral stem was loose (including the case of non-union). The 3 patients from the B3 type fracture group – two with uncemented stems and one with a cemented stem – were treated with cemented femoral stem revision. Morselized and structural bone grafts were used in one case. At the latest follow-up all 3 implants were considered stable. Primary intervention was successful in 33 cases (84.61%), and the success rate increased to 97.43% (38 cases) after the second intervention. We recorded a total of 10 complications associated with treatment (25.64%) – 6 in the B1 fracture group and 4 in cases of B2 type fracture. In the B1 fracture group there were 2 cases of deep venous thrombosis, 3 cases of hematoma and 1 case of soft-tissue infection. Type B2 fractures were complicated with 2 cases of dislocation of the endoprosthesis and 2 cases of hematoma.

Figure no. 2. A – Type A fracture of the greater trochanter, reduced and stabilised with trochanteric grip locking plate and cable. B – Displaced type A fracture, healed after stabilising with cerclage cables and crimp sleeves

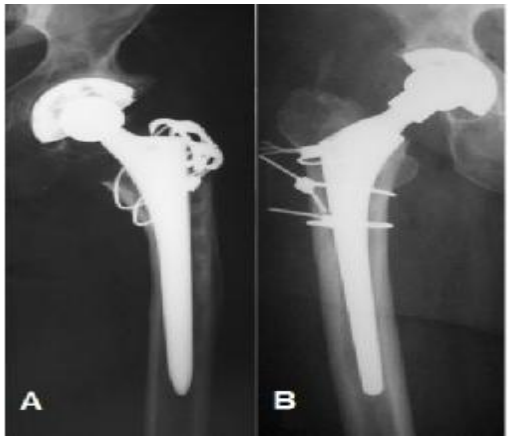

Figure no. 3. A – Displaced long oblique type B1 fracture. B – Fracture union after stabilisation with cables and crimp sleeves

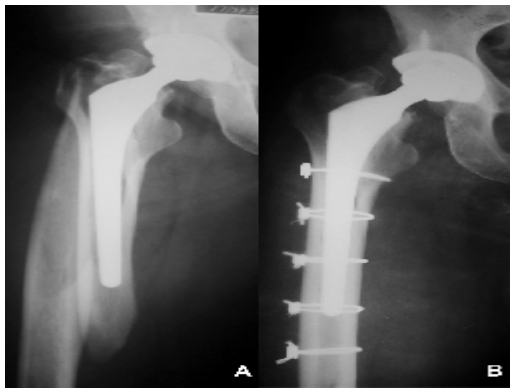

Figure no. 4. A – Comminuted type B1 fracture located at the tip of the femoral stem. Damage of the osteosynthesis materials after stabilisation with a plate and cerclage wires. B – Solid union at 3 years after re-operation using a plate and structural and morselized allografts, stabilized with mesh and cables

Figure no. 5. A – Type B2 fracture with a loose femoral stem. B – Reduction and stabilization with a cemented revision femoral component, trochanteric grip locking plate and cerclage cables

DISCUSSIONS

One of the most dreadful complications of THR, periprosthetic femoral fractures show a steadily increasing incidence, with estimates ranging from 0.1 to 2.1% for postoperative fractures and from 0.3 to 5.4% for intraoperative fractures. Higher rates are observed in cases of revision THR and uncemented THR.(1,7)

Although most of these cases can be treated by conservative measures, surgery remains the treatment of choice in cases with markedly displaced fragments or those associated with periprosthetic osteolysis.(8) Surgical treatment offers the benefits of early mobilisation and reduced systemic and local complications.(2)

The Vancouver classification system was developed by Duncan and Masri in 1995, and it is based on fracture location, implant stability and the state of the bone stock. It also offers a treatment algorithm that has been validated since, and is accepted and used worldwide.(9) This system divides periprosthetic fractures of the femur into 5 types: A, B1, B2, B3 and C. Non-operative treatment is indicated only in stable fractures, or in patients that are too frail for surgery.

Type A fractures are frequently associated with periprosthetic osteolysis and include those that involve the greater or lesser trochanter. These fractures are suitable for non-operative treatment if the endoprosthetic component is stable. Our group of type A fractures was managed either non-operatively (50%) or by ORIF, with good results that are in line with the ones reported in literature.(7,10,11)

Type B fractures are located around or just distal to the femoral stem. The subdivisions of type B fractures (B1, B2 and B3) are very important for decision making regarding management, because they refer to stem stability and bone stock.

A few selected cases of type B1 fractures can be manageable by non-operative means, but usually ORIF is necessary. Various plate devices and cerclage cables, either alone or combined with structural and morselized bone grafts can be used.(1) We obtained good results with these techniques, with only 3 failures – this highlights the still on-going debate regarding the differentiation of stable vs. unstable stems in type B fractures (B1 vs. B2).(2)

In type B2 fractures the femoral stem is unstable, thus revision artroplasty is the treatment of choice. In our cases we opted for supplementary cerclage fixation of fracture fragments, as recommended in the literature (1,2), with good results. Our relatively small subgroup of patients with B2 fractures did not permit a proper comparison of the use of cemented vs. uncemented stems.

Type B3 fractures are one of the most challenging fracture patterns, with a high rate of complications. In these cases it is essential to obtain adequate distal fixation of the implant in order to provide axial and rotational stability, because the proximal bone usually does not give a sufficient amount of support. Bone grafting is usually recommended in this type of fracture, but a recent study advocates treatment by revision artroplasty and internal fixation, without bone grafting.(12) We treated type B3 fractures by revision with a cemented femoral stem, using bone grafting in only one case out of the three.

CONCLUSIONS

We obtained results that demonstrate a good success rate in treating the majority of periprosthetic femur fractures. The Vancouver classification system provides an excellent treatment algorithm. Although our study included only a small number of subjects, by thoroughly analyzing our cases we can draw pertinent conclusions regarding each treatment method.

REFERENCES

1. Schwarzkopf R, Oni JK, Marwin SE: Total Hip Arthroplasty Periprosthetic Femoral Fractures - A Review of Classification and Current Treatment. Bulletin of the Hospital for Joint Diseases 2013;71(1):68-78.
2. Marsland D, Mears SC: A Review of Periprosthetic Femoral Fractures Associated With Total Hip Arthroplasty. Geriatr Orthop Surg Rehabil 2012;3(3):107-120.
3. Muller M, Kaab M, S. T, N.P. H, C. P. Periprosthetic femoral fractures: outcome after treatment with LISS internal fixation or stem replacement in 36 patients. Acta Orthop Belg 2009, 75:776-783.
4. Park SK, Kim YG, Kim SY: Treatment of Periprosthetic Femoral Fractures in Hip Arthroplasty. Clin Orthop Surg 2011;3(2):101-106.
5. Engh CA, Massin P, Suthers KE: Roentgenographic assessment of the biologic fixation of porous-surfaced femoral components. Clin Orthop 1990;257:107-128.
6. Harris WH, McCarthy JC, O'Neill DA: Femoral component loosening using contemporary techniques of femoral cement fixation. The Journal of bone and joint surgery American volume 1982;64(7):1063-1067.
7. Pop TS, Gergely I, Roman C, Nagy O: Periprosthetic femoral fractures after total hip arthroplasty. ASORIS 2011;4(24):53-60.
8. Rayan F, Haddad F: Periprosthetic femoral fractures in total hip arthroplasty - a review. Hip Int 2010;20(4):418-426.
9. Holley K, Zelken J, Padgett D, Chimento G, Yun A, Buly R: Periprosthetic Fractures of the Femur After Hip Arthroplasty: An Analysis of 99 Patients. HSSJ 2007;3:190-197.
10. Pritchett JW: Fracture of the greater trochanter after hip replacement. Clinical orthopaedics and related research 2001;390(Sept):221-226.
11. Hsieh PH, Chang YH, Lee PC, Shih CH: Periprosthetic fractures of the greater trochanter through osteolytic cysts with uncemented MicroStructured Omnifit prosthesis: retrospective analyses pf 23 fractures in 887 hips after 5-14 years. Acta orthopaedica 2005;76(4):538-543.
12. Wang JQ, Gao YS, Mei J, Rao ZT, Wang SQ: Revision hip arthroplasty as a treatment of Vancouver B3 periprosthetic femoral fractures without bone grafting. Indian J Orthop 2013;47(5):449-453.