STUDY OF THE MANDIBULAR CANAL IN TOTALLY EDENTULOUS PATIENTS - CLINICAL IMPLICATIONS

VICTOR TRĂISTARU[1], MIHAELA NIȚESCU[2], CAMELIA IONESCU[3], MIHAI DAVID[4], DANA CRISTINA BODNAR[5], TRAIAN BODNAR[6], CRISTIAN COMĂNESCU[7], MIHAI BURLIBAȘA[8]

[1,2,3,4,5, 6,7,8]*"Carol Davila" University of Medicine and Pharmacy București*

Keywords: *mandibular canal, total edentulous, neurovascular bundle*

Abstract: *The absence of effective preventive dental programme leads to a multiplication of patients with single or multi-tooth edentations. Clinical and technical difficulties for prosthetic treatments appear in totally edentulous patients due to sharp bone atrophy. Depending on the mandibular reorganisation due to age and edentation, mandibular canal presents calibre (it diminishes) and position changes (it approaches to the alveolar mandibular ridge) modifications. Prosthetic treatments with dental implants imply a series of local and regional contraindications. In the present article, we studied a number of 32 computerised topographies (CT), on which we could establish the cranio-caudal and vestibulo-oral position of the mandibular canal. The CT also presents the relation of the mental foramen with the edentulous ridge. The relation of the mandibular canal with the alveolar ridge presents a very important aspect for establishing the treatment plan for the patient. The clinical safe-zone must be established regarding the topography of the mandibular canal, in such way that neither the osteotomy, nor dental implant placement will harm in any way the integrity of the contents of the mandibular canal.*

Cuvinte cheie: *canal mandibular, edentație totală, mănunchi vasculo-nervos*

Rezumat: *Absența unor programe eficiente de prevenție dentară conduce către o înmulțire a pacienților cu edentații uni- sau pluri-dentare. La pacienții edentați total, apar dificultăți tehnice și clinice de protezare, datorită unei atrofii osoase accentuate. În funcție de restructurările mandibulare consecutive vârstei și edentației, canalul mandibular prezintă modificări de calibru (se reduce) și poziție (se apropie de marginea alveolară a mandibulei). Varianta protezării cu ajutorul implanturilor dentare a unor astfel de cazuri, suportă o serie de contraindicații de ordin loco-regional. Lucrarea de față a luat în studiu un număr de 32 de tomografii computerizate, pe baza cărora s-a putut stabili poziția atât în sens cranio-caudal, cât și în sens vestibulo-oral a canalului mandibular. De asemenea, tomografia computerizată prezintă și relația găurii mentoniere cu creasta edentată. Raportul canalului mandibular cu marginea alveolară a mandibulei, prezintă o importanță deosebită în stabilirea planului de tratament al pacientului. Zona de siguranță clinică trebuie stabilită în raport cu topografia canalului mandibular, astfel încât nici osteotomia și nici inserarea unui implant dentar, să nu lezeze în niciun fel integritatea pachetului vasculo-nervos alveolar inferior.*

INTRODUCTION

As noted, the mandibular canal presents a diameter of 3-4 mm. This canal has its origin at the mandibular foramen, at the level of the internal side of the mandibular ramus and it continues in the body of the mandible up to the median line, corresponding with mental symphysis. The trajectory of the canal is enveloped in trabecular bone and the walls are formed from cortical bone. This trajectory describes a superior concave curve and has a tendency to approach to the lateral face of the mandible. Inferior from the first premolar, the mandibular canal forks into mental canal (which opens on the external face of the mandibular body via the mental foramen - this canal is housing the mental neurovascular bundle) and into mandibular incisive canal (which continues the mandibular canal trajectory and is housing the incisive neurovascular bundle).(1)

For the oromaxillofacial practice the topographic, the relations between inferior teeth and mandibular canal are very important, but also the topography of the mandibular and mental foramens.(2) At the dentulous adult, the mental foramen, in cranio-caudal way, is situated at the half distance between alveolar extremity and the inferior extremity of the mandible. Seldom, it can be double, exceptional triple and it presents an oval shape in a vertical way.(2)

PURPOSE

Depending on the mandibular reorganisation due to age and edentation, mandibular canal presents caliber (it diminishes) and position (it aproaches to the alveolar mandibular ridge) modifications. Prosthetic treatments with dental implants imply a series of local and regional contraindications.

In the present article, we studied a number of 32 computerised tomographies (CT), on which we could establish the cranio-caudal and vestibulo-oral position of the mandibular canal. The CT presents also the relation of the mental foramen with the edentulous ridge. The relation of the mandibular canal with the alveolar ridge presents a very important aspect for establishing the treatment plan for the patient. The clinical safe-zone must be established regarding the topography of the mandibular canal, in such way that neither the osteotomy, nor dental implant placement will harm in any way the integrity of the contents of the mandibular canal.(3)

[1]Corresponding author: Mihai Burlibașa, Calea Plevnei, Nr. 19, Sector 5, București, România, E-mail: mburlibasa@gmail.com, Tel: +40723 472632
Article received on 19.06.2014 and accepted for publication on 20.08.2014
ACTA MEDICA TRANSILVANICA September 2014;2(3):294-297

METHODS

In the present study, we have a number of 32 patients, with ages between 64 and 85 years old. The patients have been clinical and imagistic investigated. From an imagistic point of view, the computerised tomography has been used. The equipment used in this study for achieving CT is KODAK, model 9000 3D. The software utilised for analysis the CT is i-CAT Vision.

All of the 32 patients have total edentulous mandibles, with or without prosthetic treatment. In the present study have been included only the patients with prosthetic treatment for at least 5 years. We analysed the raport of the mandibular canal with the alvolar margin, and we also located the mental foramen in a cranio-caudal way.

With the aid of the imagistic examination, we established the trajectory of the mandibular canal, the bone offer situated superior of this canal, the relation of the canal with the vestibular and lingual plates, but also the position of the mental foramen.(3)

The restant bone height has been measured in the area of the first and second molars. For establishing the areas where we will measure, we took in consideration the mezio-distal diameters of the mandibular teeth (table no. 1).(2)

Table no. 1. (after K. Hanihara)

Mandibular tooth	Average mezio-distal dimension (mm.)
IC (central incisior)	5,50
IL (lateral incisor)	6,04
C (canine)	6,93
PM1 (first premolar)	7,10
PM2 (second premolar)	7,30
M1 (first molar)	11,24
M2 (second molar)	10,83

The mental foramen position has been measured in a vertical way, towards the edentulous ridge.

RESULTS

The results obtained have been summarized, according to the following imagistic examinations and tables.

Figure no. 1. Patient I.F., 84 years old. Ortopantomographic x-ray view

Figure no. 2. Patient I.F., 84 years old. The topography of the left metal foramen on transversal cross-section

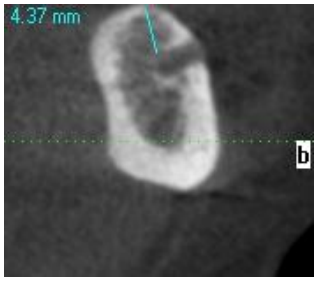

Figure no. 3. Patient I.F., 84 years old. The position of the mandibular canal in the area of the left first molar

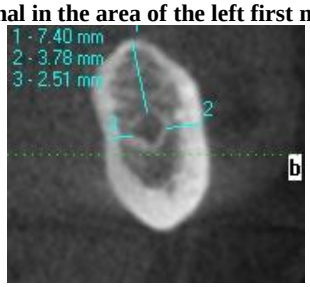

Figure no. 4. Patient I.F., 84 years old. The position of the mandibular canal in the area of the left second molar

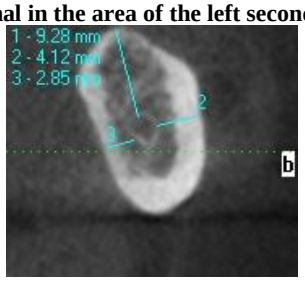

Figure no. 5. Patient I.F., 84 years old. The topography of the right mental foramen on transversal cross-section

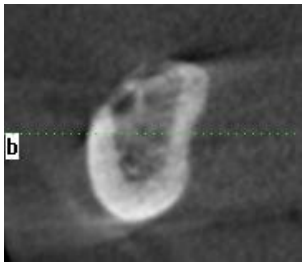

Figure no. 6. Patient I.F., 84 years old. The position of the mandibular canal in the area of the right first molar

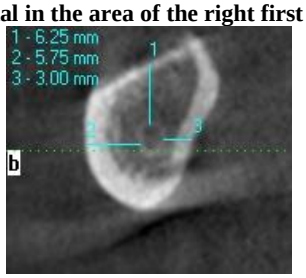

Figure no. 7. Patient I.F., 84 years old. The position of the mandibular canal in the area of the right second molar

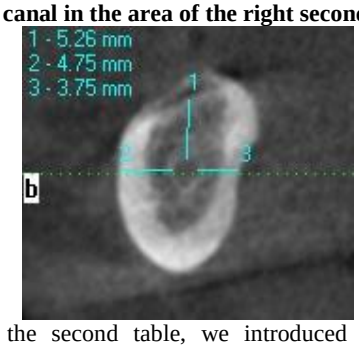

In the second table, we introduced measurements related to the bone height, bilateral, between the mandibular canal and the edentulous ridge at the level of the first and second molars. We introduced also data regarding the topography of the mental foramen in a vertical relation, with the remnant ridge.

Table no. 2. Bilateral bone heights between the mandibular canal and the edentulous ridge at the level of molars 1 and 2

	bone height M2 right	bone height M2 left..	bone height M1 right.	bone height M1 left.	bone height MF right	bone height MF left.
H.G./64/NP	5.26	9.28	6.25	7.42	3.02	4.37
F.I./64/P	7.32	6.76	7.88	7.03	5.10	4.82
R.T./65/P	11.32	10.41	7.38	8.55	6.28	5.50
G.E./65/NP	11.81	10.86	7.31	8.68	3.53	5.11
L.G./65/P	8.48	11.51	7.75	9.20	5.93	5.42
K.H./66/P	12.35	11.49	8.97	10.62	5.21	6.27
T.F./67/NP	7.37	11.39	8.36	9.51	4.97	6.48
O.V./67/NP	8.55	7.39	9.41	9.18	3.77	2.85
P.I./67/P	10.23	8.43	7.48	9.12	4.58	5.08
F.L./67/P	8.49	7.00	6.21	7.57	3.80	4.22
P.D./ 67/P	9.10	7.50	6.66	8.12	5.43	4.52
O.R./67/NP	8.29	6.83	6.06	7.39	3.71	4.11
T.L./68/P	12.48	11.18	9.04	8.75	4.18	3.68
J.O./70/P	10.36	9.28	7.50	7.26	3.47	3.05
R.P./73/P	11.00	9.86	7.97	7.71	3.69	3.24
L.D./73/P	9.29	7.65	6.79	8.28	4.16	4.61
A.T./74/NP	4.63	8.17	5.50	6.53	2.66	3.85
E.U./75/NP	7.47	6.15	5.46	6.66	4.05	3.71
P.R./76/P	11.41	9.40	8.34	10.17	5.11	5.66
F.S./76/P	6.05	10.67	7.19	8.53	3.47	5.03
E.P./78/NP	6.89	9.14	10.43	9.72	4.87	5.72
I.O./78/NP	6.26	11.04	7.44	8.81	2.88	5.20
E.I./78/P	8.59	7.08	6.28	7.66	5.14	4.27
P.R./79/P	10.73	9.61	7.77	7.53	3.59	3.16
J.O./80/NP	11.11	9.95	8.05	7.79	3.72	3.28
F.G./80/P	6.59	11.63	7.83	9.30	3.79	5.48
A.H./82/P	7.32	12.91	8.70	10.32	4.20	6.08
P.D./83/NP	5.04	8.58	5.91	6.94	3.07	4.26
T.N/83/NP	8.00	7.16	5.79	5.61	2.68	2.36
I.F./84/NP	5.26	9.28	6.25	7.40	1.02	4.37
I.G./84/P	10.88	9.76	7.92	7.68	5.33	4.65
P.M./85/P	6.26	10.88	7.40	8.74	5.43	5.24

P= with prosthetic treatment; NP= without prosthetic treatment

In the third table, we presented the data measured in the CTs of the patients with no prosthetic treatment. In the annex of the table no. 3, we summarised information regarding the minimal, maximal and the average measured values.

Table no. 3. Data measured in the patients with no prosthetic treatment

	bone height M2 right	bone height M2 left..	bone height M1 right.	bone height M1 left.	bone height MF right	bone height MF left.
H.G./64/NP	5.26	9.28	6.25	7.42	3.02	4.37
G.E./65/NP	11.81	10.86	7.31	8.68	3.53	5.11
T.F./67/NP	7.37	11.39	8.36	9.51	4.97	6.48
O.V./67/NP	8.55	7.39	9.41	9.18	3.77	2.85
O.R./67/NP	8.29	6.83	6.06	7.39	3.71	4.11
A.T./74/NP	4.63	8.17	5.50	6.53	2.66	3.85
E.U./75/NP	7.47	6.15	5.46	6.66	4.05	3.71
E.P./78/NP	6.89	9.14	10.43	9.72	4.87	5.72
I.O./78/NP	6.26	11.04	7.44	8.81	2.88	5.20
J.O./80/NP	11.11	9.95	8.05	7.79	3.72	3.28
P.D./83/NP	5.04	8.58	5.91	6.94	3.07	4.26
T.N/83/NP	8.00	7.16	5.79	5.61	2.68	2.36
I.F./84/NP	5.26	9.28	6.25	7.40	1.02	4.37

In table no. 5, we introduced measured values for the total edentulous patients, who present prosthetic treatments for at least 5 years. In the annex of table 4, we summarised information regarding the minimal, maximal and the average measured values.

Table no. 4. Minimum, average and maximum values of the measurements

MINIMUM	4.63	6.15	5.46	5.61	1.02	2.36
AVERAGE	7.38	8.86	7.09	7.82	3.38	4.28
MAXIMUM	11.81	11.39	10.43	9.72	4.97	6.48

Table no. 5. Values measured in the totally edentulous patients, who present prosthetic treatments for at least 5 years

	bone height M2 right	bone height M2 left..	bone height M1 right.	bone height M1 left.	bone height MF right	bone height MF left.
F.I./64/P	7.32	6.76	7.88	7.03	5.10	4.82
R.T./65/P	11.32	10.41	7.38	8.55	6.28	5.50
L.G./65/P	8.48	11.51	7.75	9.20	5.93	5.42
K.H./66/P	12.35	11.49	8.97	10.62	5.21	6.27
P.I./67/P	10.23	8.43	7.48	9.12	4.58	5.08
F.L./67/P	8.49	7.00	6.21	7.57	3.80	4.22
P.D./67/P	9.10	7.50	6.66	8.12	5.43	4.52
T.L./68/P	12.48	11.18	9.04	8.75	4.18	3.68
J.O./70/P	10.36	9.28	7.50	7.26	3.47	3.05
R.P./73/P	11.00	9.86	7.97	7.71	3.69	3.24
L.D./73/P	9.29	7.65	6.79	8.28	4.16	4.61
P.R./76/P	11.41	9.40	8.34	10.17	5.11	5.66
F.S./76/P	6.05	10.67	7.19	8.53	3.47	5.03
E.I./78/P	8.59	7.08	6.28	7.66	5.14	4.27
P.R./79/P	10.73	9.61	7.77	7.53	3.59	3.16
F.G./80/P	6.59	11.63	7.83	9.30	3.79	5.48
A.H./82/P	7.32	12.91	8.70	10.32	4.20	6.08
I.G./84/P	10.88	9.76	7.92	7.68	5.33	4.65
P.M./85/P	6.26	10.88	7.40	8.74	5.43	5.24

Table no. 6. Minimum, average and maximum values of measurements

MINIMUM	6.05	6.76	6.21	7.03	3.47	3.05
AVERAGE	9.38	9.63	7.64	8.53	4.63	4.74
MAXIMUM	12.48	12.91	9.04	10.62	6.28	6.27

In table no. 7, we calculated the index of vertical bone offer (IOVO). This index represents the difference, expressed in percentage, between the minimal, maximal and average calculated values for the total edentulous patients with prosthetic treatments and the same values, for the patients with no prosthetic treatments.

Table no. 7. Index of vertical bone offer (IOOV)

	IOOV (P-NP) M2 right	IOOV (P-NP) M2 left	IOOV (P-NP) M1 right	IOOV (P-NP) M1 left	IOOV (P-NP) GM right	IOOV (P-NP) GM left
MINIMUM	23.47	9.02	12.08	20.20	70.61	22.62
AVERAGE	21.32	8.00	7.20	8.32	27.00	9.70
MAXIMUM	5.37	11.77	-15.38	8.47	20.86	-3.35

CONCLUSIONS

After analysing and measuring the group of the 32 patients, we can observe more favourable values, for the remnant bone volume in the case of the total edentulous patients with prosthetic treatment for at least 5 years. This tendency can be observed at the level of the first and second molars, but also at the level of the mental foramen. In comparison of the two groups - patients with and without prosthetic treatments - the highest value regarding the difference (percentage) of the vertical bone offer, we can find at the level of the right mental foramen - 70.61%, in favour for the patients with prosthetic treatment. The lowest value (in percentage), by comparing the two groups, is 5.37 % in favour for the patients with prosthetic

treatment at the level of the right second molar. At the level of the left first molar and the mental foramen, there is a vertical bone offer more favourable in the cases of the patients with no prosthetic treatment.

REFERENCES

1. Nimigean V. Anatomie clinică şi topgrafică a capului şi gâtului, Ed. Universitară Carol Davila, Bucureşti; 2008.
2. Amorim MM, Borini CB, Lopes SL, Haiter-Neto F, Caria PHF. Morphological description of mandibular canal in panoramic radiographs of Brazilian subjects: Association between anatomic characteristic and clinical procedures. Int J Morphol 2009;27(4):1243-1248.
3. Güler AU, Sumer M, Sumer P, Biçer I. The evaluation of vertical heights of maxillary and mandibular bones and the location of anatomic landmarks in panoramic radiographs of edentulous patients for implant dentistry, J Oral Rehabil 2005;32(10):741-6.