

THERAPEUTIC CONDUCT IN SUPERPOSED CONVEXITAL CHRONIC SUBDURAL HEMATOMA

VICENȚIU SĂCELEANU¹¹County Clinical Emergency Hospital Sibiu

Keywords: chronic subdural hematoma, head trauma

Abstract: Subdural hematoma is a blood collection encapsulated at skull level, found in the subdural space between the dura mater and the arachnoid, being the result of minor, neglected TBI clinically manifested at more than three weeks after the trauma, generally in older patients, usually located at frontal and parietal level. The source consists of a cortico-dural vein rupture due to trauma, these veins being under tension due to the preexisting cortical atrophy; blood accumulates in the subdural space, is encapsulated, the increase being produced by hyperosmosis and by the successive break of other cortico-dural veins, while causing the hemolysis of blood collection.

Cuvinte cheie: hematom subdural cronic, traumatism crano-cerebral

Rezumat: Hematomul subdural este o colecție sanguină craniană care se găsește în spațiul subdural, între dura mater și arahnoidă, încapsulată, fiind urmarea unor TCC minore, neglijate, cu expresie clinică, la peste 3 săptămâni posttraumatic, în general la pacienți în vârstă, localizat de obicei la nivel frontal și parietal. Sursa constă în ruperea unei vene cortico-durale ca urmare a unui traumatism, aceste vene fiind în tensiune datorită atrofiei corticale preexistente; sângele se acumulează în spațiul subdural, se încapsulează, creșterea producându-se prin hiperosmoză și prin ruperea succesivă a altor vene cortico-durale, în timp producându-se hemoliza colecției sanguine.

INTRODUCTION

In the patients with chronic subdural hematoma, the clinical signs have a progressive evolution, occurring 2-3 weeks after the trauma onset. The clinical forms may be:

- oligosimptomatic – only one symptom occurs, the most frequent is the headache, progressive motor deficit, speech disorders, most often signalled by families.
- pseudo-tumoral – intracranial hypertension syndrome with progressive nature, associated with signs of progressive focal disease;
- pseudodemential - prevalent mental disorders, many patients reaching the psychiatric services with dementia;

Laboratory diagnosis is made by CT-scan, the appearance being of hypodense collection with a density similar to that of CSF, a biconvex lenticular appearance and a density higher than the CSF but lower than that of blood.

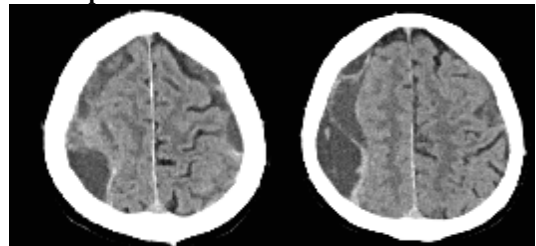
CASE REPORT

The patient, P.N.A, aged 48 years old, with hypertension and vascular and parenchymal decompensated untreated cirrhosis (2004), with multiple neglected head trauma is admitted to the neurosurgery department complaining about paresthesia and a slight motor deficit in the left upper limb, symptoms that occurred suddenly, following a head trauma from falling from the same level, four weeks ago. On the clinical examination, the patient is conscious, spatially and temporally oriented, balanced from the cardio-respiratory point of view, BP-125 / 70mmHg, AV-70 / min. Neurological examination on admission: GCS = 15 points (M6V5O4) without signs of intracranial hypertension, absent meningeal syndrome without evidence of cranial nerves damage, with particular attitudes, slight motor deficit in the left upper limb (MRC 4/5), walking

possible without help, without involuntary movements, good coordination, balance disorders - absent, hypoesthesia in the left upper limb, osteotendinous reflex – normal flexion without sphincter and autonomic disturbances, speech, praxis, gnosis - normal. Coagulation tests: prothrombin time (PT) = 17.7 s, prothrombin activity (%) = 50.5%, INR = 1.39.

Emergency cranial CT scan was performed which revealed the presence of large superposed chronic subdural hematoma at the right fronto-parietal level (figure no. 1).

Figure no. 1. Superposed chronic subdural hematoma at the right fronto-parietal level



Following clinical and laboratory investigations, on 05.14.2014, surgery was decided, practising a scalp linear incision in the right fronto-parietal region, scalping, minimal right parietal craniectomy with dura mater incision and suspension and the evacuation of the superposed chronic hematoma at fronto-parietal level through aspiration and abundant lavage, hemostasis. Postoperatively, the patient has a favourable evolution, with the remission of symptoms; but after 10 days of hospitalization, the patient experiences numbness again in the left upper limb, reason for which, on 5/22/2014, a MRI examination was performed, which highlighted the post

¹Corresponding author: Vicențiu Săceleanu, Str. Bălea, Nr. 1A, Ap. 33, Sc. C, Sibiu, România, E-mail: vicentiu.saceleanu@gmail.com, Tel: +40740 022931

Article received on 09.07.2014 and accepted for publication on 22.08.2014
ACTA MEDICA TRANSILVANICA December 2014;2(4):204-206

surgery control status, with fronto-parietal craniotomy and the presence of parietal subacute subdural hematic collections, bilaterally, superiorly, more pronounced on the right side, which also extended frontally, with areas of focal edema or mass effect (figures no. 2, 3).

For this reason, surgical intervention was decided on 23.5.2014, practicing right frontal craniotomy, evacuation of recurrent hematoma, haemostasis and suture of the wound. Postoperative status of the patient was favourable, with the remission of symptoms due to the effective surgical intervention and imaging measures quickly performed.

Figure no. 2. Recurrent right fronto-parietal subdural chronic hematoma

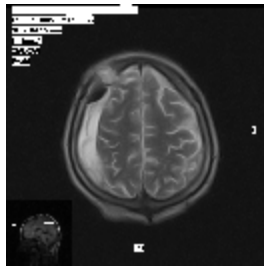
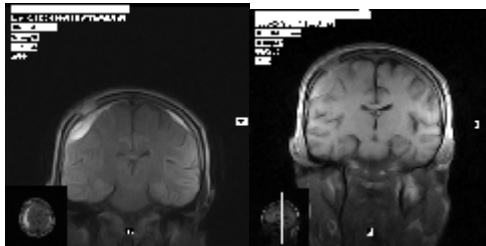
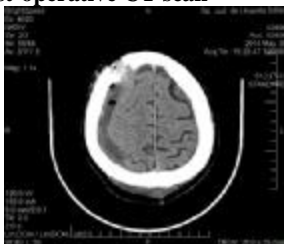

Figure no. 3. Recurrent right fronto-parietal subdural chronic hematoma



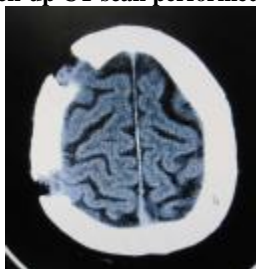
On 05/26/2014, another cranial CT scan was performed, which highlighted a small recurrent fronto-parietal postoperative hematoma, high, straight, with a maximum thickness of 1.3 cm, with a few pneumoencephalus bubbles included without mass effect (figure no. 4).

Figure no. 4. Post-operative CT scan



Cranial check-up CT scan made 30 days later highlighted the complete resorption of the recurrent subdural hematoma (figure no. 5).

Figure no. 5. Check-up CT scan performed 30 days later



DISCUSSIONS

Subdural chronic hematoma is slowly constituted over a period of several weeks, sometimes months, as a result of minor trauma that may go unnoticed. The source of the hemorrhage is the rupture of the veins afferent to the longitudinal sinus or cortical veins and rarely, the source of bleeding is a cortical artery. Most of the times, subdural hematoma is delimited by a fibrous capsule, which adheres to the brain tissue. Blood collection is sometimes stretched over the entire surface of the cerebral hemispheres. In the initial phase, hematoma content is represented by modified blood and in advanced stages, it takes a xanthochromic appearance. The symptoms, in case of chronic subdural hematoma, occur insidiously, the patients presenting headaches, gait or balance disorder, cognitive dysfunctions and memory loss, muscular weakness, confusion, aphasia. The most common signs are hemiparesis and asymmetric reflexes in the patients over 60 years old and in the younger patients, the most common symptom is headache.(1) The predisposing factors are generalized cerebral atrophy that brings about the increases of venous fragility associated with aging. So, older people are more likely to get a subdural chronic hematoma, especially due to minor trauma.(2,3)

The classic evolution takes three stages:

- initial trauma with concussion or minor brain contusion;
- a period of 3 weeks to 2-6 months follows with no symptoms or with minor symptoms (headache, dizziness, fatigue, vomiting, memory impairment);
- progressive clinical syndrome of cerebral distress due to the intervention of some favouring factors, such as: physical exercise, minor head trauma, alcoholism, sunburn, infections. During this period of time, the following are present: signs of intracranial hypertension (strong headache and resistant to treatment), neurological signs of localization.

Possible complications that may arise: permanent brain lesions, anxiety, confusion, difficulties in attention, dizziness, headache, memory loss, seizures. The patients with large hematomas may develop varying degrees of paralysis or coma. A chronic subdural hematoma may mimic a number of other diseases and cerebral disorders, including dementia, stroke, ischemic transient attack, encephalitis and brain lesions such as abscesses or tumours. The recovery after the brain injury varies widely, generally, 80-90% of patients have a significant improvement in the brain function after surgery. The prognosis of the patients with head injury correlates directly with the Glasgow Coma Scale on admission. The patients with a high score (13-15) evolve very well later. Sometimes, even after a minor trauma, symptoms such as: as dizziness and headache may persist, or cognitive problems, even for a period of one year after the trauma.(4,5)

Neurological evaluation is essential, aiming at the consciousness level, motor activity, eye opening, speech, photomotor reflex, signs of lateralization (hemiparesis/plegia).(6)

The treatment of a subdural chronic hematoma depends on the size and its growth rate. Some small subdural hematomas can reabsorbed or heal spontaneously (7), but in the case of large or symptomatic subdural hematoma, the neurosurgical intervention is required. The treatment of subdural hematoma is surgical and consists in evacuating the blood by trepanation with minimal bone resection (2/2 cm), followed or not by aspirative drainage.(8) The prognosis is very good, healing being achieved in 95% of cases, with the immediate remission of the focal signs.(9)

CONCLUSIONS

- Liver diseases with impact on coagulation are a major risk factor in the occurrence of chronic subdural hematoma.
- Cerebral CT scan is the investigation of choice in the TBI. MRI examination shows increased sensitivity as against CT scan for the detection of diffuse axonal injury, or late posttraumatic sequelae.
- The prompt diagnosis and the appropriate approach may result in a low mortality and good functional results.
- Postoperative neurological monitoring is mandatory, any sign that occurs or persists urges to performing a CT scan.
- Surgical intervention in cases of relapse is made in close correlation with the neurological status and imaging appearance.
- Recurrent subdural hematoma with sizes up to 1 cm, with or without neurological symptoms will not be operated.
- Periodical check-up by CT scan is required.

REFERENCES

1. Luxon LM, Harrison MJ. Chronic subdural haematoma. *Q J Med.* Jan 1979;48(189):43-53.
2. Traynelis VC. Chronic subdural haematoma in the elderly. *Clin Geriatr Med*1991;7:583-98. 9.
3. Adhiyaman V, Asghar M, Ganeshram KN, et al; Chronic subdural haematoma in the elderly. *Postgrad Med J.* 2002 Feb;78(916):71-5.
4. Stippler M. Trauma of the nervous system: craniocerebral trauma. In: Daroff RB, Fenichel GM, Jankovic J, Mazziotta JC, eds. *Bradley's Neurology in Clinical Practice.* 6th ed. Philadelphia, Pa: Saunders Elsevier; 2012:chap 50B
5. Biros MH, Heegaard WG. Head injury. In: Marx JA, ed. *Rosen's Emergency Medicine: Concepts and Clinical Practice.* 7th ed. Philadelphia, Pa: Mosby Elsevier; 2009:chap 38.
6. Ullman JS. Cerebrovascular pathophysiology and monitoring in the neurosurgical intensive care unit. In: Andrews BT. *Intensive Care in Neurosurgery.* New York: Thieme; 2003:29-46.
7. Naganuma H, Fukamachi A, Kawakami M, et al. Spontaneous resolution of chronic subdural hematomas. *Neurosurgery*1986;19:794-8. [Medline]
8. Brain Injury: Toward Understanding Manifestations and Treatment. *Archives of Internal Medicine* 158 (15):1617-1624. doi:10.1001/archinte.158.15.1617. PMID 9701095.
9. Săceleanu V. *Neurochirurgie Clinică*, Edit. ULBS, Sibiu; 2014.