

# HYDATID CYST WITH ATYPICAL LOCALIZATION. CASE REPORT

FLORIN MIHĂILEANU<sup>1</sup>, ALINA PINTEA<sup>2</sup>, AUREL MIRONIUC<sup>3</sup>

<sup>1,3</sup>“Iuliu Hațieganu” University of Medicine and Pharmacy, Cluj-Napoca, <sup>2</sup>“Lucian Blaga” University of Sibiu

**Keywords:** hydatid cyst, *E. Granulosus*, rare localization, neck

**Abstract:** Cystic echinococcosis remains a major health problem, especially in endemic countries. Although the pulmonary and hepatic localizations are most frequently involved, the hydatid cyst may also be identified at the level of other tissues. The primary hydatid cyst of the neck is of extremely rare occurrence even in endemic regions. We are presenting the case of a 68-year old woman with the primary localization of the hydatid cyst in the supraclavicular region, at the level of the right sternocleidomastoid muscle, where ideal cystectomy was performed, no postoperative complication or relapse being highlighted.

## INTRODUCTION

Hydatid disease is a parasitic disease determined by the infection with *Echinococcus granulosus*. The infection is endemic especially in the sheep breeding areas of the Middle East, South America, New Zealand, Australia, but also in our country especially in the rural areas. It seems that the disease affects almost 2-3 million of the world's population.(1)

The lifecycle of the parasite knows two hosts: a final one (canine) and an intermediary one represented by humans. The intermediary host is asymptomatic at the beginning, but the growth in dimensions of the larva and the emergence of the hydatid cyst at the level of the liver or of the lungs determines the emergence of the disease and sometimes even death.

Humans are infected by direct contact with the animal or by the ingestion of contaminated foods. The embryos penetrate the intestinal mucous membrane and reach the portal circulation. Due to their role of physiological capillary filter and due to the large volume of the blood capillaries, the liver and the lung are the most affected organs. Approximately 75% of the localizations of the hydatid cyst are at the level of the liver and 15% at the pulmonary level, 20% of the people infected having multiple localizations.(2,3) Crossing the capillary filters, the larvae can reach anywhere in the body borne by blood. According to the data from literature, in 15% of the situations, the localization is made at the level of the central nervous system, of the heart, of the spleen, of the uterus or of the bones (ribs, sternum, tibia).(4)

Muscle involvement is extremely rare (0.7-3%) (5,6,7) the development of the cyst taking place by direct inoculation or secondarily by metastatic dissemination from the visceral level. Literature describes muscle localizations more frequently at the level of the pectoral major, sartorius, biceps brachii, gracilis and biceps femoris muscles.

Hydatidosis presents itself clinically as a mass of tissue with slow growth, which requires a differential diagnosis with the tumours with this localization. It seems like the development rate of the cyst is of approximately 1-1.5 mm/month being influenced by the localization and by the adjacent anatomic structures.(8) The muscular hydatid cyst must be taken into discussion as differential diagnosis in patients with

muscle tumours coming from endemic areas.

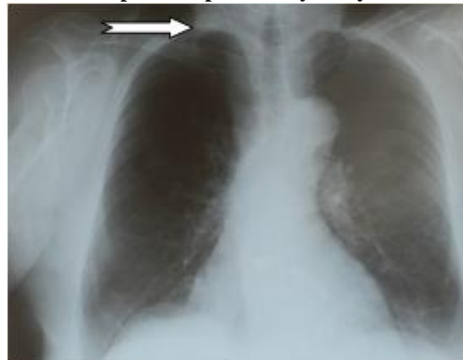## CASE REPORT

The patient, RS, aged 68, without past history of hydatid cyst comes to our clinic for a tumour formation localized on the right supraclavicular side, with a diameter of approximately 5 cm, fluctuant, mobile, well delimited, which has been growing progressively for the last 12 months. The patient has not presented subjective complaints, the reason for coming being the gradual growth in the size of the tumour. We insisted on the family and personal antecedents, on the possible contact with pets, but also on the heredo-collateral antecedents, without finding significant elements for diagnosis.

The pulmonary x-ray does not highlight any pulmonary evolutionary lesion, but it reveals circumscribed, homogeneous areas of densification of the soft tissues, on the right supraclavicular side (figure no. 1). The abdominal ultrasound does not highlight the existence of any space replacing formation at the level of the liver.

The soft tissues ultrasonography showed on the right laterocervical, supraclavicular side, a transonic image with its own wall of 23 cm<sup>3</sup> with cystic aspect, and posteriorly, suprascapular, another transonic image sharply delineated of 3 cm<sup>3</sup> (figure no. 2).

Figure no. 1. Preoperative pulmonary x-ray



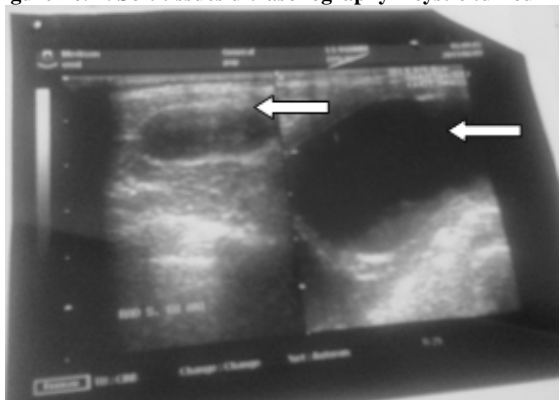
<sup>1</sup>Corresponding author: Florin Mihăileanu, Str. Clinicilor, Nr. 4-6, Cod 400006, Cluj-Napoca, România, E-mail: ms26rfl@yahoo.com, Phone: +40746 972386

Article received on 29.09.2015 and accepted for publication on 27.11.2015

ACTA MEDICA TRANSILVANICA December 2015;20(4):103-106

## CLINICAL ASPECTS

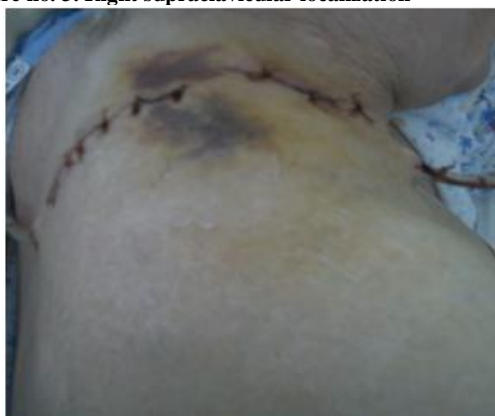**Figure no. 2. Soft tissues ultrasonography – cystic tumour**



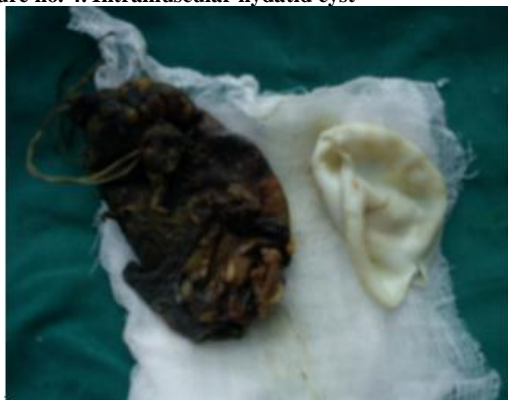The laboratory data were within normal limits and no eosinophilia was highlighted.

We intervened surgically under intravenous anesthesia making a right supraclavicular incision and an incision in the deltoid region. During surgery, we identified a multilobular formation of 10/15 cm, extended from the supraclavicular region until the deltoid region, in contact with the clavicle and the spine of the scapula, adherent to the left pleura. The diagnosis of multilocular hydatid cyst with daughter vesicles was established, and ideal cystectomy was practiced (figures no. 3, 4), lavage with hypertone saline solution and drainage of the remaining space. Postoperatively, the patient followed a drug treatment with Albendazol given in 3 cures (10mg/kg for 28 days), distanced at an interval of 2 weeks between each cure.

**Figure no. 3. Right supraclavicular localization**



**Figure no. 4. Intramuscular hydatid cyst**



## DISCUSSIONS

Infection with *E. Granulosus* remains a major health problem due to its localizations especially at the level of the liver and of the lung. The most frequent localizations of the cyst are liver (65.7%), lung (10.25%), peritoneum (8.18%), spleen (2.3%), kidneys (1.4%), subcutaneously (1.2%), retroperitoneal (0.51%), pancreas (0.50%), uterus and annexes (0.51%) and other localizations (0.13%).(9) Other studies speak of an incidence of 2.3% of the localizations in the soft tissues, only 24 cases out of 1 056 patients with hydatid cyst taken in study.(10) *E. Granulosus* determines the development of a chronic cystic lesion whose growth rate is of approximately 0.53 cm/year so that, if it is discovered in time, it can be easily removed surgically. The cyst wall is made of 3 layers. The external layer is represented by the pericyst which is the organ's or the tissue's own structure where the hydatid cyst is developing, being a result of the compression of the adjacent tissue secondary to the growth of the tumour. The middle layer is represented by the laminated membrane and the internal layer is represented by the germinal epithelium (endocyst). This is responsible for the production of scolices that represent the larval stage of the parasite.(11)

The clinical manifestations of patients with muscular hydatid cyst are totally unspecific so that most of the times the diagnosis cannot be established based on the symptoms.

The diagnosis of hydatidosis is established based on paraclinical explorations. Serological tests can be useful but do not have a 100% correspondence for the positive diagnosis, frequently giving false results, so that the only certain way to diagnose remains imagery (ultrasonography, computer tomography, MRI magnetic resonance) being the best option especially for the atypical localizations of hydatidosis. Ultrasonography establishes the diagnosis of certainty pursuing the presence of cystic calcifications, the presence of daughter vesicles or the detachment of the cystic membrane. Computer tomography brings extra data concerning the localization, the dimensions and the adjacency reports of the cyst.

The primary localization of hydatidosis at the muscular level is very rarely encountered, especially as it is necessary for the larva to cross the physiological barrier represented by the hepatic and pulmonary capillaries. To this, it is also added that at the muscular level, the growth in dimensions of the cyst is blocked by muscle contractility and the presence of lactic acid. It is important for patients with muscle hydatidosis to be evaluated imagistically for the exclusion of simultaneous hepatic or pulmonary localizations, the fact being known that in 20% of patients with hydatid disease, it may be multiple.

Unfortunately, in the case of muscular localization of the hydatid cyst, most of the times, the serology tests are negative (Casoni's test of provoked eosinophilia, the ELISA test for the identification of parasitic antigens, the cellular immunity tests).

Muscle hydatidosis being an extremely rare pathology, raises diagnosis difficulties. The preoperative evaluation of patients is mandatory to avoid the rupture, the infection or the recurrence of the hydatid cyst. The examination of choice remains ultrasonography, which most of the times describes particularities of the cystic wall, the presence of daughter vesicles or of hydatid sand – the "snow storm" sign, but sometimes, it cannot make the differential diagnosis with an abscess or other cystic tumours with this localization.

Gharbi describes 6 types of hydatid cysts:

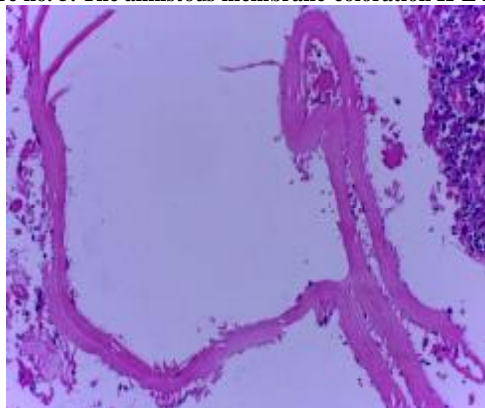- Type I is the cyst with uniform content, well delimited, in whose case the cyst wall cannot be visualized directly,
- Type II the cyst with small declive echoes, snowflake sign,

- with visible cyst wall,
- Type III with wheel like content with septa, determined by the presence of the daughter vesicles,
- Type IV with the emergence of a floating membrane determined by the discoloration of the proligerous membrane (waterlily sign),
- Type V with heterogeneous content, hyper and hypoeogenic characteristic for the cyst with abscess
- Type VI represented by the calcified, inactive hydatid cyst

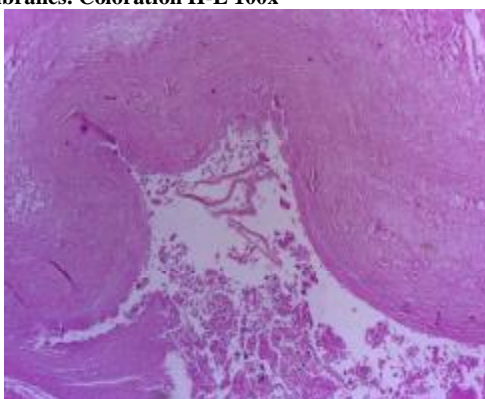
The treatment of the muscular hydatid cyst is surgical. Due to the risk of its intraoperative rupture with anaphylactic reaction and secondary hydatidosis, when the diagnosis is certainly established, the patients are given albendazol 10mg/kg for 28 days before surgery. In the case of multiple muscular localizations and in sickly patients, only a conservative drug treatment can come into question.

In the present case, as the certainty diagnosis was established during surgery, subsequently confirmed in the histopathological exam, the treatment consisted of the complete excision of the cyst with the irrigation of the surgical area with hypertone saline solution and subsequently, with antiseptic solutions (figures no. 5, 6). Postoperatively, the patient followed a treatment with Albendazol 3 cures (10mg/kg for 28 days), distanced at an interval of 2 weeks between each cure.

**Figure no. 5. The anhistous membrane-coloration H-E 200x**



**Figure no. 6. The conjunctive wall, cavity with anhistous membranes. Coloration H-E 100x**

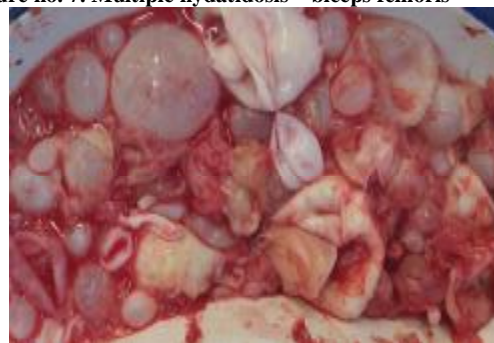


The cervical localization of the hydatid cyst is very rare. Ozekinci describes only 1 case out of 234 patients with hydatidosis described over a period of 5 years.(12,13,14)

Muscular hydatid disease can be confined at the level of any muscle of the body, the literature describing more frequently localizations of the pectoralis major, sartorius, biceps

brachii, gracilis and biceps femoris muscles (figure no. 7).

**Figure no. 7. Multiple hydatidosis – biceps femoris**



Kocakusak described a localization of the hydatid cyst at the level of the vastus lateralis muscle and Tatari, at the level of the supraspinatus muscle.(15,16)

The anatomic muscle characteristics, contractility and the presence of lactic acid are unfavourable for the growth of hydatid larvae, but the muscle volume and the rich vascularisation explain the confinement at the muscular level, in our case at the level of the sternocleidomastoid muscle.

Direct mortality due to echinococcosis is low (0.29-0.60%), the main complication of the disease being given by the relatively high relapse rate of up to 10%.(17)

In our case, the patient came with a right supraclavicular formation, asymptomatic, of elastic consistency, depressible, painless, and relatively mobile from the in depth plans, without local inflammatory signs.

Usually, muscular hydatidosis manifests itself as a primary tumour, without other localizations of the hydatid cyst being highlighted (over 90%). The confinement of the larva is carried out by blood, but the specialized literature also suggests the lymphatic dissemination route. Due to the local anatomical situation, the hydatid cyst may have several collateral expansions, the most affected muscular regions being represented by the torso muscles, the muscles of the lower limbs (40%), the muscles of the upper limbs (15%), of the head (5.33%) and of the neck (1.67%).(18)

The erroneous diagnosis of muscular hydatidosis is due to the fact that the lesions are in general clinically asymptomatic and mime benign or malignant tumours with muscular localization. The differential diagnosis is made with the hematoma, malignant tumours (liposarcoma), abscess or benign tumours.

The biopsy of these tumours is contraindicated as it may cause anaphylactic shock. Drug treatment is insufficient for the muscular hydatid cyst. The curative treatment is given by the ideal excision of the cyst. In case ideal cystectomy is not possible, the abundant irrigation of the area with hypertone saline solution shall be necessary and the large drainage of the area, as the perforation of the cyst may determine relapse in time.

## CONCLUSIONS

The preoperative diagnosis for muscular hydatidosis is frequently a difficult task due to the atypical localization of the disease, to the low incidence and because often it mimes a tumour with such a localization. Diagnostic suspicion must exist especially in patients coming from endemic areas or who have antecedents of hydatid cyst.

We have presented the rare case of a patient with primary localization of the hydatid cyst in the supraclavicular region, at the level of the sternocleidomastoid muscle. The

particularity of the case is given by the fact that the diagnosis was established during surgery, the evolution of the patient being favourable; 2 years postoperatively, no complications or relapse being highlighted (ultrasonography, pulmonary x-ray).

The best treatment for muscular hydatidosis remains surgical therapy followed by drug treatment with Albendazol.

The hydatid cyst may be confined anywhere in the body, no location being immune to the disease.

The atypical localizations of the hydatid cyst must be had in view when we diagnose pseudotumoral lesions with liquid content at the level of the muscles and in patients coming from endemic areas.

15. Kocakusak A, Koyuncu A, Arıkan S, Senturk O. Primary hydatid cyst of vastus lateralis muscle. *Acta Chir Belg.* 2004;104:471-2.
16. Tatari H, Baran O, Sanlidag T, Gore O, Ak D, Manisali M, et al. Primary intramuscular hydatidosis of supraspinatus muscle. *Arch Orthop Trauma Surg.* 2001;121:93-4.
17. Mercut D, Ianosi G, Resceanu A, Fronie S, Demetrian P, Nemeş E. Chistul hidatic. Forme rare de prezentare. *Chirurgia (Buc).* 2004;3 Mai-Iunie.
18. Unc OD, Steriu L, Iordache I, Kabtour B, Ples D, Călin I, Grasa C. Localizări rare ale chistului hidatic. *Prezentări de caz. Chirurgia.* 2010;105 (1):103-107.

## REFERENCES

1. Ito A, Urbani C, Jiamin Q, Vuitton DA, Dongchuan Q, Health DD, Craig PS, Zheng F, Schantz PM, Control of echinococcosis and cysticercosis: a public health challenge to international cooperation in China. *Acta Trop.* 2003;86:3-17.
2. Bouree P. Hydatidosis: dynamics of transmission. *World J Surg.* 2001;25:4-9.
3. Durakbasa MO, Kose O, Islam NC, Kilicoglu G. A primary hydatid cyst of the gracilis: a case report. *J Orthop Surg (Hong Kong).* 2007;15:118-20.
4. Jlidi R, Yaakoubi MT, Ladeb MF, Ben Ayeche ML, Ghannouchi G, Moula T. [Bone hydatidosis. 12 cases]. *Ann Pathol.* 1992;12(2):98-101.
5. Dahniya MH, Hanna RM, Ashebu S, Muhtaseb SA, el-Beltagi A, Badr S, el-Saghir E. The imaging appearances of hydatid disease at some unusual sites. *Br J Radiol.* 2001;74:283-289.
6. Tatari H, Baran O, Sanlidag T, Gore O, Ak D, Manisali M, et al. Primary intramuscular hydatidosis of supraspinatus muscle. *Arch Orthop Trauma Surg.* 2001;121:93-4.
7. Arazi M, Erikoglu M, Odev K, Memik R, Ozdemir M. Primary echinococcus infestation of the bone and muscles. *Clin Orthop Relat Res.* 2005;432:234-41.
8. Milicevic M, 2007. Echinococcal Cysts: Cause, Diagnosis, Complications, and Medical and Surgical Treatment. *Mastery of Surgery, Fischer JE, 5th Edition, Lippincott Williams & Wilkins; 2007. p. 1044-7.*
9. Ito A, Urbani C, Jiamin Q, Vuitton DA, Dongchuan Q, Health DD, Craig PS, Zheng F, Schantz PM, Control of echinococcosis and cysticercosis: a public health challenge to international cooperation in China. *Acta Trop.* 2003;86:3-17.
10. Muñoz Sánchez JA, Conthe Gutiérrez P, Arnalich Fernández F, Fernández A, García Seoane J, Ortiz Vázquez J, et al. The incidence of hydatidic disease in a general hospital. I. Epidemiological analysis of 1056 cases. *Med Clin (Barc).* 1982;78:421-6.
11. Beggs I. The radiology of hydatid disease. *AJR Am J Roentgenol.* 1985;145:639-648.
12. Ozekinci S, Bakir S, Mizrak B. Evaluation of Cystic Echinococcosis Cases Given a Histopathologic Diagnosis from 2002 to 2007 in Diyarbakir. *Türkiye Parazit Derg.* 2009;33:232-35.
13. Iynen I, Sogut O, Guldur ME, Kose R, Kaya H, Bozkus F. Primary hydatid cyst: An unusual cause of a mass in the supraclavicular region of the neck. *J Clin Med Res.* 2011;3:52-4.
14. Kesici U, Kesici S, Türkmen ÜA, Ulusoy H, Duman A, Burakgazi G, et al. Primary cyst hydatid in the neck; report of one case. *Türkiye Parazit Derg.* 2011;35:217-9.