EVOLUTION OF SURGICAL TECHNIQUES FOR CORRECTION OF LEFT VENTRICULAR ANEURYSM AFTER ACUTE MYOCARDIAL INFARCTION

RADU BĂLĂU[1], HORAŢIU SUCIU[2], KLARA BRÎNZANIUC[3], RADU DEAC[4], MIHAELA OPRIŞ[5], MARIUS HARPA[6]

[1,2,3,4,5,6]*University of Medicine and Pharmacy Tîrgu-Mureş, Institute for Cardiovascular Diseases and Transplantation Tîrgu-Mureş*

Keywords: *ventricular aneurysm, linear reconstruction, ventriculoplasty*

Abstract: *Evolution in the surgical treatment of left ventricular aneurysm post myocardial infarction resulted in considerable decrease of intra and postoperative mortality in these patients, but the optimal technique for correction remains questionable, each technique presenting advantages and disadvantages. The purpose of this study was to carry out a review of publications on left ventricular reconstruction techniques for left ventricular aneurysm after acute myocardial infarction, from the first attempts to currently used techniques.*

One of the most common sequelae of transmural myocardial infarction is the development of an aneurysm of the left ventricular wall. The most common location of the left ventricular aneurysm is the anterolateral wall of the left ventricle and the anterior portion of the septum, which is territory of the left anterior descending coronary artery. Less frequent is the posterior location of the left ventricular aneurysm caused by a dominant right coronary artery infarction associated with lesions of the circumflex artery.

Evolution in the surgical treatment of left ventricular aneurysm post myocardial infarction resulted in considerable decrease of intra and postoperative mortality in these patients, but the optimal technique for correction remains questionable, each technique presenting advantages and disadvantages.

The purpose of this study was to carry out a review of publications on left ventricular reconstruction techniques for left ventricular aneurysm after acute myocardial infarction, from the first attempts to currently used techniques.

First steps

The first step in the surgical treatment of left ventricular aneurysm was made by Beck, who in 1944 used "fascia lata" aponeurosis to strengthen the aneurysmal wall of the left ventricle, in an attempt to prevent excessive expansion and avoid aneurysm rupture.(1) This technique was palliative and was fairly quickly abandoned. In 1955, Likoff and Bailey suggested a more radical technique, doing a closed ventriculoplasty by applying a large lateral vascular clamp on the beating heart, right on the base of the left ventricular aneurysm, followed by aneurysm resection and suture of the edges of the remaining ventricular wall.(2) This type of procedure is the precursor of linear correction of left ventricular aneurysm.

The two techniques mentioned above represent pioneering attempts in this field. The techniques used later in surgical correction of left ventricular aneurysm can be classified into two categories: direct suture techniques and patch ventriculoplasty techniques.

Direct suture techniques

Development of extracorporeal circulation and cardiopulmonary bypass allowed first left ventricular aneurysm resection, followed by linear suture, first performed by Cooley in 1958. The surgery is performed through median sternotomy. Cardioplegic cardiac arrest is used especially if associated procedures are required, such as myocardial revascularization surgery or mitral valve procedure. In situations where left ventricular aneurysm resection is not accompanied by other procedures, cardioplegic arrest is not necessary and surgery can be performed on the beating or induced fibrillating heart, if the aortic valve is competent. This technique involves a linear incision in the aneurysmal territory at the front or rear wall of the left ventricle, parallel to the interventricular septum. The ventricular aneurysm is excised leaving in place a margin of about 1 cm of scar tissue to allow suture of the ventricular wall. Closing of the defect thus created is done in two layers.(3)

In aneurysms of the anterior wall, interventricular septum is almost always involved in the scar, causing a paradoxical movement of the septum, and thus affecting the left ventricle contractility. Resection and direct suture technique does not solve the problem, therefore, left ventricular functionality remains impaired by the paradoxical movement of the interventricular septum, so different techniques of septoplasty have been tried.

Two of the septoplasty techniques experimented by Cooley have become very popular: septal folding with separated stitches and reinforcing aneurysmal septum with a patch of Dacron (technique indicated especially in cases with extremely thinned ventricular septum, to prevent septal rupture).(4,5) In both cases, the dyskinetic septum is transformed into an akinetic one, with good immediate results, but this affects late results, akinetic septal area contributing to the worsening of congestive heart failure phenomena.

As a result of that finding, in 1973, Stoney proposed an amendment to the technique of resection and linear suture of anteroseptal aneurysms, which contains inclusion of septal scar into the correction procedure. After resection of aneurysmal wall, it is essential to examine the interventricular septum to identify the limit between the scar and the viable myocardium. The lateral edge of the excision area is sutured to the interventricular septal aneurysm in the transition area between the scar and the viable septum. The suture is armed with teflon

[2]Corresponding author: Horaţiu Suciu, Str. Gheorghe Marinescu, Nr. 50, Tîrgu-Mureş, România, E-mail: suciu.horatiu@umftgm.ro, Phone: +40744 701530
Article received on 03.12.2016 and accepted for publication on 03.01.2017
ACTA MEDICA TRANSILVANICA March 2017;22(1):34-36

strip into the ventricular free wall and wires are passed through the septum to the anterior wall of the right ventricle. The correction is completed with a second suture that connects the scar tissue located along the left anterior descending artery with viable myocardium of the side wall of the left ventricle.(6) This technique makes bypass to the left anterior descending artery impossible, because it is included in the suture line.

Another option for linear correction was introduced by Cabrol in 1974. This technique consists of cappitonage and exclusion of fibrous unresectable area, creating a new left ventricular cavity bordered only by contractile walls. Cappitonage is made with three layers of continuous suture. First, the deepest connects the free wall of the left ventricle to the interventricular septum in the border zone between the scar and the viable myocardium, the second layer connects the portion of ventricular free wall with the fibrous septum, and the third is shallow, epicardial.(7)

In 1984, Guilmet proposed the technique of septal exclusion, indicated in large aneurysms with septal involvement. This technique involves partial resection of the aneurysmal sac and exclusion of septal scar from the new ventricular cavity. Two layers of suture are applied, first connecting the left edge of the aneurysmectomy with the border zone of the septal scar, thereby excluding 2/3 of the septal dyskinesia. The second layer suture unites the right edge of the aneurysmectomy with the anterior left ventricular wall, providing hemostasis.(8)

Figure no. 1. Linear left ventricular aneurysm repair

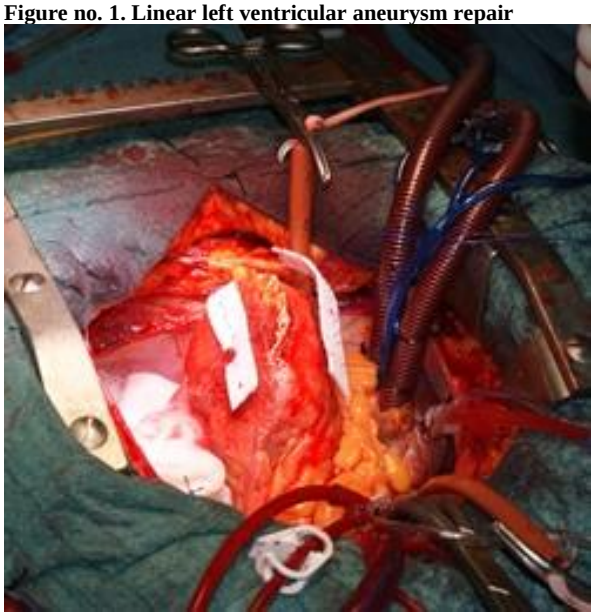

Patch ventriculoplasty techniques

In 1979, Levinsky described a technique of reconstruction of the left ventricle using a Dacron patch after resection of post myocardial infarction aneurysm. As a result of complications due to the fact that linear sutures were cutting into necrotic tissue, a wider resection up to the viable myocardium was needed. Since a 12/6 cm defect is impossible to close by direct suture, Levinski used a Dacron patch for its closure.(9) This technique is precursor of the current ventriculoplasty patch techniques.

In 1985, Jatene and Dor independently reported a new method, called anatomical reconstruction of the left ventricle with circular endoventricular reduction and closure by patch suture of the ventricular wall defect. The purpose of these methods was to recreate normal left ventricular geometry so that normal myocardial fibers have initial orientation.

In his technique, after ventriculotomy, aneurysm resection and thrombectomy of the left ventricular cavity, Jatene performed one or two purse string sutures at the junction between normal and fibrous myocardium. These sutures are tight, carefully reconstructing the left ventricular cavity and reducing its size. Afterwards, ventriculotomy closure is performed with or without patch. If ventricular cavity volume is close to the desired one, ventriculotomy is closed with isolated stitches reinforced with Teflon patches. In such cases, longitudinal suture length is significantly shorter than for conventional linear suture. When the defect resulted from anevrismectomy is large, double Dacron patch is used to close ventriculotomia. Endoventricular circular patch suture reduces patch surface and thus the akinetic area in the newly formed left ventricular cavity.(10)

In Dor's technique of circular endocavitary plasty, the procedure is performed under cardioplegic arrest. Ventriculotomy is performed in the dyskinetic area, the thrombus is removed, and if there are documented episodes of ventricular tachycardia, endocardic subtotal resection is performed. Cooley performs a circular endoventricular suture at 1 cm from the edge of viable myocardium to allow recreation of a normal shape of the left ventricle. A balloon is inserted into the left ventricular cavity and inflated to a theoretically diastolic volume of 50-70 ml/m², then circular suture is tightened and knotted. Subsequently, ventriculotomy is closed with a patch of appropriate size. Excluded scar tissue is sutured above, contributing to local hemostasis.(11,12,13,14)

Figure no. 2. Patch ventriculoplasty

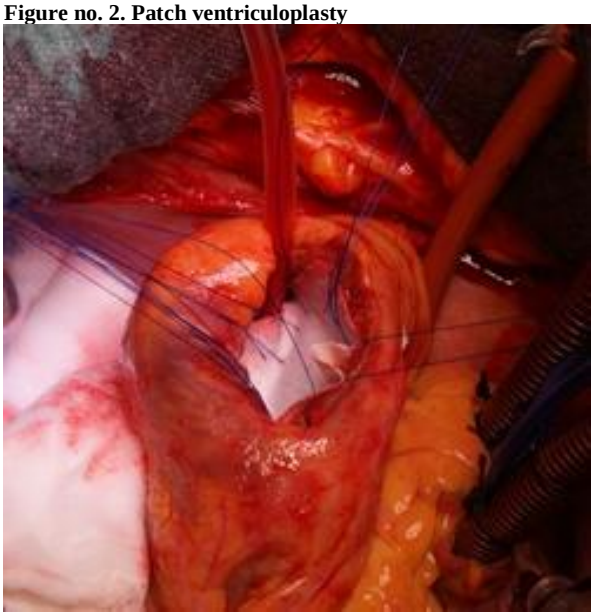

In 1989, Cooley promoted the ventricular endoanevrismoraphy technique as a modified version of patch reconstruction. The surgery is performed under conditions of continuous hypothermic cardioplegia. The apical aneurysm is opened through an incision parallel to the interventricular sulcus, avoiding left anterior descending artery. After left ventricular thrombectomy and identification of the border zone, defect size measurement is performed. An elliptical Dacron patch of appropriate size is used to close the defect, with the purpose of recreating normal ventricular shape, the scar tissue remaining outside. Ventriculotomy is closed above the patch, providing an additional hemostasis.(15,16)

The major advantage of ventricular patch plasty is recreation of the left ventricular geometry, eliminating paradoxical movement and reducing akinetic surface.

Complementary surgical procedures may be required on a case by case basis, associated myocardial revascularization being considered an almost indispensable procedure. Mitral valve repair procedures, closing a post infarct ventricular septal defect, and surgery of ventricular arrhythmias may be necessary in some cases.(17-23)

Conclusions

In conclusion, evolution of surgical techniques for correction of left ventricular aneurysm post myocardial infarction resulted in a significant decrease in mortality in patients with this type of pathology, but left open the discussion on the optimal technique used for each patient. Since all techniques have their advantages and disadvantages and due to anatomical and pathophysiological aspects of each case, most often the choice of a particular technique is up to the surgeon.

REFERENCES

1. Beck CS. Operation for aneurysm of the heart. Ann Surg. 1944;120:34.
2. Likoff W, Bailey CP. Ventriculoplasty: excision of myocardial aneurysm; report of a successful case. JAMA. 1955;158:915-920.
3. Cooley DA, Collins HA, Morris GC Jr, Chapman DW. Ventricular aneurysm after myocardial infarction: surgical excision with use of temporary cardiopulmonary bypass. JAMA. 1958;167:557-560.
4. Cooley DA, Walker W E Technique of ventricular septoplasty In: Moran JM, Michaelis LL, editors. Surgery for the complications of myocardial infarction. Grune & Stratton, Inc; 1980. p. 279.
5. Reddy SB, Cooley DA, Duncan JM, Norman JC. Left ventricular aneurysm: twenty-year surgical experience with 1572 patients at the Texas Heart Institute. Cardiovascular diseases. Bull Texas Heart Inst. 1981;8:165-186.
6. Stoney WS, Alford WC, Burrus GR, Thomas CS. Repair of anteroseptal ventricular aneurysm. Ann Thorac Surg. 1973;15:394-404.
7. Cabrol A, Guiraudon G, Laughlin L, Mattei S, Luciani J, Leon L, Renou J. Resection of left ventricular aneurysms and fibrous plaques. J Cardiovasc Surg. 1974;15:72-73.
8. Guilmet D, Popoff G, Dubois C, Tawil N, Bachet J, Goudot B, Guermonprez JL, Brodaty D, Schlumberger S. Nouvelle technique chirurgicale pour la cure des anévrysmes du ventricule gauche: l'anévrysmoplastie en paletot. Résultats préliminaires. 11 observations. Arch Mal Coeur Vaiss. 1984;77:953-958.
9. Levinsky L, Arani DT, Raza ST, Kohn R, Schimert G. Dacron patch enlargement of anterior wall of left ventricle after aneurysmectomy with concomitant infarctectomy. J Thorac Cardiovasc Surg. 1979;77:753-756.
10. Jatene A. Left ventricular aneurysmectomy. Resection or reconstruction. J Thorac Cardiovasc Surg. 1985;89:321-331.
11. Dor V, Kreitmann P, Jourdan J, Acar C, Saab M, Coste P, Viglione J. Interest of physiological closure (circumferential plasty on contractile areas) of left ventricle after resection and endocardectomy for aneurysm or akinetic zone comparison with classical technique about a series of 209 left ventricular resections. J Cardiovasc Surg. 1985;26:73. [abstract].
12. Dor V, Saab M, Coste P, Kornaszewska M, Montiglio F. Left ventricular aneurysm: a new surgical approach. J Thorac Cardiovasc Surg. 1989;37:11-19.
13. Dor V. Left ventricular aneurysms: the endoventricular circular patch plasty. Semin Thorac Cardiovasc Surg. 1997;9:123-130.
14. Dor V. The endoventricular circular patch plasty (Dor procedure) in ischemic akinetic dilated ventricles. Heart Failure Rev. 2001;6:187-193.
15. Cooley DA. Ventricular endoaneurysmorrhaphy: a simplified repair for extensive postinfarction aneurysm. J Cardiac Surg. 1989;4:200-205.
16. Cooley DA, Frazier OH, Duncan JM, Reul GJ, Krajce Z. Intracavitary repair of ventricular aneurysm and regional dyskinesia. Ann Surg. 1992;215:417-424.
17. Vicol C, Rupp G, Fischer S, Summer C, Dietrich Bolte H, Struck E. Linear repair versus ventricular reconstruction for treatment of left ventricular aneurysm: a 10-year experience. J Cardiovasc Surg (Torino). 1998;39:461-467.
18. Antunes PE, Silva R, de Oliveira JF, Antunes MJ. Left ventricular aneurysms:early and long-term results of two types of repair. Eur J CardiothoracSurg. 2005;27:210-5.
19. Lange R, Guenther T, Augustin N, Noebauer C,Wottke M, Busch R, Mayr N,Meisner H, Holper K. Absent long-term benefit of patch versus linear reconstruction in left ventricular aneurysm surgery. Ann Thorac Surg. 2005;80:537-42.
20. Minami K, Amin-Parsa MH, Reiss N, Schulte-Eistrup S, Coskun O, Koerfer R. Left ventricular aneurysmectomy, a 10-year experience in 269 patients. J Cardiovasc Surg. 2003;44(5 Suppl. 1):64 [abstract].
21. Tavakoli R, Bettex D, Weber A, Brunner H, Genoni M, Pretre R, Jenni R, Turina M. Repair of postinfarction dyskinetic LV aneurysm with either linear or patch technique. Eur J Cardiothorac Surg. 2002;22:129-34.
22. Lundblad R, Abdelnoor M, Svennevig JL. Surgery for left ventricular aneurysm: early and late survival after simple linear repair and endoventricular patch plasty. J Thorac Cardiovasc Surg. 2004;128:449-56.
23. Shapira OM, Davidoff R, Hilkert RJ, Aldea GS, Fitzgerald CA, Shemin RJ. Repair of left ventricular aneurysm: long-term results of linear repair versus endoaneurysmorrhaphy. Ann Thorac Surg. 1997;63:701-5.