# THE NEUROLOGIST'S RESPONSIBILITIES IN DECLARING THE TIME OF BRAIN DEATH AND ORGAN DONATION

**MIHAELA LUNGU[1], MARY NICOLETA LUPU[2], CARINA DOINA VOINESCU[3]**

*[1,2]Emergency Clinical Hospital Galați, [1,2,3]"Dunărea de Jos" University Galați*

***Keywords:*** *brain death, organ donor, the neurologist's role*

***Abstract:*** *Declaring brain death and identifying the potential organ donors requires the existence of a multidisciplinary team, but the neurologist has the responsibility of establishing the irreversibility of the brain damage. This responsibility, which is not a simple one, implies elements of medical ethics, but also emotional participation of the neurologist.*

Brain death is defined as a non-responsive status associated with abolition of all brain reflexes which represents the most severe grade of brain hypoxia, frequently determined by lack of circulation.(1)

The first definition of brain death was given in 1950, as being the state in which the brain is irreversibly damaged but heart and lung functions can be artificially maintained: exceeded coma.(2)

In 1968 Harvard Medical School introduces the concept of brain death as being the brain state non-responsive to any type of stimulus, stopping breathing and absence of electrical activity on electroencephalography (EEG) for 24 hours.(2)

The equating between brain death and the patient's death involved, in the years that followed, performing complex ethical and moral analysis with social, religious implication, the justification for this equivalence being given by the association of brain death with irreversible heart – respiratory insufficiency.(3)

The essential criteria for brain death's diagnosis include absence of all brain functions associated with the absence of vital functions that are under brain control, modifications being irreversible, in other words nonreactive coma, absence of brain stem reflexes and apnea.(4,5)

In declaring brain death it is absolutely mandatory for the determining cause of the irreversible brain damage to be known: subarachnoid hemorrhage, traumatic brain injury (6), cardiac arrest.(7,8) etc, imposing differential diagnosis with drug intoxications, anesthesia, hypothermia (body temperature over 32 degrees), vegetative status, "locked-in" syndrome, for which clinical tests and repeated laboratory analysis are required.(9)

Clinically the brain dead patient is in a profound coma, no spontaneous movements, without motor or verbal response to visual, cutaneous, auditory stimulus. Spinal reflexes of triple flexion may be present with or without the presence of the Babinski sign (its existence does not rule out brain death).(10) But there may be positions in flexion or extension which require timing of declaring this status. The eyeballs are in middle position, the pupils are nonreactive with sizes between 4-9 mm. Bulbar muscles are paralyzed, facial movements, coughing and swallowing reflexes, suction reflex, and corneal reflex being absent. There is no motor or autonomic response to noxious stimulus, there are no respiratory movements.(11)

Diagnosing the bulbar condition is performed through apnea test which shows the absence of the bulbar response to increasing CO2 concentration: disconnection from ventilation equipment for 3-5 minutes up to 8-10 minutes is associated with absence of respiratory movements in CO2 pressure values >= 50-60mmHg (formal criteria 60 mm Hg) or causes increasing CO2 pressure up to >=20mmHg more than the normal value.(4)

Another important element is the presence of diabetes insipidus in a brain dead patient, its absence imposing diagnosis delay. Tachycardia response to atropine injection shows loss of cardiac innervation through bulbar vagal neurons. Neurological examination protocol includes pupil examination (which has to be between 4-9 mm with abolished photo-motor reflex), eyeball movements (which must be absent), corneal reflex – absent, spontaneous blinking – absent, facial movements – absent, spontaneous muscle movements – absent, ocular-vestibular reflex, ocular-cephalic reflex, glossopharyngeal reflex, coughing reflex – absent associated with the absence of spontaneous breathing and response to atropine.(12)

Monitoring the eventual organ donor is done for at least 6 hours in cases of primary brain damage and for 24 hours in cases of secondary brain damage. Clinical evaluation of potential donors may be difficult, as each patient can be the ideal donor for a particular organ and donor with some drawbacks for another organ. The donor's age correlates with other conditions, for example hypertension, diabetes.

The cause of death must be well established, suspicions related to central nervous system (CNS) infections, neoplastic diseases must be eliminated.(13) Laboratory evaluations include serology, chemistry, hematology an microbiology examinations.(14,15,16) For example the existence of piercings and tattoos may raise suspicion for infections with hepatitis viruses, human immunodeficiency virus (HIV), and therefore in situations in which this type of actions on the skin occurred in less than 3 months before the patient can be excluded from donation.(1) After clinical establishment of the existence of a potential donor, after following all the previously mentioned steps which were well established by examination protocols there are also necessary laboratory confirmations (14), which are carried out through several methods: EEG, brain angiography, brain scintigraphy, Doppler examination, echocardiography.(17,18,19)

Electroencephalography aspect is extremely important in the confirmation of the brain death, although in United States most medical institutions do not require EEG as an indispensable criteria for the diagnosis.(5)

In brain death, EEG does not present electrical potentials that are over 2mV for a period of 30 minutes

[3]Corresponding author: Doina Carina Voinescu, Str. Al. I. Cuza, Nr. 35, Galați, România, E-mail: carinavoinescu@gmail.com, Phone: +40757 644226
Article received on 14.11.2016 and accepted for publication on 23.02.2017
ACTA MEDICA TRANSILVANICA March 2017;22(1):15-16

(isoelectric aspect). However reaching the moment in which an isoelectric line is registered is purely theoretical, as the artifacts determined by the interference of the surrounding equipment appear on the route: ventilation equipment, electrocardiography (EKG) equipment, other electrical devices.

Moreover, the absence of these artifacts indicates a possible technical problem regarding the EEG recording equipment.(1)

The EEG registration is performed after 6 hours since the causal event, and then it is repeated up to 24 hours before declaring brain death. The route must show the absence of the electrical activity for at least 30 minutes, while registering it on 16 channels with electrodes placed at a distance of 10 cm from each other, frontal, temporal, occipital and parietal including during painful stimulus. Sometimes, on the EEG route there can be EKG aspects recorded, with the appearance of a QRS complex.

The ideal aspect – isoelectric – of the EEG is influenced by artifact given by the ventilation equipment, by the electrocardiograph and by all the other electrical devices that are around. Moreover, the absence of these artifacts and the obtaining of an ideal isoelectric line raises high suspicions about the well functioning of the encephalograph. The EEG route will be monitored for 24 hours.

We exemplify an EEG aspect in a patient that was brain dead, due to a brain hemorrhage, caused by a brain aneurysm: no electrical potentials that are over 2mV (the absence of the electrical activity), with artifacts determined by the interference of the surrounding equipment (figure no. 1).

**Figure no. 1. EEG route in a brain dead patient**

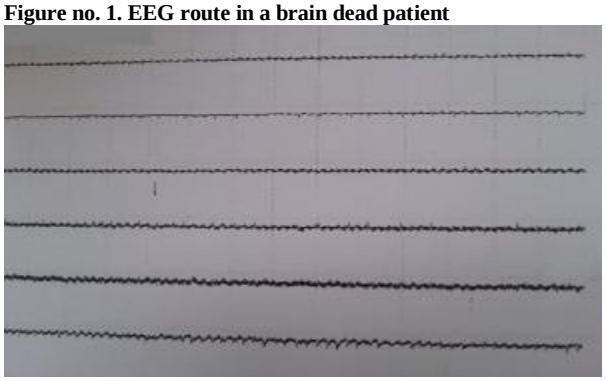

Evoked visual potentials are not a criterion that is worth following because they may show various abnormalities.

Some medical centers use brain scintigraphy or brain angiography to demonstrate the absence of intracranial circulation, though clinical diagnosis is preferred, because false – negative results may appear.

Arteriography on 4 vessels shows the absence of intracranial circulation: total suppression of all arterial contrast and the absence of venous flow, full suppression of the blood flow in the polygon of Willis, delayed circulation (its extending over 15 seconds is not compatible with the preservation of brain function). However, the administration of contrast substance may lead to the alteration of renal function for the potential donor.

Brain scintigraphy evaluates the blood flow through the brain and of the Tc99 tracer towards the brain parenchyma.

Through Doppler examination, temporal and foramen magnum, we highlight the absence of intracranial blood flow. But in 10% of the cases the time gap is missing and because of this, the initial absence of the Doppler sign is not equivalent with brain death. Low systolic peaks at the start of the systole, with no diastolic flow or turbulent flow indicate the high vascular resistance associated with exceeded intracranial pressure.(20)

In other words, laboratory investigations used in the diagnosis of brain death have pro and con arguments, which make the neurological clinical examination to become essential in this situation.

So, the neurologist has a major moral, legal and medical responsibility to declare a patient a possible organ donor and to allow the rest of medical team to harvest the organs.

## REFERENCES


1. Adams and Victor's Principles of Neurology - Tenth Edition, McGraw-Hill Education, USA; 2014.
2. Harvard Criteria. Report of the AdHoc Committee of the Harvard Medical School to Examine the Definition of Brain Death. A definition of irreversible coma. JAMA. 1968;205:337-340.
3. Randell TT. Medical and legal consideration of brain death. Acta Anaesthesiologica Scandinavica. 2004;48(2):139-144.
4. Evaluare. Diagnostic. Management. Donare/transplant. Legislaţie: OMS 1246.
5. Guidelines for the Determination of Death, JAMA 11/13/1981;246 (19):2184-2186.
6. Greenberg MS. Handbook of neurosurgery- Fourth Edition, Greenberg Graphics, Florida; 1997. p. 564-570.
7. Dujardin KS, McCully RB, Wijdicks EF, et al. Myocardial dysfunction associated with brain death: clinical, ecocardiographic and pathologic features, J. Heart Lung Transplant. 2001;20:350.
8. Cooper DK, Novitzky D, Wicomb WN. The pathophysiological effects of brain death on potential donor organs, with particular reference to the heart. Ann R Coll Surg Engl. 1989;71:261.
9. Popa C. Moartea cerebrală şi managementul transplantului de organe, vol. A XIV-a Conf. Nat. de Stroke: Sinteze si rezumate; 2013. p. 75-91.
10. Popa C. Moartea cerebrală, in vol. A-XIV-a Conf. Nat.de Stroke- Sinteze şi rezumate; 2013. p. 49-56.
11. Canadian Neurocritical Care Group. Guidelines for diagnosis of brain death. Can J Neurol. Sci. 1999;26:64-66.
12. Report of the Quality Standards Subcommitte of the American Academy of Neurology. Practice parameters for determinating brain death in adults. Neurology. 1995;45:1012-1014.
13. Rosendale JD, Chabalewski FL, McBride MA, et. al.: Increased transplanted organs from the use of a standardized donor management protocol. Am J Transplant. 2002;2:761.
14. Hufschmidt A, Lucking CH. Neurologie integrala, de la simptom la tratament, Ed. Polirom; 2002. p. 348-350.
15. Totsuka E, Fung JJ, Ishii T, et al. Influence of donor condition on postoperative graft survival and function in human liver transplantion. Transplant Proc. 2000;32:322.
16. Wijdicls EFM. Determinating brain death in adults. Neurology. 1995;45:1003.
17. Rosendale JD, Chabalewski FL, McBride MA, et. al.: Aggressive pharmacologic donor management results in more transplanted organs. Transplantation. 2003;75:482.
18. Cooper DK, Novitzky D, Wicomb WN. The pathophysiological effects of brain death on potential donor organs, with particular reference to the heart. Ann R Coll Surg Engl. 1989;71:261.
19. Zaroff J. Echocardiographic evaluation of the potential cardiac donor. J Heart Lung Transplant. 2004;23:250.
20. Tiu C, Antohi F. Neurosonologie, Ed. SemnE, Buc.; 2006. p. 219- 228.