THEORETICAL AND PRACTICAL ASPECTS OF DENTAL RECONSTRUCTIONS WITH FIBERGLASS POSTS AND COMPOSITE MATERIAL

MONA IONAȘ[1]

[1] *"Lucian Blaga" University of Sibiu*

Keywords: *fiberglass posts, composite resin, aesthetic restoration*

Abstract: *In the past, severely mutilated tooth crown reconstructions had as a single option, namely the realization of a metallic cast posts. Nowadays, the patients want treatments with a high aesthetic result. Crown reconstructions with fiberglass posts and composite material are being used more and more frequently due to their simple technique of treatment and durability over time.*

INTRODUCTION

The restoration of endodontically treated teeth is very important in dental practice, involving a wide range of therapeutic options with variable complexity. In recent years there have been major changes in the field of crown restorations, the metallic cast posts being increasingly replaced by non-metallic root posts, used in combination with the composite material for the realization of the crown reconstructions.(1)

The root post is not necessary for teeth which only lack in substance due to the creation of access to endodontic therapy. Not using of a root pivot is conditioned by the existence of clinical requirements: there are no horizontal cracks in the coronary section, the tooth being not subjected to excessive occlusal forces such as the canine guide or the teeth subjected to bruxism. Otherwise, the placement of a root post is required to ensure the longevity of the restoration.(2)

PURPOSE

The purpose of this paper is to present a simple technique of restoring endodontically treated teeth with fiberglass post and composite material

MATERIALS AND METHODS

The method used in the crown reconstitutions with fiberglass post is as follows:

- Retro alveolar radiography to verify the correctness of the endodontic treatment before inserting the fiberglass post
- Isolation with the rubber dam
- Removing the gutta-percha with a drill
- Choosing the drill to create the fiberglass post housing and preparing the calibrated groove
- EDTA irrigation to remove the gutta-percha and the root-sealant
- Degreasing the fiber with alcohol
- Apply cement to the root canal. If application tips are used, they must be immersed in the cement to avoid the occurrence of air inclusions. If self-adhesive cement is used, the technique is simplified because it eliminates the conditioning stages of the dental tissue.
- The post rotates gently and a moderate pressure is applied to fix it in the desired position. Before fixing the post, remove excess cement with a scraper or a probe or light-cure for 2 seconds then remove excess cement. It is photopolymerized for 40 seconds or it can be waited for 5 minutes until it is self-polymerized.
- By means of a diamond burr, shorten the fiberglass post to the required size, before the restoration is complete. The fiberglass post should be preferably completely covered by the composite material, otherwise it may change its color due to the temperature variation.
- Next the accomplishment of the coronal section with composite material follows.

In the canals in which the canal circumference is 50% larger than the thickest fiber, additional fiberglass posts will be used. Insert first the cement into the canal then the master fiber post and then the additional fiber posts on which the cement is applied.(3)

RESULTS

The first case presents, step-by-step the crown reconstruction in the frontal area using RelyX ™ Fiber Post (3M ESPE), self-adhesive cement (RelyX U100 3M-ESPE) Filtek Bulk composite (3M ESPE) and composite material Z 250 (3M ESPE) (figure no. 1).

There is also presented a case of failure due to the infringement of the Ferrule rules, in a patient with bruxism who exerts excessive force. The materials used are fiberglass post (Glassix), self-adhesive cement (RelyX U100 3M-ESPE) and micro-hybrid composite (Z 250-3M-ESPE) (figure no. 2).

DISCUSSIONS

The Ferrule effect is accepted in dentistry as a restoration principle of the endodontically treated teeth. The Ferrule effect sets a long-term prognosis for an endodontically treated tooth. The factors involved in determining the prognosis of a tooth are direct and indirect. Direct factors are those determined by the Ferrule effect: the height of the remaining dentine wall, the wall thickness, the number and the distribution of the remaining walls, as well as the type of forces exerted on the respective tooth. Indirect factors are those that can influence the functionality of the Ferrule effect, namely the type of root anchor and the composite material. For the clinician, it is very important to obtain a height of 2mm and a width of 1mm of the dentine wall, which surrounds the tooth on at least half the circumference. The location of the dental walls, the direction and the magnitude of the exerted forces at tooth level are complementary in terms of prognosis of the tooth.(4)

[1]Corresponding author: Mona Ionaș, Str. Lucian Blaga, Nr. 2A, Sibiu, Romania, E-mail: stomatologmonaionas@yahoo.com, Phone: +40269 436777
Article received on 14.04.2017 and accepted for publication on 25.05.2017
ACTA MEDICA TRANSILVANICA June 2017;22(2):87-88

Problematical is also the use of endodontically treated teeth in a large classical dental bridge, especially for patients with bruxism.(5) In our case, the failure occurred because of disregarding the Ferrule effect in a patient with excessive force generated by bruxism. Clinicians wishing to perform a crown reconstruction should be aware of the fact that the root anchorage allows retention of the coronary reconstruction and does not have the role of strengthening the tooth. When it is inserted into the root, it can lead to tooth damage.(6)

Figure no. 1. The technique used in the crown reconstruction with fiberglass post and core composite materials, Figure no. 1.a. Initial radiological appearance of the tooth 3.2 to be restored with fiber post. Figure no. 1.b. Isolated tooth, ready for preparation. Figure no. 1.c. Preparing the canal with a calibrated drill and checking the length of the preparation. Figure no. 1.d. Test of the fiber post into the canal. Figure no.1.e. Drying the canal Figure no. 1 f. Fiber post cemented in the canal. Figure no. 1.g. Stage of the coronal reconstruction, application of the adhesive system. Figure no. 1.h. Applying fluid composite material in the neighboring area of the fiber-post, where the condensation of the classical composite material is hampered by the presence of the fiber post

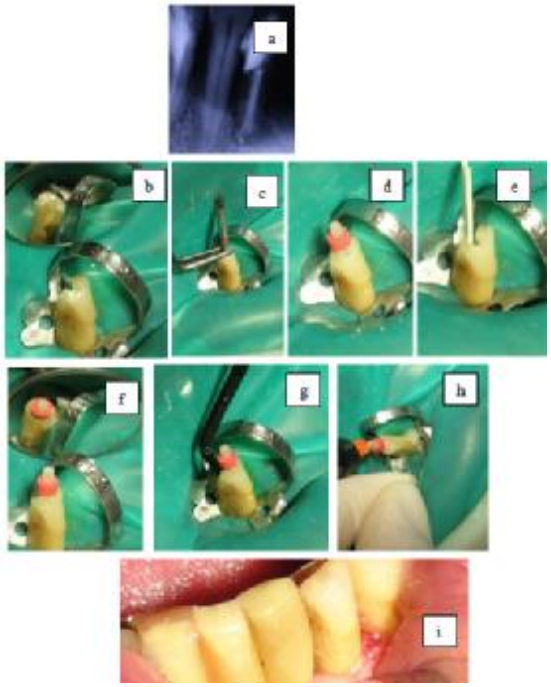

Figure no. 2. Failure of the coronal restoration with fiber post, Figure no. 2.a Tooth 44 with dislodged fiber post, without root fracture, in a patient with bruxism. Figure no. 2b. Metal polymer dental prosthesis fractured and dislodged fiberglass post

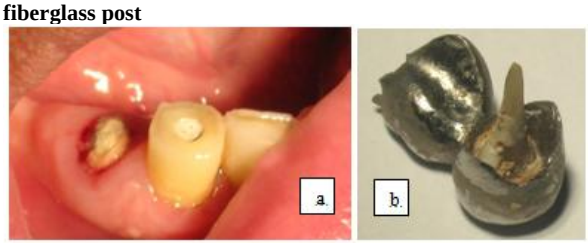

Regarding the prevention of root fractures of an endodontically treated and restored tooth with fiberglass post, the presence of the Ferrule effect is more important than is the type of root post or the composite material used for the coronal restoration.(7) The fracture of the reconstructed teeth with fiberglass post is reduced.(8) In our case of failure, one can observe that the fiber post has been dislodged without any root fracture. The elasticity of the fiberglass posts is close to that of the dentine, so that it does not concentrate the forces at the tip of the root.(9) The root length of the tooth that must be anchored must allow 4-5 mm of gutta-percha at apical level, for the apical sealing to be performed.(10,11,12) Practically, the length of the post is dictated and limited by the existence of a root curve and by the need to preserve a minimum apical seal with gutta-percha. There is not enough clinical data with regard to the relationship between the post length and the alveolar bone, but it is advisable to extend the post below the alveolar ridge when it is mandatory for it to be used.(13)

CONCLUSIONS

A careful and correct assessment of the teeth to be restored with fiberglass posts is mandatory prior to starting the crown reconstruction.

REFERENCES

1. Vițalariu AM. Reconstituirile Corono-Radiculare, Casa de editură Venus Iași; 2007.
2. Brodbeck UR. Six years of clinical experience with an all-ceramic system. Signature. 1997;4(3 Suppl):6-13.
3. Boksman L, Hepburn AB, Kogan E, Friedman M, de Rijk W. Fiber Post Techniques for Anatomical Root Variations, Dent Today. 2011;30(5):104,106-111.
4. Jotkowitz A, Samet N. Rethinking ferrule –a new approach to an old dilemma, British Dental Journal. 2010;209:25-33.
5. McLean A. Predictably restoring endodontically treated teeth. J Can Dent Assoc 1998;64(11):782-787.
6. Duke ES. Advances in restorative core materials, Compend Contin Educ Dent. 2000;21(11):976-978.
7. Slutzky-Goldberg I, Slutzky H, Gorfil C, Smidt A. Restoration of endodontically treated teeth review and treatment recommendations. International Journal of Dentistry. 2009; doi: 10.1155/2009/150251.
8. Mannocci F, Ferrari M, Watson TF. Intermittent loading of teeth restored using quartz fiber, carbon-quartz fiber, and zirconium dioxide ceramic root canal posts. J Adhes Dent. 1999;1(2):153-8.
9. Manhart J. Fibergalss reinforced composite endodontic posts, Dent Today. 2011;30(3):84,86,88-92.
10. Morgano SM. Restoration of pulpless teeth: application of traditional principles in present and future contexts. J Prosthet Dent. 1996;75(4):375-80.
11. Ferrari M, Vichi A, Mannocci F, Mason PN. Retrospectiv study of the clinical performance of the fiber posts, American Journal of Dentistry. 2000;13(Special Issue):10B-13B.
12. Anderson G, Perdigao J, Jodges J, Bowles W, Efficiency and effectiveness of fiber post removal using 3 techniques, Qiuntessence international. 2007;8:663-670.
13. Whitworth JM, Walls AW, Wassell RW. Crowns and extra-coronal restorations: endodontic considerations: the pulp, the root treated tooth and the crown. Br Dent J. 2002;192(6):315-320.