CASE PRESENTATION: IMPLANT AND PROSTHETIC MANAGEMENT OF A CASE WITH AN ACCESSORY MENTAL FORAMEN

IULIANA BABIUC[1], MIHAELA PAUNA[2], CLAUDIA MATEIAŞ[3], GABRIELA TĂNASE[4], AUGUSTIN MIHAI[5], MĂDĂLINA MALIȚA[6], RADU COSTEA[7], MIHAI BOGDAN BUCUR[8], CAMELIA IONESCU[9], MIHAI BURLIBAȘA[10]

[1,2,3,4,5,6,7,8,9,10] *"Carol Davila" University of Medicine and Pharmacy Bucharest*

Keywords: *accessory mental foramina, implant, CBCT, mandible anatomy*

Abstract: *Accessory mental foramina represent a morphological variation found with a variable frequency in different populations. They are smaller diameter canals and foramina with a neuro-vascular content, usually located distally from the mental foramen. Cone bean computed tomography (CBCT) Technology allows for the detection and detailed description of the accessory mental foramina. This is a report of a clinical case where an accessory mental foramen was identified on the CBCT analysis. Careful implant planning was carried out, which allowed for an optimal implant position in relation to the neighbouring tooth and to the accessory mental foramen and canal. A monolithic zirconia crown restored an optimal function for the patient.*

INTRODUCTION

A good analysis of the anatomical features of the surgical site is mandatory in implant dentistry. CBCT technology offers a very detailed insight of the clinical parameters of the patient and has become a standard investigation in dentistry prior to implant treatment. It allows for an optimal measuring of the available bone, as well as a good observation of the bone quality. CBCT analysis offers detailed exploration of the anatomy of the site, which allows for an optimal planning of the surgical maneuvers in order to avoid neuro-vascular structures.(1)

An important landmark in implant dentistry is the mandibular canal. Its course, position and morphology must be carefully analyzed prior to implant placement. The mandibular canal contains the inferior alveolar nerve and artery and an injury of those structures can cause intense bleeding and neurological complications.(2,3) The inferior alveolar nerve has two terminal branches: the incisive nerve and the mental nerve, which exits the mandible through the mental foramen. The anatomy of the premolar region of the mandible is dominated by the position of the mental foramen.(4) There are numerous reports concerning the position of the mental foramen, the most common being between the two premolars and in the long axis of the second premolar.(5-9)

Variations of the position and morphology of the mental canal and foramen have been reported. The presence of accessory mental foramina has been first observed on cadaver studies and dry skulls. The increased usage of CBCT technology has led to numerous reports about the detection of additional mental foramina in the cases investigated for dental implant treatment.(10-14) The incidence of this morphological variation seems to between 5 to 11%, more frequent in Japanese and Asian populations. These are smaller diameter canals and foramina usually located distal to the main foramen. Dissection studies have shown that the accessory mental canals and foramina contain neuro-vascular structures. Toh et al (14) reported an accessory mental nerve which innervated the mucosa and skin of the corner of the mouth and of the median labial area. Other studies found communications between the accessory mental nerve with braches of the facial and buccal nerves.

The current report aims to present a clinical case where an accessory mental foramen was detected. The surgical and prosthetic treatment was modified in order to avoid damaging this anatomical structure.

CASE PRESENTATION

A 65-year-old male patient requested implant treatment to replace a missing lower first molar, which was extracted 3 years prior to the visit. The patient had no significant medical history.

A CBCT analysis was performed, to establish the dimensions of the alveolar crest, the bone density and to explore the characteristic features of the surgical site. A radiological report was sent from the radiology centre, together with the DICOM files. The markings and measurements of the report indicated a favourable situation of the site for the insertion of a dental implant. It marked the position of the mandibular canal and of the mental foramen. It also showed the alveolar crest had an optimal width and height. However, this report did not mark the presence of an additional mental foramen located distally and coronal to the main mental foramen. Cross-sectional slices indicate the presence of an accessory mental canal 1,5 mm in diameter and a corresponding accessory mental foramen very close to the tip of the alveolar crest and in close proximity of the edentulous crest that had to be restored with implant treatment.

An independent exploration of the surgical site was performed by the clinician using the DICOM files, in order to clarify the anatomy of the surgical site. The 3D reconstruction of the mandible was analysed, as well as cross-sectional and oblique tomographic slices. The emergence of the accessory mental canal from the mandibular canal was observed. The position of the future implant was carefully planned on the tomographic volume, making sure the accessory mental canal and foramen would be avoided during the surgical procedure.

[4]Corresponding author: Gabriela Tănase, Str. Plevnei, Nr. 19, Sector 5, București, România, E-mail: mburlibasa@gmail.com, Phone: +40723 472632
Article received on 10.07.2017 and accepted for publication on 28.08.2017
ACTA MEDICA TRANSILVANICA September 2017;22(3):64-66

Figure no. 1. The curved slice of the left hemimandible in the tomographic report. A second mental foramen can be spotted distally to the apex of the second premolar

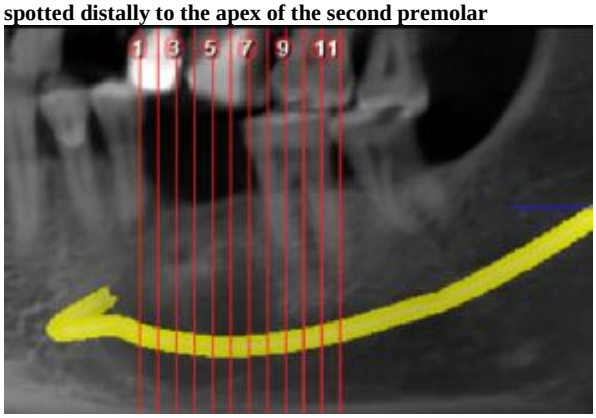

Figure no. 2. Cross-sectional slices of the mandible depicting the accessory mental canal and foramen emerging from the mandibular canal

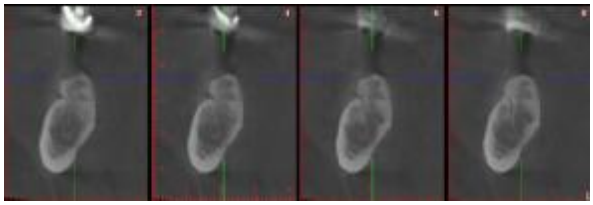

After performing local anaestesia, a limited gingival flap was raised, exposing the tip of the alveolar bone. An osteotomy corresponding to the distal root of the 36 was performed. A 4/12 mm implant was inserted with a torque of 40N/cm^2. A healing abutment was placed. The position of the implant was verified radiographically. Optimal distance to the neighbouring tooth and to the accessory mental foramen was observed.

Figure no. 3. Radiography depicting the newly placed implant and its' position in relation to the accessory mental foramen and to the neighbouring tooth

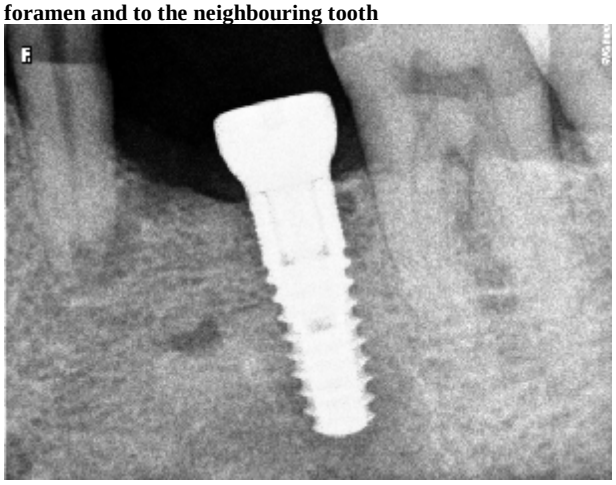

The patient had minimal postsurgical discomfort. No neurological complications were reported.

After a healing period of 2 months, the implant was restored with a standard abutment and a monolithic zirconia crown, which was extended mesially to close the edentoulous space. Care was taken in the design of the mesial aspect of the crown, to restore and optimal contact point and to reduce the risk of food and plaque retention. The prosthetic solution proved functional and resistant. The patient was satisfied with the restored masticatory function. No food entrapment was reported for the mesial extension of the crown.

Figure no. 4. Occlusal view of the standard abutment

Figure no. 5. Occlusal view of the monolithic zirconia crown

Figure no. 6. Buccal aspect of the monolithic zirconia crown cemented on the implant abutment. The mesial contact point is restored and the mesial embrasure is of normal dimensions

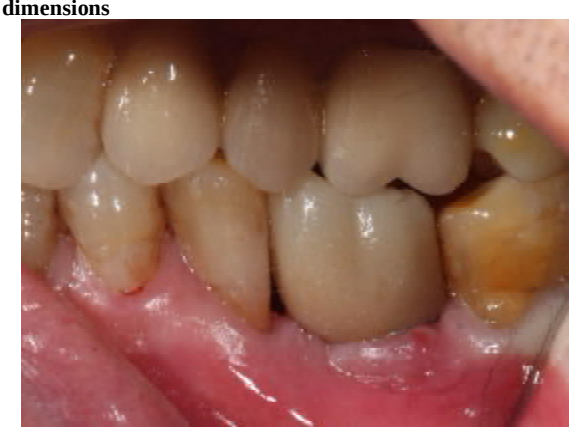

DISCUSSIONS

Understanding the anatomy of the surgical site has a great importance in the success of the implant treatment. CBCT

technology offers the opportunity to investigate with great accuracy the characteristic features of the clinical case and help the practitioner to take the correct decisions regarding the surgical procedures.

Accessory mental foramina proved to be relatively frequent throughout different populations. Some studies (10-14) report an incidence of up to 11% of the cases. These little foramina are usually located distally and coronally from the main mental foramen, on the buccal side of the alveolar crest corresponding to the second premolar and first lower molar. Therefore, care must be taken in observing the tomographic anatomy of the region when implant treatment is planned. The content of the accessory mental canal has proved to be neuro-vascular (14), which means that injury of the emergence can cause intense bleeding and neurologic complications. The current case presented a large accessory mental canal and foramen, with a diameter greater of 1,5mm. It is considered that injury to the arterial structures that have a greater diameter of 1mm can lead to intense bleeding. With proper implant planning, the patient underwent an uneventful healing, with no bleeding or neurologic complications.

It is therefore important for the clinicians to analyze themselves the surgical site with the CBCT, in order to correlate the clinical procedures to the anatomy of the case.

CONCLUSIONS

Good knowledge on surgical anatomy is crucial for a complication-free procedure. CBCT technology proved to be a valuable tool for an accurate diagnosis and planning of the reported case and should be used every time implant treatment is indicated.

REFERENCES

15. Al-Faraje L. Surgical and radiologic anatomy for oral implantology. Quintessence Publishing; 2013. p. 169-200.
16. Wandu SG, Penhall B, Townsend GC. Morphological variability of the human inferior nerve. Clin Anat. 1997;10:82-87.
17. Clemente CD. Cranial nerves. In: Gray H., ed. Anatomy of the human body 30th American Edition. Philadelphia: Lea & Febiger; 1985. p. 1165-1169.
18. Carter RB, Keen EN. The intramandibular course of the inferior alveolar nerve. J of Anatomy. 1971;108:433-40.
19. Greenstein G, Tarnow D. The mental foramen and nerve: Clinical and anatomical factors related to dental implant placement. A literature review. J Periodontol. 2006;77:1933-1943.
20. Mwaniki DL and Hassanali J. The position of mandibular and mental foramina in Kenyan African mandibles. East African Medical Journal. 1992;69(4):210-213.
21. Akabori E. Crania nipponica recentia 1. Analytical inquiries into the non-metric variations in Japanese skull according to age and sex. Japanese J of Medical Sciences 1. Anatomy. 1992;4:61-315.
22. Mbajiorgu EF, Mawera G, Asala SA, Zivanovic S. Position of the mental foramen in adult Black Zimbabwean mandibles: a clinical anatomical study. Central African Journal of Medicine. 1998;44(2):24-30.
23. Green RM. The position of the mental foramen: a comparison between the southern (Hong Kong) Chinese and other ethnic and racial groups. Oral Surgery, Oral Medicine, Oral Pathology. 1987;63(3):287-90.
24. Naitoh M, Hiraiwa Y, Aimiya H, Gotoh K, Ariji E. Accessory mental foramen assessment using cone-beam computed tomography. Oral Surgery Oral Medicine Oral Pathology Oral Radiology Endodontics. 2009;107:289-294.
25. Kodera H, Hashimoto I. A case of mandibular canal elements of nerves and arteries in this canal. Kaibougaku Zashi. 1995;70:23-30.
26. Naitoh M, Yoshida K, Nakahara K, Gotoh K, Ariji E. Demonstration of accessory mental foramen using rotational panoramic radiography compared with cone-beam computed tomography. Clin Oral Impl Res. 2011;22(12):1415-1419.
27. Hanihara T, Ishida H. Frequency variations of discrete cranial traits in major human populations. IV. Vessel and nerve related variations. J of Anatomy. 2001;199:273-287.
28. Toh H, Kodama J, Yanagisato M, Ohmori T. Anatomical study of the accessory mental foramen and the distribution of its nerve. Okajimas Folia Anatomica Japonica. 1992;69:85-88.