A CASE REPORT OF AN AORTIC FLOATING THROMBUS WITH PERIPHERAL EMBOLIZATION IN A 29-YEAR OLD APPARENTLY HEALTHY SUBJECT

IULIA BIANCA CATRINA[1], IOAN MANIŢIU[2], GABRIELA EMINOVICI[3]

[1,2,3]*"Lucian Blaga" University of Sibiu*

Keywords: *aortic thrombosis, arterial embolism, thrombophilia*

Abstract: *Aortic thrombosis is a common scenario in the aneurysmal aorta, but in a morphologically normal aorta is a rare event. Only a few cases, especially at young age, have been reported. We report a case of aortic thrombosis in a 29-year old female, without any medical history, who was admitted with an acute ischemic syndrome located in the right foot. 2D-3D ultrasound and computed tomography scans revealed the presence of a 4-6 cm thrombus, located at the abdominal aorta, with distal embolization of the right popliteal artery. An extensive serologic survey revealed inflammatory syndrome and thrombophilia.*

INTRODUCTION

Etiological diagnosis of arterial embolism is a complex task. More than 85% of peripheral arterial embolisms (PAE) originate in the cardiac cavities. Imaging techniques such as computed tomography (CT) scan, magnetic resonance imaging and 2D-3D echography are helping to detect, with increasing frequency, non-cardiac sources of PAE, among them, the aorta has been reported in up to 5% of cases to be the origin of PAE.(1) Usually the source of major arterial embolism is a thrombus in the aneurysmal or atherosclerotic aorta, but emboli originating from a morphologically normal aorta are a rare event.(2) Although the major factor responsible for the formation of thrombus in the aortic wall is the Virchow's triad, the detailed mechanism of aortic thrombosis has not been fully elucidated and the therapeutic strategy is still controversial.(3)

We report a case of a large and highly mobile thrombus, located within a normal abdominal aorta, resulting in peripheral embolism that caused acute ischemia in the right lower extremity.

CASE REPORT

A 29-year old woman was admitted accusing acute pain, coldness and anesthesia in the right foot. Clinical examination revealed absent pulses at the right popliteal, posterior tibial and dorsalis pedis arteries.

For cardiovascular and prothrombotic risk factors, she had a 9 years history of cigarette smoking (10-15 cigarettes/day) and a history of 24 months contraceptives usage. Otherwise she has no previous medical history of arrhythmia, stroke, ischemic heart disease and diabetes mellitus.

Emergency 2D- ultrasound of the arterial system of the limb revealed acute thromboembolic occlusion of the right popliteal artery. A diagnostic work up was initiated to determine the source of the embolism. Holter monitoring ECG showed no pathologic changes. 2D-3D ultrasound of the hearth showed no structural or functional abnormalities, but going further with the ultrasound and examining the thoracic and abdominal aorta an large and hypermobile thrombus was revealed (figure no. 1a, b, figure no. 2) located in the infrarenal area, attached to a non-aneurysmal aorta, without any visible signs of an atheromatous plaque, but with a slight thickening of the aortic wall and a intima with an irregular contour (figure no. 3).

Figure no 1. a) 3D ultrasound examination, longitudinal scan, revealing the presence of a thrombus in the abdominal aorta

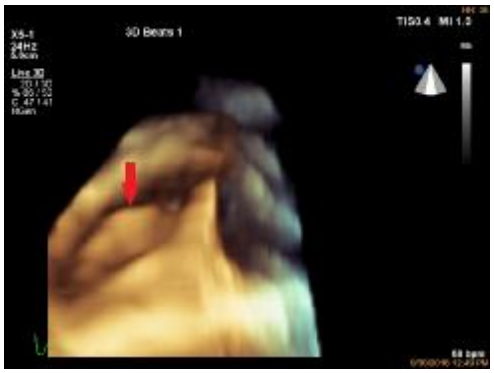

Figure no. 1 b) 3D ultrasound, transversal scan that shows the same thrombus in its distal portion

[1]Corresponding author: Catrina Iulia Bianca, Str. George Matei Cantacuzino, Nr.53, Cisnădie, Sibiu, România. E-mail: catrina.bianca@ymail.com, Phone: +40785 777100
Article received on 21.10.2017 and accepted for publication on 04.12.2017
ACTA MEDICA TRANSILVANICA December 2017;22(4):29-31

Figure no. 2. Color Doppler sonogram emphasizing Doppler flow around the thrombus

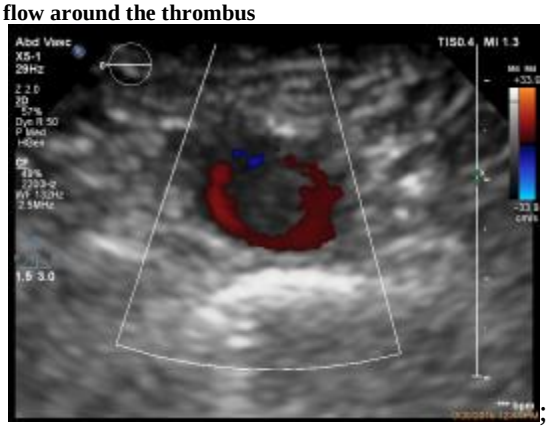

Figure no. 3. 2D ultrasound showing a slight thickening of the aortic wall and an intima with an irregular contour

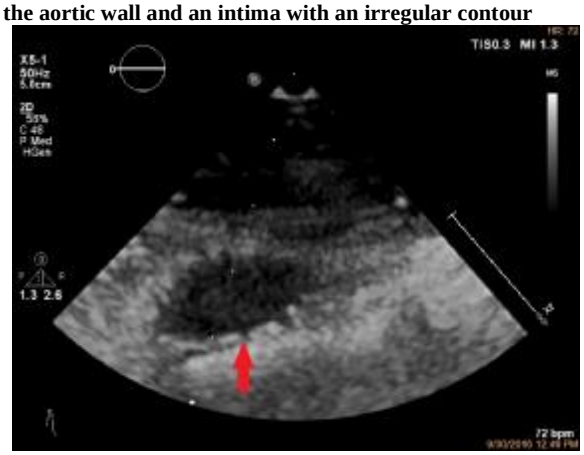

CT scans of the thoraco-abdominal aorta and lower limbs arterial system confirmed the presence of the thrombus (figure no. 1e), without any other size changes or atherosclerosis visible signs.

Figure no. 4. Computed Tomography scan showing the thrombus and its pedunculous form

Biochemical laboratory parameters showed a minimal inflammatory syndrome (C-reactive protein was 24 with a reference of < 6) but with no other changes in the other parameters. An extensive serologic survey for hypercoagulability was deducted, and it turn out positive for thrombophilia (heterozygous mutation of MTHFR C677T, heterozygous mutation of the XIII V34L factor, homozygous PAI-1 5G/5G mutation and the presence of A1/A3 EPCR alleles). Homocysteine level was 12.22 µmol/L with a maximum level accepted as normal 15.00 µmol/L.

The patient was given anticoagulant therapy with unfractionated heparin, for 10 days, during which the aortic thrombus disappeared and partial permeabilization of the popliteal thrombus was noticed. The patient was discharged with the indication to continue treatment with oral anticoagulants and to return for check-up after a month. After 6 months the popliteal thrombus also disappeared with full reperfusion of the popliteal artery.

DISCUSSIONS

Vaideeswar et al analyzed 30 cases of non-atherosclerotic and non-aneurysmal aortic thrombosis in order to investigate the etiology. The conclusion was that this pathology includes a heterogeneous group of disorders and that the patients presenting it should be investigated for hypercoagulability states and aortic diseases.(4)

Hypercoagulability usually results in venous thrombosis, arterial thrombosis is rare and aortic rarer. Common factors that involve thromboembolism are factor V Leiden, prothrombin mutation and deficiencies of protein S, protein C and antithrombin. Elevated levels of C-reactive protein and homocysteine are thought to be involved in arterial thrombosis.(5) The genetic mutations that our patient presented were more likely to predispose to venous thrombosis, not arterial.

Multiple studies implicate numerous acquired risk factors such as obesity, aortic atherosclerosis and metabolic syndrome as a cause of atherothrombosis.(6) But in our case no such associations were seen. Other conditions like gastrointestinal tumors were ruled-out by CT.

Jean-Patrice Baillargeon et al (7) concluded that current use of low-dose oral contraceptives significantly increases the risk of cardiovascular events, including a significant risk of arterial complications with third generation oral contraceptives. Our patient had a third generation oral contraceptives usage history of 24 months.

The combination of smoking and oral contraceptives usage is a substantial risk factor for cardiovascular complications. Smoking induces global changes in vascular function (8), the most important effect of cigarette smoking in thromboembolic complications may be endothelial disturbance and fibrin formation.(9) In the study by Laperche et al (10) smoking was the leading risk factor, and histopathological examination revealed microscopic features of atherosclerosis limited to the insertion site of the thrombus in all patients. Considering the slight thickening of the aortic wall and the intima with the irregular contour seen in ultrasound examination it is likely that the thrombus in our patient was attached to an atherosclerotic plaque.

Different types of treatment are available, with variable success depending of the different forms of the pathology, including anticoagulant therapy alone, thrombolysis, surgery and thromboaspiration.(8) In our case we initiated anticoagulant therapy with heparin and because of the remarkable response to therapy, we decided to continue with it, and the patient was discharged with indication of oral anticoagulation therapy. She was explained all treatment options, but decided to continue only with non-invasive

treatment.

CONCLUSIONS

Embolic events arising from thrombi within a non-atherosclerotic, non-aneurysmatic aorta is a rare but possible event. Physicians should be aware of the risk of associating contraceptive therapy to a patient who already presents thrombotic risk factors, such as smoking and thrombophilia.

Although the prevalence is low, arterial thrombosis can occur in thrombophilic patients especially if there is a combination of predisposing factors that provides the proper substrate for their development.

2D-3D echography together with CT scans are the most appropriate initial imaging modalities for the diagnostic and therapeutic management of this pathology.

REFERENCES

1. Cañadas V, Vilacosta I, Luaces M, Bustos A, Ferreirós J, Aragoncillo P, et al. Thrombosis in an Apparently Normal Thoracic Aorta and Arterial Embolism. Rev Esp Cardiol. 2008;61(2):196-200.
2. Panetta T, Thompson JE, Talkington CM, Garrett WV, Smith BL. Arterial embolectomy: a 34-year experience with 400 cases. Surg Clin North Am. 1986 Apr;66(2):339-53.
3. Wolberg AS, Aleman MM, Leiderman K, Machlus KR. Procoagulant activity in hemostasis and thrombosis: Virchow's triad revisited. Anesth Analg. 2012 Feb;114(2):275-85.
4. Vaideeswar P, Deshpande JR. Non-atherosclerotic aorto-arterial thrombosis: A study of 30 cases at autopsy. J Postgrad Med. 2001 Jan-Mar; 47(1):8-14.
5. Asanuma Y, Oeser A, Stanley E, Bailey DG, Ayumi Shintani, Stein CM. Effects of C-reactive Protein and Homocysteine on Cytokine Production: Modulation by Pravastatin. Arch Drug Inf. 2008 Jul;1(1):14–22.
6. Zhong L, Hollensead S, Parker JC. Extensive aortic thromboembolism due to acquired hypercoagulable state: an autopsy case report. Arch Pathol Lab Med. 2005 Feb;29(2):247-50.
7. Baillargeon JP, McClish DK, Essah PA, Nestler JE. Association between the Current Use of Low-Dose Oral Contraceptives and Cardiovascular Arterial Disease: A Meta-Analysis. The Journal of Clinical Endocrinology & Metabolism. 2005;90(7):3863-3870.
8. Malyar NM, Janosi RA, Brkovic Z, Erbel R. Large mobile thrombus in non-atherosclerotic thoracic aorta as the source of peripheral arterial embolism. Thrombosis Journal. 2005;3:19.
9. Smith FB, Lowe GD, Fowkes FG, Rumley A, Rumley AG, Donnan PT, et al. Smoking, haemostatic factors and lipid peroxides in a population case control study of peripheral arterial disease. Atherosclerosis. 1993;102(2):155-162.
10. Laperche T, Laurian C, Roudaut R, Steg PG. Mobile thromboses of the aortic arch without aortic debris. A transesophageal echocardiographic finding associated with unexplained arterial embolism. The Filiale Echocardiographie de la Societe Francaise de Cardiologie. Circulation. 1997;96(1):288-294.