SURGICAL TREATMENT INDICATIONS IN NERVE ROOT COMPRESSION BY HERNIATED LUMBAR DISC

MIRCEA VICENȚIU SĂCELEANU[1], ANCUȚA-MARIA PLEȘERU[2], ADRIANA SĂCELEANU[3]

[1,3] "Lucian Blaga" University Sibiu, [1,2,3]Clinical County Emergency Hospital Sibiu

Keywords: *surgical indications, lumbar disc, herniation*

Abstract: *Degeneration of intervertebral discs is the consequence of aging and inevitable minor spinal traumas. Back pain is among the most frequent medical complaints, affecting almost 80% of the adult population. We present the case of a 48 year old male admitted with classical clinical features of sciatica, with associated motor deficit affecting the anterolateral calf muscles, extended gradually over a period of 6 months. Magnetic resonance imaging (MRI) of the lower spine revealed inferior migration of the herniated L4-L5 lumbar disc, with L5 nerve root compression. We performed right L4-L5 interlaminary approach, right L5 foraminotomy and ablation of the right L4-L5 herniated disc. There was almost immediate complete regain of muscle strenght in the lower right limb, with dramatical decrease of nerve root pain. Thus, we suggest that surgery should systematicaly be considered as an option, as this positive outcome defied the correlation between duration of preoperative weakness and extent of neurological recovery.*

INTRODUCTION

Degeneration of the intervertebral discs and ligaments is the consequence of aging and the succession of inevitable minor traumas of the spine occurring constantly throughout life. Back pain is amongst the most frequent medical complaints, affecting up to 80% of the adult population (1), so that it has become one of the top expensive health problems and a leading cause of disability amongst individuals younger than 50.(2) Associated back and leg pain are most likely due to nerve root compression secondary to a lumbar disc rupture, generally occurring during the third to fifth decades of life, affecting both genders, more significantly males.(2)

Clinicians recommend waiting 5 to 8 weeks after the onset of the characteristic symptoms of a herniated lumbar disc before considering surgery. During this period of time, conservatory treatment should be based on the limitation of physical strain, administration of nonsteroidal anti-inflammatory drugs, followed after the acute phase by physiotherapy procedures and medical gymnastics.(3)

Surgical treatment is to be performed as soon as one of the following issues arises:

1. progressive motor deficit, which needs rapid surgical decompression of the affected nerve root;
2. intolerable pain despite the use of adequate potent opioid pain medication;
3. cauda equina syndrome;
4. unwillingness of the patient to invest time in non-surgical treatment.(4)

CASE PRESENTATION

We bring forward the case of a 48 year old male patient, with no significant medical history, admitted to the Neurosurgery ward with intense lower back pain, decreased right lower leg muscle strength and consecutive gait impairment.

The onset of this current affliction was fairly insidious, occurring approximately 6 months before admission to hospital, with a gradual succession and progression of the symptoms and sudden worsening during the past two weeks.

On clinical neurological examination, the patient had significant difficulty in sustaining prolonged standing position, sciatic scoliosis and gait impairment with slight forward tilting of the trunk caused by intense lumbar pain, and impossibility of standing or walking on the heels, with the presence of foot drop on the right side.

On inspection of the lower lumbar region, there was no evidence of lesions, local trauma, malformations, or superficial causes of pain.

Palpation revealed paravertebral bilateral intense muscle spasm and tenderness over the fourth lateral lumbar process and right lateral gluteal region.

The straight leg raising test performed on the right elicited severe ipsilateral lumbar burning pain, radiating down the buttock and leg, particularly on the lateral thigh, anterolateral foreleg and dorsal foot at an elevation angle of roughly 35 degrees. Crossed straight raising sign was also present at an elevation angle of about 50 degrees. Paresthesia was almost constantly felt in the distal regions of the radicular painful sites. The deep tendon reflexes were globally normal and symmetric. Muscle strength testing depicted weakness involving the extensors of the right foot and of the big toe, with impaired inversion of the foot.

MRI of the lumbar spine was performed, revealing inferior migration of the herniated L4-L5 lumbar disc, with L5 nerve root compression in the right intervertebral foramina. The herniated disc did not have a transligamentous extension, but it caused moderate lumbar stenosis (figures no. 1, 2).

In the presence of such an obvious motor deficit, the immediate treatament option was surgery. The elected surgical procedure was right L4-L5 interlaminar approach with right L5 foraminotomy followed by the ablation of the right L4-L5 herniated disc.

There were no local or general complications during

[3]Corresponding author: Adriana Săceleanu, Str. Corneliu Coposu, Nr. 2-4, Sibiu, România, E-mail: vicentiu.saceleanu@gmail.com, Phone: +4070 022931
Article received on 18.07.2017 and accepted for publication on 29.11.2017
ACTA MEDICA TRANSILVANICA December 2017;22(4):63-65

postoperative recovery, and we noticed almost immediate complete regain of muscle strength in the lower right limb, with dramatic decrease of nerve root pain.

Figure no. 1. MRI T2WI STIR Sag - Subligamentous L4-L5 herniated disc fragment, no acute spondilar inflammation

Figure no. 2. MRI T2WI Tra - L5 nerve root compression in the right intervertebral foramina

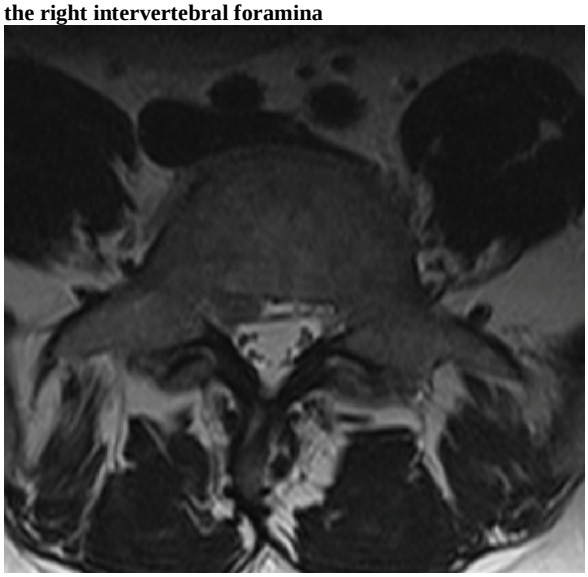

On discharge from hospital, the patient's neurological examination revealed none of the complaints or findings which were present on admission, while surgical recovery was also successful.

DISCUSSIONS

The most commonly affected individuals by lumbar degenerative disc disease are middle-aged men.(5) The highest prevalence in symptomatic herniated discs is amongst people 30 to 50 years of age, with a male to female ratio of 2:1. In this age group, up to 95% of the herniated discs occur at lower levels of the lumbar spine (L4-L5 and L5-S1 levels).(6)

Morphological changes in intervertebral discs like desiccation, fibrosis and cleft formation in the nucleus, fissuring and mucinous degeneration of the anulus, defects and sclerosis of end-plates, are all associated with aging.(7) The degenerative changes in the discs are all cell-mediated processes, in which the normal healing response of the intervertebeal structures are impaired. The intervertebral disc begins to exhibit degenerative changes in the late second or early third decade.(8)

In this particular case, clinical diagnosis was fairly obvious due to the multitude of symptoms and signs of lumbar nerve root compression secondary to lumbar disc degeneration. The positive crossed straight leg sign is highly characteristic for lumbar root lesion.(9)

Serious causes of back pain were eliminated due to the absence of “red flags” such as fever, recent bacterial infection, major trauma, urinary dysfunction, or osteoporosis. The presence of previous carcinoma was excluded through the inquiry of the medical history of the patient, as back pain, sensory and motor deficit could have been signs of tumoral processes affecting the peripheral nervous system.(10)

Although the MRI examination depicted that the migration of the L4-L5 herniated disc caused moderate lumbar stenosis, our patient had no complaints of bladder or bowel dysfunction, and did not present neurogenic intermittent claudication.

However, despite the seemingly common clinical picture, the neurological motor deficit had been present for such an extended period of time, that complete regain of function seemed highly unlikely, if not impossible.

Surgical treatment of lumbosacral radiculopathy is always needed at some point in time in patients who do not respond to conservative medical therapy and must be performed as soon as possible when sensory and especially motor neurological deficits are associated.(1)

Antigravity weakness of the tibialis anterior muscle, commonly known as “foot drop”', is a frequent debilitating condition secondary to lumbar nerve root deficiency. The indication, timing, and benefit of surgery for foot drop remain debatable. Reversal of decreased muscle strength depends on the time it takes for the nerve to recover once the compressive lesion has been dealt with. Duration of preoperative weakness is significantly associated with the extent of recovery.(11)

In our particular case, symptoms lasting for approximately 6 months suggested the postoperatory recovery would be slow and most likely not complete.

However, once the nerve root had been relieved of the mechanic compression through surgical treatment, the patient regained complete motor strength in the first 24-48 hours following the procedure. In our particular case, as the postoperative recovery of the local motor function occurred at such a fast pace, this outcome defies the correlation between duration of preoperative weakness and extent of neurological recovery.

Thus, we suggest that surgery should systematically be considered as an option in such cases, helping the patient to resume his daily life activities at a full extent as soon as possible, with an overall positive impact on the quality of life.

CONCLUSIONS

Back pain is one of the most prevalent morbid conditions amongst the adult population, frequently leading to long-time conservatory medical treatment, absenteeism from work and early retirement. In the absence of additional local and general symptoms to lead to another more serious underlying pathology, associated radicular pain usually signifies lumbar

disc nerve root compression, which should be surgically relieved as soon as possible, especially in the presence of a neurological motor deficit. The prolonged time extent of the motor deficit must not interfere with the decision of surgical treatment.

REFERENCES

1. Ropper AH, Samuels MA, Adams and Victor's Principles of Neurology 9th ed, McGraw Hill; 2009.
2. Biller J, Practical Neurology 5th ed, Wolters Kluwer; 2017.
3. Silișteanu SC, Antonescu E, Szakacs J, Totan M, Roman Filip C, Șerb BH, Cernușcă Mițariu M, Grigore N, Cernușcă Mițariu SI. Study on Changes in Some Physiological parameters Under the Action of Therapeutic Ultrasound. Rev Chim 2017;6(68):1404-1407.
4. Greenberg MS, Handbook of Neurosurgery 5th ed, Thieme; 2001.
5. Vodusek DB, Jeromel M, Podnar S. Spinal Cord Disorders. In: Lisak RP, Truong DD, Carroll WM, Bhidayasiri R, editors. International Neurology. Wiley Blackwell; 2016. p. 626-631.
6. Jordon J, Konstantinou K, O'Dowd J. Herniated Lumbar Disc. BMJ Clin Evid. 2009;2009:1118.
7. Postacchini F, Postacchini R, Operative Management of Lumbar Disc Herniation Acta Neurochirurgica. 2011;Suppl 108:S17-23.
8. Choi YS. Pathophysiology of Degenerative Disc Disease. Asian Spine J. 2009 Jun; 3(1):39–44.
9. Campbell WW Clincal Signs in Neurology A Compendium, Wolters Kluwer; 2016.
10. Roman Filip C, Ungureanu A, Grosu F, Costea M, Gheorghe IT, Flucuș O, Catană A, Dancu R, Isăilă R. Suspected Neurolymphomatosis in the Context of a Disseminated immunoblastic Non-Hodgkin Lymphoma and Borreliosis. Rom J Neur. 2011;9(4):203-205.
11. Bhargava D, Sinha P, Odak S, Tyagi A, Towns G, Pal D, Surgical Outcome for Foot drop in Lumbar Degenerative disease. Global spine J. 2012;2(3):125-128.