CONSERVATIVE TREATMENT OF UTERINE FIBROIDS BY UTERINE ARTERY EMBOLIZATION (UAE)

TUDOR MIHAI BĂDESCU[1]

[1] *"Lucian Blaga" University of Sibiu*

Keywords: *interventional radiology, uterine artery embolization, mini-invasiveness, period of genital activity, preservation of reproductive function*

Abstract: *Uterine leiomyoma is a major public health problem in women of reproductive age. Uterine fibroids may be present in percentages of 15-20% in women of childbearing age and in percentages of 30-40% in women over 30 years of age.(1,2) Newer figures reveal a percentage higher than 50% regarding the frequency of uterine fibroids diagnosed on ultrasound in premenopausal women without symptomatology.(3) Therapeutic conduct in uterine leiomyoma must take into account several aspects characteristic of the disease, first of all its appearance and progression during female genital activity with a maximum in the age range of 35 to 55 years and spontaneous involution with the installation of menopause, all these under hormonal influence. The emergence of demographic and socio-economic changes that have occurred over the last two decades has led to an increase in the procreation age of the first child over the age of 35, which unfortunately corresponds to the maximum incidence of uterine fibroids, so the latter becomes a common cause of female infertility and should be treated compensatorily in order to preserve the reproductive function. An alternative to classical surgery is the of the Uterine Artery Embolization (UAE), a technique with an efficiency of over 85% in terms of dominant symptoms: pain and haemorrhage.(4,5) Embolization of the uterine artery is a safe and effective mini-invasive method that provides permanent infarction of the tumour tissue without its subsequent relapse followed by a significant improvement in symptomatology with rapid socio-professional reintegration.(6)*

INTRODUCTION

Uterine leiomyoma is the most common benign genital tumour, consisting of analogous elements of the uterine muscle.(7) The predominance of the structural elements outlines the myomatous or fibrous appearance.(8) Fibroids are found at a frequency of 3 to 9 times higher in African women than in Caucasian women. Typically, the fibroma occurs at a young age, rarely under 20, usually asymptomatic until 30-40 years of age. The literature mentions the cases of 13-year-old (Wilson) and 9-year-old (Sarati) girls who developed multiple uterine fibroids for the second, respectively a cystic degenerated fibroid in the case of the first. Although not a hereditary disease, the appearance of uterine fibroids in several members of the same family is not an unusual finding, suggesting the possibility of genetic transmission of a predisposing element. There is also a certain ethnic and family predisposition.(9) The most important known risk factor is the presence of a uterine leiomyoma in the mother.(10) Uterine fibroids are clonal tumours that are often based on localized cytogenetic abnormalities. The most common are chromosome aberrations involving chromosomes 6, 7, 12 and 14.(11) Of the total of uterine leiomyomas studied, between 20-60% of leiomyoma cells have cytogenetic abnormalities.(12)

The incidence of fibroma is associated with some features of female genital life, namely: the period of genital activity slightly prolonged period due to menopause (after 50 years old), limited sexual activity, or abstinence that could generate congestion in the genital area according to Stambalovic, a relationship of inverse proportionality between uterine fibroids and fertility.

Using oral contraceptives does not pose an increased risk of uterine fibroids. The risk is even lower if used more than 7 years (Odds ratio 0.5). New generation oral contraceptives reduce the loss of menstrual blood in women with leiomyoma.(13)

Regarding medical past history and diseases associated with uterine fibroids, we mention cardiac disorders and arterial hypertension, even talking about a triad: *uterine fibroid, hypertension and obesity.* Cardiovascular disease cause congestive changes in the splanchnic and pelvic territory (14), being rather a condition favouring tumour development and less the effect of the presence of leiomyoma itself. There is a risk increase by 21% for every 10 pounds of weight gain.(15) Misciagne and his colleagues highlight a significant association between *uterine leiomyoma and gallstones,* finding an increased cholesterol saturation index. If we consider the 2.5-fold higher risk of biliary lithiasis in estrogen-treated women, it can be assumed that even an increased or uncontracted estrogen production may be a condition both for the appearance of lithiasis and for the appearance of uterine fibroma. There is also evidence of association of uterine fibroma with a range of *endocrine-metabolic disorders*: thyroid disorders, acromegaly, obesity.

Surgical interventions in the genital sphere are accompanied by disturbances in the uterine return circulation, and chronic venous insufficiency syndrome is frequently associated with pelvic varicose veins, as revealed flebographically by Reveli et al. in 1959.

Smoking, in contrast, recognized as a risk factor in cardiovascular disease, would reduce the incidence of fibroma in smoking women by low concentrations of active estradiol.

[1]Corresponding author: Tudor Mihai Bădescu, Str. Gh. Ţiţeica, Nr. 14, Şelimbăr, România, E-mail: tudor_badescu@yahoo.com Phone: +40722 370089

Article received on 17.10.2017 and accepted for publication on 26.02.2018
ACTA MEDICA TRANSILVANICA March 2018;23(1):81-85

Surgical (classical or laparoscopic) surgery aims at removing the tumour, at partially or completely preserving the female genital function, with the best possible vital and functional prognosis. Fibromatous uterus surgery may be a radical (hysterectomy) or conservative (myomectomy - represents the prototype of the classical conservative gynecological surgery that is recommended to young women up to the age of 40; myometrectomy). Conservative therapy may also be considered to be myolysis or coagulation of fibromyomas by hysteroscopy or laparoscopic surgery performed with the Nd: YAG laser or bipolar needle.(16)

An alternative to classical surgery is the of the *Uterine Artery Embolization (UAE),* a technique with an efficiency of over 85% in terms of dominant symptoms: pain and haemorrhage. It is not yet known whether the fertility of the woman is affected later. Reduction in fibromyoma volume occurs in 39-69% of cases. Embolization is generally cheaper than abdominal myomectomy, although the process itself is somewhat more expensive, but hospitalization is shorter. It is a primary or adjunctive therapy to surgery.(17)

The medical treatment of uterine leiomyomas represents an adjunctive and transient therapeutic measure aimed at achieving spontaneous menopause or the optimal moment for surgery.(18) For this reason, it is only symptomatic. The basis of medical treatment is hormone therapy with synthesis progestatives, and more recently with gonadotropin releasing hormone (GnRH) agonists. Additionally, hemostatic medication, antifibrinolytic medication is also prescribed.

Other therapeutic methods: laparoscopic bipolar clotting of uterine arteries (in this case, leiomyoma necrosis is usually of the hyaline type followed by secondary amenorrhea), high intensity focused ultrasound fibromyoma necrosis, intrauterine levonorgestrel devices.

Conservative treatment of uterine fibroid by Uterine Artery Embolization (UAE)

Definition

Embolization of the uterine artery is a safe and effective miniinvasive method that provides permanent infarction of the tumour tissue without its subsequent relapse, followed by a significant improvement in symptomatology with rapid socio-professional reintegration.

History

Embolization of the Uterine Artery (UAE) in the treatment of uterine fibroids was used among the first, by Ravina, in 1991, with the aim to reduce intraoperative bleeding during hysterectomy or myomectomy. In some situations where this embolization was performed days-weeks before surgery, the patients reported a significant improvement in symptomatology, and on ultrasound, it was found a reduction in the size of the fibroids, which even led to the cancellation of the scheduled surgery, and of course, to amplifying research efforts on embolization of the uterine artery as a direct method for uterine fibroid treatment.

MATERIALS AND METHODS

The personal study is conducted under the form of a retrospective epidemiological analysis, combined with an eight-year clinical study (2002-2009), where UAE was practiced at the Obstetrics and Gynecology Clinic of the Bucharest Emergency University Hospital.

In order to perform this clinical and statistical study, I used as working material, the observation sheets of the clinic archives, the surgery protocols, the admission registers and the data provided by the clinic's statistical office.

To complete the statistical survey, the following steps were taken:

- collecting, processing and centralizing data;
- analysis compared to indices in other statistics;
- case presentations.

The first stage of the clinical trial consisted in the selection of the working material, represented by a sample of 14 cases diagnosed with uterine leiomyoma, in which arterial embolization was practiced.

Based on the patients' selection protocol, the following eligibility criteria were established (19), indications:

1. Young patients with multiple fibromas who want to have children (for whom hysterectomy is not an alternative),
   - allows simultaneous therapy of all fibroids,
   - preserves the reproductive function of the uterus.
2. Symptomatic uterine fibroids
   - refusal of hysterectomy,
   - the refusal of blood transfusion,
   - refusal/contraindication of general anesthesia.
3. Patients nearing menopause
   - much less aggressive intervention than hysterectomy,
   - cheaper compared to hormone therapy.
4. UAE indications by size, number and location of fibroids (figure no. 1)
   - Irrespective of size
     - large embolized fibroids require more careful follow-up to avoid any possible overinfection of necrotic structures,
     - embolization + segmental myomectomy for very large fibroids.
   - Number
     - by embolization, all existing fibroids are simultaneously devascularized, even those of small size, undetected by imagining methods.
   - Localisation (figure no. 1)
     - the most indicated are intramural or submucosal well-vascularized fibroids
     - subserosal, pedunculated fibroids are not considered ideal for embolization.(20,21) Embolization + segmental myomectomy are recommended.

Figure no.1. UAE indications according to location

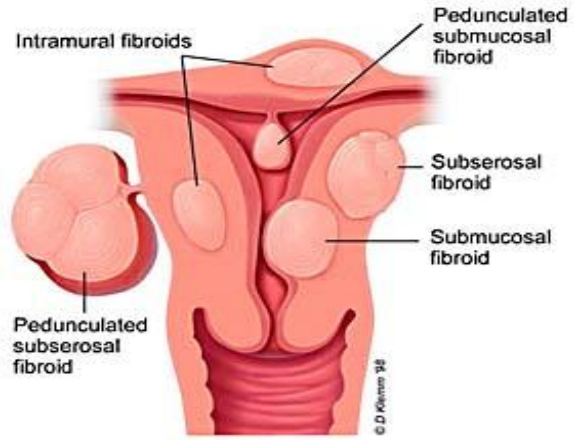

Embolization contraindications are the following: pregnancy, endometrial carcinoma, genital infections, rapid increase of leiomyoma, contrast medium intolerance etc. The effect on fertility is under evaluation. Taking into account the relatively new nature of the procedure (the first article on fibroids embolization was published in 1998 - Dr Jacques Ravina, there are no long-term comprehensive studies.)

However, medium-term studies seem to indicate a favourable outcome.

Surgical technique

Arteriography is an invasive method involving arterial puncture and the introduction of a catheter up to the vascular segment to be investigated, followed by injection of the contrast medium.(22)

The bilateral femoral approach was used by the Seldinger technique, with double crossing over, which reduces the intervention time and therefore, the accumulated radiation dose, but it increases the risk of local complications.

After the catheter is positioned in the blood vessel of interest and the retraction of the guide, an iodine contrast substance is injected through the lumen of the catheter; in this case, Iopamiro 300 was used. Simultaneously, the respective territory is covered by an X-beam that is captured and recorded in dynamics by an image acquisition device. The obtained images reveal the vascular lumen anatomy as well as the dynamics of blood flow in that territory.(23,24)

Through crossing over, the catheter is passing the bifurcation of the aorta in the other common iliac, the internal iliac, and from this one into the uterine artery, where it either advances distally as close as possible to the arteries irrigating the fibroma, either it is positioned proximally (in this case, the method is called free flow embolization), and fine particles of Tachocomb of 1 mm, PVA (polyvinyl alcohol) of 150-300 μ or 300-500 μ or 5 mm gel platelets are injected.(25)

Postprocedure care

The patient requires maximum 3 days of hospitalization with symptomatic treatment, nonsteroidal anti-inflammatory drugs (NSAIDs), antiemetics, antibiotics. In some cases, pain at the level of tumour formation can occur (due to devascularisation), that can be treated by antialgic medication. In 10% to 40% of cases, the so-called post-embolization syndrome is described, characterized by: - presence of pelviabdominal pain with a bimodal distribution at 6-12 hours caused by uterine ischaemia and 3-5 days after the intervention; headaches, nausea, vomiting, subfebrilities, leukocytosis. If fever does not cede within 24-36 hours, hysteroscopy and curettage are required.

CASE REPORTS

Next, I will present 3 cases from the group of the 14 selected patients in whom the conservative mini-invasive intervention by arterial embolization was practiced.

Case 1: Embolization followed by myomectomy

Patient, M.G., aged 20, coming from the rural area, virgo intacta, is hospitalized in the Obstetrics and Gynecology Clinic of Bucharest Emergency University Hospital with the diagnosis of pelvic-abdominal tumour.

Anamnesis reveals abundant and painful menorrhagiaa, frequent urinations, intra-abdominal pressure.

Clinical gynecological consultation indicates the presence of a large, ovoid formation (about 8cm in diameter), tumour-shaped form at peviabdominal level.

The pelvic ultrasound reveals the uterine affiliation of the tumour and provides data in favour of its benign character suggesting the diagnosis of uterine leiomyoma.

Laboratory analyses performed were within physiological limits except for the blood count that revealed the presence of moderate anemia (Hb = 9g/dl) that was attributed to the presence of abundant metrorrhages. A magnetic resonance (MRI) examination was performed to confirm the diagnosis and establish the therapeutic response. This test showed the presence of a unique 8/8 cm fibromatous nodule, developed intramurally on the anterior wall of the uterus.

The usual therapeutic conduct for large fibroids is total hysterectomy. Myomectomy is not approved due to significant bleeding with uncontrollable potential.

The patient being young (20 years) and virgo intact, a therapeutic alternative to hysterectomy was sought in order to preserve the reproductive function of the patient.

Pelvic arteriography was decided and practiced that highlighted a large, pelviabdominal highly vascularized tumour of the left uterine artery (figure no. 2).

Under these conditions, the chosen therapeutic conduct was that of the supraselective embolization of the fibroma-supply blood vessels followed by segmental myomectomy.

Figure no. 2. Selective arteriography of the left uterine artery - richly vascularized large uterine fibroid

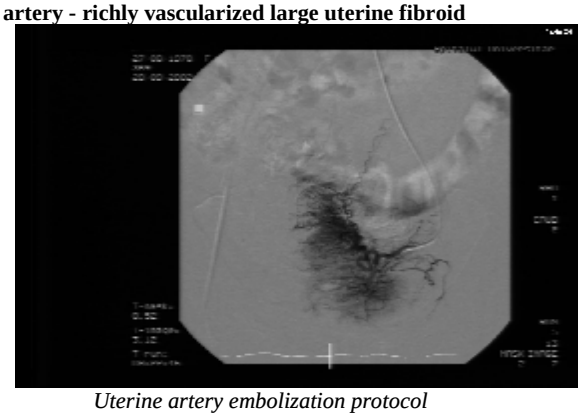

Uterine artery embolization protocol

The procedure began by puncturing the right external femoral artery, immediately below the inguinal ligament using the Seldinger technique, followed by mounting an 11 cm long 5F arterial sheath. A 5F arterial Cobra-I type catheter with a 0.035-inch Terumo hydrophilic guide was inserted through the sheath into the right common iliac artery.

Then, through the “crossover” technique, the catheter crosses the aorta bifurcation and descends into the left common iliac artery. Catheterization is continued by directing the probe into the left internal iliac artery and from this one, into the left uterine artery (figure no. 3A).

After placement of the probe as near to the branches of the uterine artery that supply the fibroid, fragments less than 1 mm of Tachocomb were injected through the catheter (figure no. 3B).

These particles have completely disrupted the blood flow at tumour level.

The contrast agent used was Iopamiro-300 in 75 ml.

Figure no. 3. Selective arteriography of the left uterine artery (A) followed by injection of Tachocomb (B)

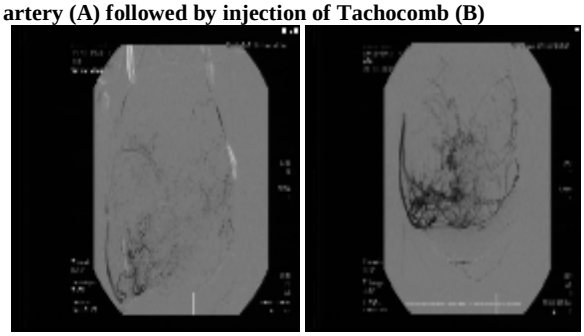

The intervention resulted in the quasitotal reduction of blood flow in the fibrous nodule (figure no. 4).

Figure no. 4. Selective arteriography of the left uterine artery postembolization

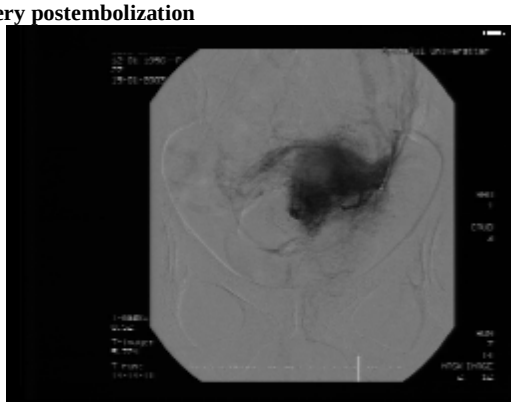

Immediately after the intervention, the patient complained about a slight pelvic pain that did not require analgesic medication and spontaneously ceased in about 90 minutes.

On the first day after embolization, surgery was decided and practiced, which consisted of myomectomy and drainage. In this case, it was a median pubo-subombilical incision. A fibromatous nodule with a size of 80/90 mm was extracted under minimal bleeding conditions. The histopathological extemporaneous result indicated an edematous transformed leiomyofibroma. The postoperative progression of the patient was favourable without complications.

Case 2: Uterine fibroid expelled postembolization

23-year-old, nuligest, nuliparous, 90mm single uterine fibroid, located intramurally, with development into the uterine cavity.

The patient required conservative therapy, so in November 2003, she benefited from right uterine artery embolization, the left uterine artery is not embolized due to the supply of the left ovary thereof.

In February 2004, initially after an initial reduction of 10mm, the fibroid continued to increase to 94/87mm, reason for which left uterine artery embolization was decided and practiced, but protecting the utero-ovarian communicating branch (figure no. 5).

Figure no. 5. Right uterine artery embolization

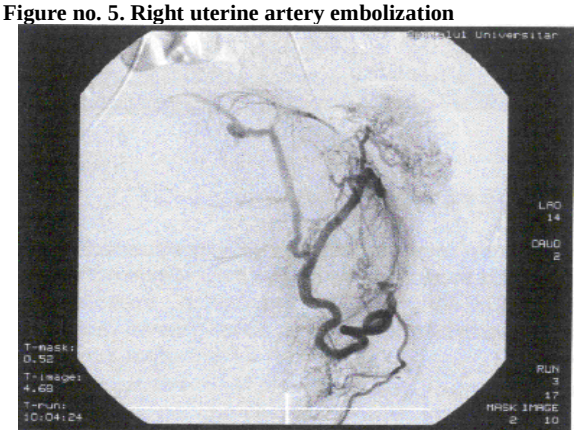

At 7 days postembolization (the second), the necrobiosed fibromatous nodule was embedded in the cervix (figure no. 6) and the fibroma expulsion was performed by torsion of the pedicle.

On April 2004, clinical and ultrasound assessment was made: no clinical complaints, and the imagining investigations (hysteroscopy and ultrasound) had normal appearance.

Figure no. 6. Uterine fibroids expulsion after embolization

Case 3: Embolization and pregnancy

A 26-year-old nuligest woman with fibromatous uterus, a 90 mm subserosal fibromatous nodule, came to our service for infertility.

In March 2004, embolization with Tachocomb was performed, and in January 2005, she had a 3100-g live birth via Caesarean section.

DISCUSSIONS

Uterine artery embolization comes as an alternative to conservative surgical treatments, such as myomectomy and myometrectomy, or as an alternative to much more expensive Gn-RH analogue therapy. Uterine artery embolization can be used in preoperative treatment for total hysterectomy in order to reduce the volume of uterine fibroids, reduce bleeding, thus facilitating surgery.

In this study, the majority of women who opt for the embolization of the uterine arteries fall within the age range of 20-35 years, age range specific to women who wish to experience pregnancy and preserve menstrual function. The degree of parity is another important criterion in choosing uterine artery embolization as a therapeutic method. The highest incidence was noted in nuligest patients, respectively 8 cases out of a total of 14, which could suggest that uterine fibroma is a possible cause of sterility.

From the clinical point of view, the most commonly symptom reported in patients in the study group was bleeding (menometrorrhagia), followed by dysmenorrhea; other symptoms present at admission were those caused by compressions of uterine leiomyoma on adjacent organs: urinary bladder (frequent micturition), rectum (constipation).

The clinical-anatomical form with the highest frequency of occurrence in the studied group was the intramural leiomyoma in 8 patients out of the total of 14. After embolization of the uterine arteries, the conditions for conservative intervention - i.e. myomectomy improved, which was performed in 4 cases from the studied group.

In 3 cases, transvaginal expulsion of necrobiosed fibrosis was reported, the extraction of which was done by torsion of the pedicle, and in one case with uterine fibromatosis, spontaneous expulsion of a single fibromatous nodule was recorded. Embolization of the uterine arteries was applied in the case of massive uterine haemorrhage occurring three days postpartum, resulting in its immediate stopping, along with gradual and significant resorption of uterine fibroma, with no need for further surgery. The use of uterine embolization to preserve the fertile function is documented in our study by reporting an uncomplicated pregnancy following this intervention.

Positive diagnosis was based on anamnesis, clinical examination, ultrasound examination, all representing the compulsory preoperative investigation protocol along with haematological tests, ECG, kidney tests, urine tests, coagulation tests, pulmonary radiography. As an alternative (more expensive) we mention nuclear imaging, more sensitive than the standard ultrasonography.

Uterine fibromyoma therapy by combining both methods, uterine artery embolization and myomectomy, appears to be an effective, conservative, therapeutic method, less aggressive compared to hysterectomy and also, relatively inexpensive.

The small size of the studied group makes it statistically less significant than the ones mentioned in the literature, but larger studies will be carried out based on this one in the future.

CONCLUSIONS

Embolization of uterine arteries is a safe and effective method of uterine fibroids therapy. The method allows the preservation of intact internal genital organs and even fertility, thus avoiding the possible complications (physical, mental, need for a transfusion) of hysterectomy.

In cases where surgery is contraindicated or refused by the patient, embolization of the uterine arteries alone is an effective method of therapy of uterine fibroma, with very good results reported in the literature and highlighted in this study.

Functional gynecological surgery implemented in the case of uterine fibroids is an important element in the readaptation of female genital apparatus after the conservative intervention and of the repercussions of surgery on the physiology and psychology of women.

Following conservative surgery or by embolization of uterine arteries, the quality of life of women is fully preserved with normal genital functions, hormonal and biological balance being fully preserved.

REFERENCES

1. Gao Z, Matsuo H, Nakago S. p53: Tumor suppressor protein content in human uterine leiomyomas and its down-regulation by 17 beta-estradiol. J Clin Metab. 2002; Aug;87(8):3915-20.
2. Cramer DW. Epidemilogy of myomas. Sem Reprod Endocrinol. 1992;10(4):320-4.
3. Vedantham S, Goodwin SC, McLucas B. Uterine artery embolization for fibroids: considerations in patient selection and clinical follow-up. Medscape Women's Health. 1999;4(5).
4. Pelage JP, Le Dref O, Soyer P. Fibroid-related menorrhagia: treatment with superselective embolization of the uterine arteries and midterm follow-up. Radiology. 2000 May;215(2):428-31.
5. Ravina JH, Aymard A, Ciraru-Vigneron N. Arterial embolization of uterine myoma: results apropos of 286 cases. J Gynecol Obstet Biol Reprod (Paris). 2000 May; 29(3):272-5(Medline).
6. Ravina JH, Bournet JM, Fried D. et al. Value of preoperative embolization of uterine fibroma: Report of a multicenter series of 31 cases. Contracept Fertil Sex. 1995;23:45-49.
7. Ravina JH, Herbreteanu D, Ciraru-Vigneron N. Arterial embolization to treat uterine myomata. Lancet. 1995 Sept 9;346(8976):671-2(Medline).
8. Moghissi SK. A clinician's guide to the use of Gonadotropin-Releasing Hormone Analogues in women. Medscape Women's Health. 2000;5(1).
9. Pedeutour F, Ligon AH, Morton CC genetics of uterine leiomyomata. Bull cancer. 1999 Nov;86(11):920-8.
10. Van Voorhis BJ, Romitti PA, Jones MP. Family history as a risk factor for development of uterine leiomyomas. Results of a pilot study. J Reprod Med. 2002 Aug;47(8):663-9.
11. Ligon AH, Morton CC. Genetics of uterine leiomyomata. Genes Chromosomes Cancer. 2000 Jul;28(3):235-45.
12. Barbieri RL, Andersen J. Uterine leiomyomas: The somatic mutation theory. Sem Reprod Endocrinol. 1992;10(4):301-9.
13. Orsini G, Laricchia L, Fanelli M. Low-dose combination oral contraceptives use in women with uterine leiomyomas. Minerva Ginecol. 2002 Jun;54(3):253-61.
14. Rossoshansky AR. Starea sistemului cardiovascular la pacientele cu miom uterin înainte şi după tratament operator, Akush. I Ghinek. 1969;8:69-71.
15. Luoto R, Rutanen EM, Auvinen A. Fibroids and hypertension. A cross-selectional study of women undergoing hysterectomz. J Reprod Med. 2001 Apr;46(4):359-64.
16. Goldfarb HA. Myoma coagulation (myolysis). Obstet. Gynecol. Clin. North Am. 2000 Jun;27(2):421-30.
17. Baker CM, Winkel CA, Subramanian S. Estimated costs for uterine artery embolization and abdominal myomectomy for uterine leiomyomata: a comparative study at a single institution. J Vasc Interv Radiol. 2002 Dec;13(12):1207-10.
18. Reidy JF, Bradley EA. Uterine artery embolization for fibroid disease. Cardiovasc. Intervent. Radiol. 1998 Sep-Oct;21(5):357-60 (Medline).
19. Goodwin SC, McLucas B, Lee M. Uterine artery embolization for the treatment of uterine leiomyomata midterm results. J Vasc Interv Radiol. 1999 Oct.;10(9):1159-6.
20. Ravina JH, Aymard N, Ciraru-Vigneron, Bouret JM. Embolisation arterielle perticulaire: un nouveau traitment des hemorragies de leiomyomes uterins. La Presse Medicale. 1998;21(7):299-303.
21. Ravina JH, Aymard A, Ciraru N, Ciraru-Vigneron, Ledreff O, Clerissi J, Herbreteanu D, Merland JJ. Arterial embolization of uterine fibroids, Clinique Spontini, Paris
22. Hutchins FL. Jr., Worthington-Kirsch R, Berkowitz RP. Selective uterine artery embolization as primary treatment for symptomatic leiomyomata uteri. J Am Assoc Gynecol. Laparosc. 1999 Aug; 6(3):279-84.
23. Mc Lucas B, Goodwin S, Adler L, Rappaport A, Reed, Perrella R. Pregnancy following uterine fibroid embolizatio. International Journal of Gynecology and Obstetrics September. 2001;74(1).
24. Badescu T, Costin N. Managmentul medicamentos al fibromiomului uterin, Revista Acta Medica Transilvanica. 2007;2(4):79-81.
25. Badescu T, Costin N. Fibromiomul uterin voluminos la o femeie tânără, Revista Acta Medica Transilvanica. 2009;2(4):82-83.