THE EVALUATION OF HIP JOINT SPACE IN CLINICALLY NORMAL HIPS AS AN INDICATOR OF EARLY OSTEOARTHRITIS

ANCA MARIA POP[1], CRISTIAN TRÂMBIȚAȘ[2], TUDOR SORIN POP[3]

[1,2,3]*University of Medicine and Pharmacy Tîrgu-Mureș*

Keywords: *hip joint, osteoarthritis, joint space width*

Abstract: *Osteoarthritis is a main reason of pain in elderly, the joint space width being the most used criteria in the assessment of the hip joint articular cartilage thickness. The aim of our study was to measure a set of parameters on clinically asymptomatic patients with normal radiographic aspect of hips and to compare the results with the joint space width. The recorded parameters were: gender, age, center-edge angle of Wiberg, neck-shaft angle and acetabular depth. The Wiberg angle was inversely associated with the joint space width and the mean acetabular depth was 12.5 mm, positively associated with the superomedial joint space width. A head-neck ratio of 1.35 and neck-shaft angle were not correlated with the joint space width values. The Wiberg angle can be considered a radiological parameter inversely related to the joint space width of the hip joints. We found no association between aging and hip joint space narrowing.*

INTRODUCTION

Radiographic description of the normal variations of the hip joint space, regarding its shape and width at precise locations, is extremely important in setting the limits of early radiographic alterations in patients with osteoarthritis (OA). This condition has been defined by the American College of Rheumatology as a painful condition accompanied by at least two of the following criteria: presence of osteophyte, joint space narrowing (JSN) and sedimentation rate less than 20mm/1st hour. The joint space width (JSW) of the hip is normally used for the assessment of the articular cartilage thickness, as OA is always accompanied by its narrowing. It is still unclear whether in the hip joint this could be a consequence of aging as it is known to be in the case of the knee joint space.(1,2) Compared with the knee, the hip JSW has received limited attention, even though it offers a more direct measurement of the cartilage thickness. Furthermore, a substantial amount of radiographic JSW of the knee is related to other factors than cartilage thickness, as meniscal damage, extrusion or variability in patient positioning. By contrast, the hip joint has no menisci and the positioning of the patient is standardized, allowing a better follow-up evaluation.(3) Many epidemiological studies considered JSN as the major radiographic feature of early OA and the threshold value of the joint space was considered to range from <4mm to <1,5mm but the commonly accepted value is a reduction of less than 2,5mm.(4,5) As there were no normal accepted values defined in the scientific literature, the joint space width of interest was usually compared with that measured on the contralateral hip, considered to be normal. The most important radiological parameters used to predict the development of OA in a dysplastic hip are the depth of less 9 mm in the acetabulum and a center-edge angle of Wiberg less than 25^0. Each extreme value of the neck shaft angle and a decreased femoral head to femoral shaft ratio are also indicators for developing OA.(6,7) The correlation of these measurements with the JSW values recorded in normal hips could offer important data upon the differences between healthy and osteoarthritic hips.

PURPOSE

The aim of our study is to measure a set of parameters on clinically asymptomatic patients with normal radiographic aspect of hips and to compare the results with the joint space width.

MATERIALS AND METHODS

A total of 128 consecutive patients without clinical signs of OA who underwent a routine pelvic radiograph for hip contusion or health control, in a time interval from 2010 to 2015, were included in this study. Our study was carried out after the approval from the Ethics Committee of our university, in accordance to the standards of Helsinki Declaration of 2002. As exclusion criteria we considered to be neuromuscular disorders, other congenital anomalies or a Kellgren-Lawrence score over 2. All the radiographs were interpreted by the same observer in a single blind manner and all measurements were done on the right hip. On conventional anteroposterior radiographs performed with the patient in the supine position (with the hips extended and 15^0 internal rotation) the following parameters were recorded: gender, age, center-edge angle of Wiberg, neck-shaft angle and acetabular depth. We used the same methodology as Lequesne et al in 2004.(2) The joint space width was defined as the area between the acetabular roof and the part of the femoral head on the opposite site. The roof limits were set at the lateral extremity of the condensed subchondral bone and the junction roof-acetabular fossa line, medially. The JSW was measured in the upper, weight-bearing part of the joint and the shortest distance between the acetabulum and the femoral head was recorded in three points: the medial and lateral margins of the subchondral sclerotic line and along the vertical line through the center of the femoral head. The Wiberg's angle is formed between a vertical line drawn through the center of the femoral head and a line that passes through this latter point and the lateral brim of the acetabular roof. It measures the lateral covering of the femoral head by the acetabular roof: in congenital dysplasia it is less than 20^0 and in coxa profunda is over 40^0. The neck shaft angle is formed by the neck axis and

[2]Corresponding author: Cristian Trâmbițaș, Str. Gh. Marinescu, Nr. 38, Tîrgu-Mureș, E-mail:c_trambitas@yahoo.com, Phone: +40745 615 113
Article received on 06.01.2018 and accepted for publication on 28.02.2018
ACTA MEDICA TRANSILVANICA March 2018;23(1):67-69

the axis of the femoral diaphysis; in coxa valga it is over 140^0. The acetabular depth is measured from the deepest point of the acetabulum to a line that crosses from the lateral extremity of the acetabular roof to the superior pubic angle; in dysplastic hips this distance measures less than 9 mm. The radiographs were digitized using Picture Archiving Communication System Software which enables measurements with an accuracy of 0.01 mm and 0.010.

Statistical analysis was carried out using SPSS for Windows (version 11), in order to evaluate the relationship between all measured parameters. Mean and standard deviations were calculated.

RESULTS

We evaluated 128 patients (72 women and 56 men) with a mean age of 53.4 years (range between 23.2-79.6 years old). On each radiograph, a set of angles and parameters were measured by the same evaluator in order to eliminate the inter-observer differences (figures no.1, 2).

Figure no. 1. Representation of the recorded radiological parameters (E- lateral brim of acetabular roof, V- line through the center of the femoral head, T- medial extremity of the acetabular roof, C- center of the femoral head, C1- axis of the femoral neck, D- axis of the femoral dyaphisis)

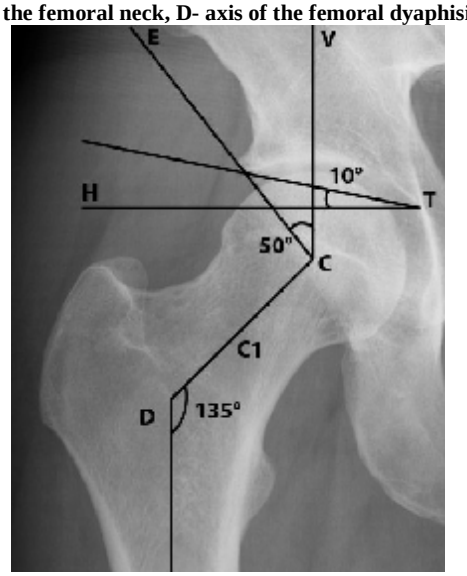

Figure no. 2. The measurement of the acetabular depth (ad)

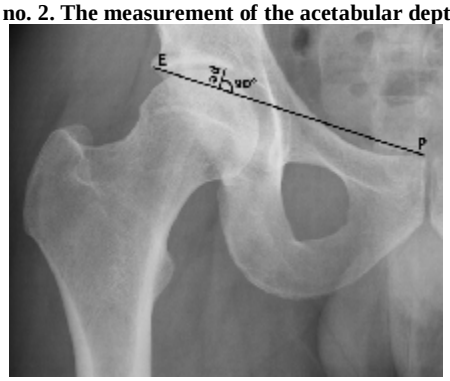

The first evaluation was the Kellgren-Lawrence scoring which was considered to be 0 for 92 hips (71.8%), 1 for 36 hips (28.2%). The measurement of JSW at the superolateral and superomedial areas ranged between 1,6-8,2 mm (mean 4,8 +/- 0.92) and 2,5-8,4 mm(mean 4.67 +/- 1.03) respectively. The mean Wiberg angle was 38.1+/-5.4 (range 20.5-62.0) degrees and the mean acetabular depth was 12.5+/-2.6 (range between 4.5-20.5) mm. Three hips (2.3%) had a center-edge angle less than 25^0 and nine hips (7%) had an acetabular depth of less than 9 mm. The head-neck ratio had a mean value of 1.35+/- 0.14 (range 1.2-2.0) and for the neck-shaft angle a mean value of 128.5+/-5.2 degrees (range 119^0-145^0) had been measured (table no. 1).

Table no. 1. Description of the radiological parameters measured for the study group

Parameter	Mean +/- Standard Deviation	Range
Age	53.4 +/- 18.5 years	23.2 – 79.6 years
Wiberg angle	38.1 º +/- 5.4 º	20.5 º - 62.0 º
Acetabular depth	12.5 +/- 2.6 mm	4.5 – 20.5 mm
Neck-head ratio	1.35 +/- 0.14	1.2 – 1.8
Neck-shaft angle	128.5 º +/- 5.2º	119 º - 145 º

DISCUSSIONS

Due to the differences between the presence of pain and the radiographic alterations characteristic for OA, many epidemiological studies defined this condition as a combination of clinical and radiological parameters.(1,2,5) The American College of Rheumatology developed a set of criteria in order to define and standardize symptomatic hip, knee and hand OA, based on joint symptoms and positive radiography. The Kellgren-Lawrence system is based on the presence and severity of radiographs features as joint space narrowing, osteophytes, subchondral cysts and joint line sclerosis have been considered the radiographic standard for several decades.(4)

The results of our study showed that 71.8% of patients had a Kellgren-Lawrence score of 0 which corresponds to normal radiographic aspect of the hip joint. We observed that the Wiberg angle was inversely correlated to the JSW in clinically healthy patients in both superolateral and superomedial areas, which is in accordance with the results of other studies.(1,2) Altered values of the head-neck ratio and neck-shaft angle are considered to represent risk factors for developing OA but based on the results of our study we found no correlation between these parameters and the joint space width. Hip OA is less common in the aging population compared to knee OA but a systematic review upon the prevalence of primary hip OA conducted by Dagenais et al (2009) showed a tendency towards increasing prevalence with age, reporting variations from 0.7% in the 40-44 years of age group to 14% in the group of patients aged over 85 years (8). Arden et al (2009) measured the prevalence and incidence of hip OA in women over 65 years of age, followed-up at least 8 years and obtained an increasing prevalence from 1.8% to 9.4% and an incidence from 3.6% to 8.9% from baseline to the last control respectively.(9)

Age-related oxidative stress and damage is thought to play a role in OA but until now the antioxidant therapies have not been well tested and documented.(10) The minimum JWS can be manually measured or using computer assistance but in both cases the location of this parameter is time consuming, subjective, susceptible to structural damage that can confound joint margins detection, inconsistent measurements in different points on serial radiographs, leading to measurement errors. Therefore, a reliable, efficient and responsive computer-based method to evaluate the hip JSW could be a significant advance in studies carried out in large cohort studies.(11-13) Advances in the study of osteoarthritis have been hampered by the lack of visual information upon important structural changes that have

been taken place in the hip joint. The radiographic examination considered the gold standard diagnostic method is limited, as it gives a 2-dimensional image of the whole joint.(14) Therefore, new perspectives are represented by 3-dimensional measurements of the hip joint space, obtained from computer tomography imaging systems, with great impact for the assessment and prediction of osteoarthritis.

The joint space mapping represents a new analysis method that offers accurate measurements of the hip joint space and subsequently builds a 3-dimensional model of the whole hip joint.(15,16) Much of recent research work focused on aging changes in the articular cartilage but clinical data based on Magnetic Resonance Imaging suggested that aging modifications that could play an important role in the pathogenesis of OA are also found in other structures as bone and ligaments. Therefore, further work is needed for understanding the biological mechanisms of aging in the joint tissues affected by OA. This could contribute to the development of new therapies in order to prevent or slow the development and progression of OA.

CONCLUSIONS

The results of our study showed that the center-edge angle of Wiberg was inversely related to the joint space width of the examined hips. Older age is considered to be the greatest risk factor for OA in susceptible joints but this disease is not an inevitable consequence of growing old.

Radiographic changes characteristic to OA especially osteophytes are common in older patients but the symptoms of joint pain can be independent of the radiographic aspect.

REFERENCES

1. Goker B, Sancak A, Aral M, Shott S, Block JA. The radiographic joint space width in clinically normal hips: effects of age, gender and physical parameters. Osteoarthritis Cartilage. 2003;11:328-334.
2. Lequesne M, Malghem J, Dion E. The normal hip joint space: variations in width, shape and architecture on 223 pelvic radiographs. Ann Rheum Dis. 2004;63:1145-1151.
3. Courozier T, Lequesne M, Favret H, Taccoen A, Mazieres B, Vignon M et al. Measurement of the radiological hip joint space width. An evaluation of various methods of measurement. Osteoarthritis Cartilage. 2001;9(3):281-286.
4. Altman R, Alarcon G, Appelrouth D, Bloch D, Borenstein D, Brandt K. The American College of Rheumatology criteria for the classification and reporting osteoarthritis of the hip. Arthritis Rheum. 1991;34:505-514.
5. Lanyon P, Muir K, Doherty S, Doherty M. Age and sex differences in hip joint space among asymptomatic subjects without structural change: implications for epidemiological studies. Arthritis Rheum. 2003;1041:1046.
6. Doherty M, Courtney P, Doherty S, Jenkins W, Maciewicz RA, Muir K. Nonspherical femoral head shape (pistol grip deformity), neck shaft angle and risk of hip osteoarthrosis: a case-control study. Arthritis Rheum. 2008;58:3172-3182.
7. Im GI, Kim JY. Radiological joint space width in the clinically normal hips of a Korean population. Osteoarthritis and Cartilage. 2010;18(1):61-64.
8. Dagenais S, Garbedian S, Wai EK. Systematic review of the prevalence of radiographic primary hip osteoarthritis. Clinical orthopaedics and related research. 2009;60:1052-1059.
9. Arden NL, Lane NE, Parini N, Javaid KM, Lui LY, Hochberg MC. Defining incident radiographic hip osteoarthritis for epidemiologic studies in women. Arthritis Rheum. 2009;60(4):1052-1059.
10. Anderson SA, Loeser RF. Why is osteoarthritis an age related disease? Best Peract Res Clin Rheumatol. 2010;24(1):15-29.
11. Ratzlaff C, Van Wyngaarden C, Duryea J. Location-specific hip joint space width for progression of hip osteoarthritis- data from osteoarthritis initiative. Osteoarthritis Cartilage.2014;22(10):1481-1487.
12. Terjesen T, Gunderson RB. Radiographic evaluation of ostheoartritis of the hip. Acta Orthop. 2012;83(2):185-189.
13. Troelsen A, Romer L, Kring S, Elmengaard B, Soballe K. Assessment of hip dysplasia and ostheoarthritis: variability of different methods. Acta Radiol. 2010;51:187-193.
14. Turmezei T, Poole K, Treece G. Three-dimensional measurement of the hip joint space from clinical CT for the assessment and prediction of osteoarthritis. The Lancet. 2016, 387, S 101, doi: 10.1016/S 0140-6736.
15. Neumann G, Hunter D, Nervitt M, Chibnik LB, Kwoh K, Chen H, Harris T, Saterfield S, Duryea J. Location specific radiographic joint space width for osteoarthritis progression. Osteoarthritis and Cartilage. 2009;17(6):761-765.
16. Santiago RF, Chinchilla Santiago A, Ansari A et al. Imaging of hip pain: From radiography to cross-sectional imaging techniques. Radiology Research and Practice. 2016; Article ID 6369237.