COMPARISON OF RECTAL STUMP CLOSURE METHODS FOR MECHANICAL ANASTOMOSIS IN RECTAL CANCER

CORNEL DRAGOŞ CHEREGI[1], OVIDIU FABIAN[2], OVIDIU POP[3], ADRIAN MAGHIAR[4]

[1,2]Railway University Hospital, Cluj-Napoca, [3]Municipal Hospital, Oradea, [4]Pelican Hospital, Oradea

Keywords: *linear stapler, mechanical suture, rectal stump, lower rectal tumour, mechanical anastomosis*

Abstract: *Is mechanical suturing of the rectal stump safer than manual suturing for mechanical anastomosis in rectal cancer? Materials and methods: In order to answer this question, we conducted a prospective observational interventional study in 85 patients with rectal cancer, divided into two groups: group A, in which mechanical suturing of the rectal stump was performed (36 patients) and group B, which underwent manual enterorrhaphy (49 patients). Results: Linear staplers are used in lower rectal tumour resection in 69.44% of the patients. Their use reduces the operative time by 15 minutes ± 4 minutes and eliminates the septic time. At 12 months postoperatively, these patients recover a normal lifestyle: 2 stools/day (75%), defecation delayed by 45 minutes (63.89%), and complete gas continence (80.56%). Conclusion: Mechanical suturing of the rectal stump is safe for the patient by saving the sphincter and improving quality of life.*

INTRODUCTION

Colorectal cancer is the most frequent digestive tumour, being the third cause of death from cancer, despite early diagnosis and therapeutic progress made over the past years. The standard treatment in these patients consists of preserving the anal sphincter with the restoration of intestinal function by colorectal or coloanal anastomosis and maintaining genitourinary function by preservation of hypogastric nerves.

Using surgical staplers for mechanical colorectal or coloanal anastomosis, in the preparation of the rectal stump after rectal tumour resection has proved to be safe for both surgeons and patients, by preserving the anal sphincter and consequently, contributing to the improvement of quality of life post-surgery. However, the efficacy of these medical devices should be compared to that of the conventional manual suturing technique because their high cost plays an important role in the treatment plan of these patients. The result of such a comparative study can help the surgeon to counsel patients in this regard.

MATERIALS AND METHODS

The rectum, previously freed and pulled up into the abdomen, maintained in slight tension in vertical position, allows to establish the optimal level at which it will be transected. This level should be chosen so that the residual stump is sufficiently supplied by the inferior hemorrhoidal (rectal) arteries preserved at and below the level of the anal levators, as well as by the inferior branches of the middle hemorrhoidal (rectal) artery.

Low anterior rectal resection with complete mesorectal excision is indicated in malignant middle and lower rectal ampullary tumours. Regarding upper rectal ampullary and rectosigmoid junction tumours, anterior rectal resection is associated with partial mesorectal excision by distal mesorectal transection at least 5 cm from the tumor lesion.(1,2)

The distal resection margin varies depending on the site of the lesion. A distal margin 2 cm from the lesion should be obtained. For distal rectal tumours, less than 5 cm from the anal margin, the minimum acceptable distal resection limit is 1 cm. Distal intramural spread beyond 1 cm is associated with aggressive behaviour or advanced stages of the tumour.

Table no. 1. Minimum acceptable proximal and distal resection margins

Resection margins	Proximal resection margin (cm)	Distal resection margin (cm)
Ideal margins	5 or > 5	2 or > 2
Minimum acceptable margins	2 or >2	1 or > 1

The preparation of the rectal stump for anastomosis by mechanical suture can be performed by manual enterorrhaphy or mechanically, using a linear stapler.

To begin with, two (or more) guiding threads are passed through the lateral margins of the rectum, below the level of the future rectal transection site; the role of these threads is to prevent retraction towards the bottom of the pelvic excavation of the rectal stump after rectal transection. A special clamp for mounting the purse string thread will be applied to the rectum and an L-shaped Satinscky-Iancu Jianu clamp will be placed caudal to this (figure no. 1). The rectum will be transected between the two clamps, after mounting the purse string thread. After rectal transection, the pelvic operative field will be washed with saline or betadine solution diluted to 1/10. This has the role to remove the possible tumour cells resulting from the manipulation of the rectum with the tumour; these cells can determine local recurrences.(2,3) A CEEA circular stapler will be introduced through the anal canal, and the rectal stump will be closed in a purse string fashion around its trocar (figure no. 1). The anvil of the circular stapler will be inserted into the transected end of the colon, and a purse with a 2.0 monofilament thread will be made around the shaft of the anvil. Anastomosis will be carried out by coupling the two portions of the stapler and by firing it (figure no. 2).(2)

The integrity of the two rings (from the two rectal and colonic segments) resulting from mechanical anastomosis will be verified. Anastomotic sealing can be controlled by "flooding"

[1]Corresponding author: Ovidiu Fabian, Spitalul Clinic CF, Clinica Chirurgie IV, Str. Republicii Nr. 14, Cod 400015 Cluj -Napoca, România, E-mail: fabianovidiu@yahoo.com, Phone: +40751 075525
Article received on 05.05.2018 and accepted for publication on 29.05.2018
ACTA MEDICA TRANSILVANICA June 2018;23(2):61-66

of the pelvis with betadine, followed by introduction of air through the anus.(2)

Figure no. 1. Application of a special clamp to mount the purse string thread on the rectum. Rectal transection between the purse clamp and the L-shaped clamp. Washing of the operative field, mounting of the transanal circular stapler with the closure of the rectal stump in a purse string fashion around its trocar

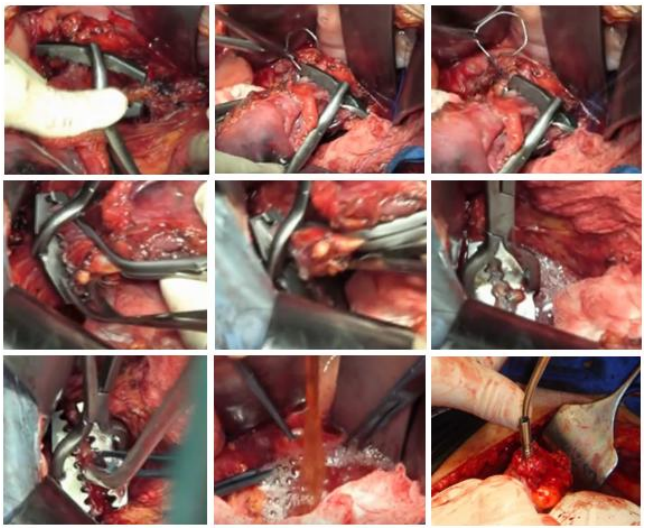

Figure no. 2. After the purses have been made, the two components of the stapler are coupled; mechanical end-to-end anastomosis after extraction of the circular stapler (4)

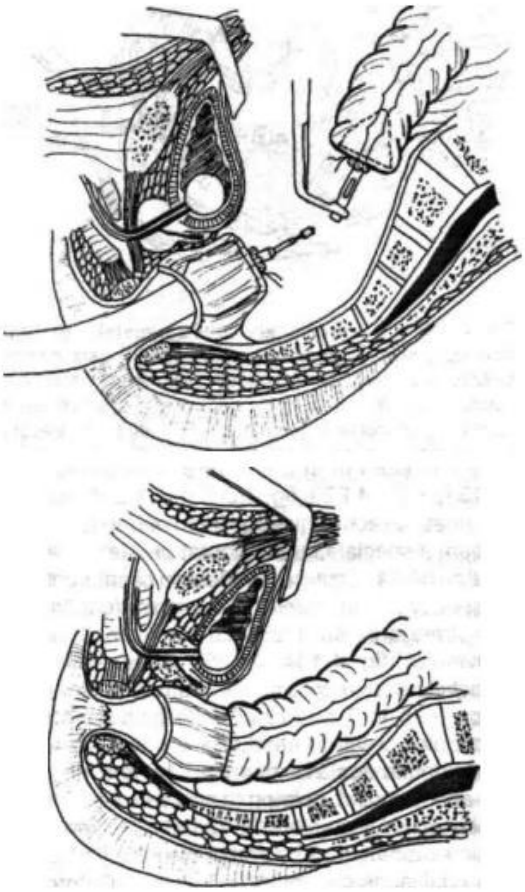

When mechanical suturing is intended, the L-shaped clamp is replaced with a *GIA linear stapler*. This is applied to the rectum, caudal to the two (or four) guiding latero-rectal suspension threads, with a role in preventing post-transection retraction of the rectal stump. Using a linear stapler, concomitant rectal transection and suture is performed, avoiding in this way the septic time of the opening of the rectal lumen (figure no. 3). The suture line of the residual rectal stump consecutive to the withdrawal of the stapler from the pelvis is controlled for hemostasis, which is also performed for the fat perirectal tissue transected at the same time with the rectal lumen. For the hemostasis of the (residual) caudal rectal transection-suture portion, it is recommended to apply a continuous suture with small stitches, using a 3-0 non-resorbable thread, with a mounted atraumatic needle. The rectal stump prepared in this way is ready for mechanical anastomosis that will be performed with the colon loop descended in the pelvis (figures no. 4,5). Mechanical anastomosis can be end-to-end or end-to-side on the anterior or posterior wall of the rectal stump. Some authors recommend avoiding transfixion of the suture line on the rectal stump with the mandrin of the stapler and performing anastomosis through it, i.e. strictly end-to-end anastomosis, because a subsequent (immediate or late) separation of the ends of the suture is possible, particularly in cases with a rectal stump diameter larger than that of the colon end to be anastomosed.(4)

Figure no. 3. Rectal transection-suture using a linear stapler

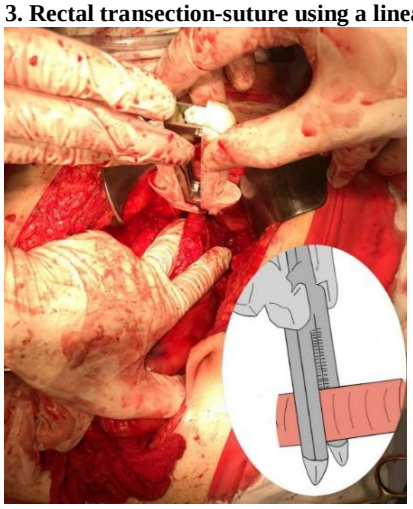

Figure no. 4. The anvil of the circular stapler is introduced into the colon end to be anastomosed under protection of a purse. The mandrin shaft of the stapler is driven transanally into the rectal stump

Figure no. 5. The perfect and complete coupling of the previously positioned components of the circular stapler favours the perfect joining of the colon and rectal ends for end-to-end anastomosis. Final appearance of mechanical end-to-end colorectal anastomosis

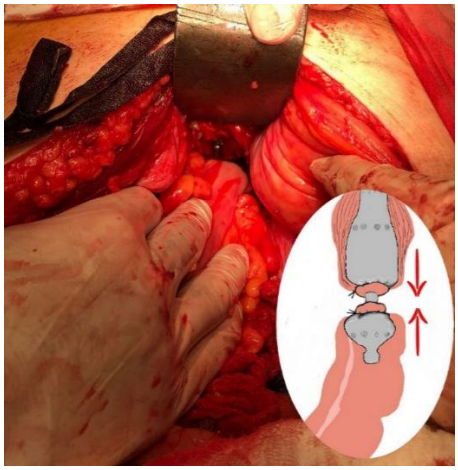

In order to protect low colorectal anastomosis (the middle and lower thirds), temporary lateral ileostomy about 30 cm from the ileocecal valve is performed.(5) Then, pelvic drainage with two tubes and abdominal wall closure in two anatomical planes are carried out.

To emphasize the importance of these rectal stump closure techniques with the aim of performing mechanical anastomosis in rectal cancer, we conducted a prospective observational interventional study over a 3 year period (2013-2016) at the Surgical Clinic IV of the CF Clinical Hospital Cluj-Napoca, in 85 patients admitted for rectal and rectosigmoid adenocarcinoma, with different disease stages, who underwent Dixon surgery. For transection and closure by mechanical suture of the rectal stump, we used a GIA linear stapler, and for mechanical anastomosis we used Covidien and Panther circular staplers. The patients were assigned to two groups: group A undergoing Dixon surgery with rectal stump closure by mechanical suture using a linear stapler (36 patients), and group B undergoing Dixon surgery with rectal stump closure by manual suture (49 patients). All patients underwent mechanical anastomosis. A number of parameters were monitored in the studied group: demographic data (age, sex), the type of suture, manual versus mechanical, the distance from the anal orifice at which rectal resection was performed, presence of temporary ileostomy, development of immediate and late postoperative complications, operative times, mortality, evaluation of intestinal fecal and gas transit at 3 and 12 months postoperatively.

All information was stored and processed with the Microsoft® Excel® 2010 software (Microsoft® Corporation, USA), representing the database of the statistical study.

The statistical analysis methods used were Fisher's exact test, Chi-square test, the comparison of means test (t-test) and the comparison of proportions test using the MedCalc® version 12.2.1.0 medical statistics software (MedCalc® Software, Mariakerke, Belgium). A p value < 0.05 shows a statistically significant difference between the studied groups.

The study was approved by the Ethics Committee and all patients were asked to fill in and sign an informed consent form.

RESULTS

The analysis of demographic data evidences a significantly increased incidence of the disease in male patients (57 male patients/28 female patients, p = 0.000015). Our study shows a significantly increased incidence of rectal and rectosigmoid adenocarcinoma in the fourth – eighth decades of life both in the entire group and comparatively between the two groups (p < 0.0001) (table no. 2).

Table no. 2. Demographic and therapeutic aspects of the patients included in the study

	Group A (n = 36)	**Group B (n = 49)**	***p*** †
Sex M/F	57/28		***p = 0.000015****
Men	22	35	p = 0.361837*
Women	14	14	
Age (years)			
20-40 years	2	2	***p* < *0.000001*** **
41-60 years	18	17	
61-80 years	16	30	
	p = 0.0001**	p < ***0.0001*** **	
Operative time	15 ± 4 minutes	30 ± 7 minutes	***p* < *0.0001***** **
Ileostomy	32 (88.89%)	19 (38.77%)	***p* = 0.000002***
No ileostomy	4 (11.11%)	30 (61.22%)	***p* = 0.000002***
Postoperative complications			
Low-flow fistula	4 (1 in the lower 1/3, 3 in the middle 1/3 of the rectum)	2 (lower 1/3 of the rectum)	p = 0.394016*
High-flow fistula	0	2 (middle 1/3 of the rectum)	p = 0.509222*
Fistula	4 (11.11%)	4 (8.16%)	p = 0.9328***
Parietal wound hematoma	2	1	p = 0.571368*
Abdominal wound seroma	0	1	p = 1.000000*
Wound suppuration	1	1	p = 1.000000*
Other complications			
Death from pulmonary embolism	0	1	p = 1.000000*
Intestinal adhesion obstruction	0	1	p = 1.000000*
No other complications	29	40	p = 1.000000*

**Fisher's exact test*
***Chi-square test*
****Comparison of proportions test*
*****Comparison of means test*
†p < 0.05 shows a statistically significant difference between the studied groups

In this study, we aimed to show the importance of using a linear stapler in low rectal tumour resection. Looking at the distance from the anal orifice at which tumour resection was performed in the entire group of patients, we found that in 54.11% of the patients, the tumour was located in the lower rectum. This evidences the importance of using a linear stapler in lower rectal resection, with a significant difference compared to the group undergoing manual resection (25 patients vs 21 patients, ***p* = 0.017143**) (table no. 3).

Table no. 3. The distance at which tumour resection was performed in relation to the anal orifice in the entire group of patients

Location of tumour resection	**Group A (n = 36)**	**Group B (n = 49)**	***p*** †
Lower 1/3 (4-7 cm from the AO)	25	21	***p* = 0.017143***
Middle 1/3 (8-10 cm from the AO)	6	14	p = 0.300837*
Upper 1/3 (11-20 cm from the AO)	5	14	***p* = 0.123216***

**Fisher's exact test*
†p < 0.05 shows a statistically significant difference between the studied groups

From the point of view of the operative time, there was a significant decrease by 15 minutes ± 4 minutes when resection was performed with a linear stapler compared to the

group of patients in which resection and stump closure were performed manually ($p < 0.0001$) (table no. 2). The advantage of using a linear stapler consists of obtaining a mechanical suture of the rectal stump and of eliminating the septic time given by the opening of the rectal lumen, as is the case in manual resection.

In order to protect colorectal anastomosis, temporary ileostomy was performed in the majority of the patients in which a linear stapler was used for resection and mechanical suture of the rectal stump compared to the other group of patients (88.89% vs. 38.77%, ***p*** **=** 0.000002) (table no. 2).

The rate of postoperative complications (low-flow fistula, high-flow fistula, parietal wound hematoma, abdominal wound seroma, wound suppuration) had no statistical significance between the groups (table no. 2).

Table no. 4. Incidence of anastomotic fistula depending on the surgical technique used

Anastomotic fistula	**Group A (n = 36)**	**Group B (n = 49)**	***p*** †
Lower 1/3 (4-7 cm from the AO)	1 (2.77%)	2 (4.08%)	P = 0.7860***
Middle 1/3 (8-10 cm from the AO)	3 (8.33%)	2 (4.08%)	P = 0.7215***

****Comparison of proportions test*

† $p < 0.05$ shows a statistically significant difference between the studied groups

The incidence of anastomotic fistula was present in patients undergoing rectal resection in the lower and middle 1/3, without a statistical difference between the two groups (table no. 4).

In terms of systemic complications, one patient in group B developed pulmonary embolism and died, and one patient had intestinal adhesion obstruction (table no. 2). No anastomotic stenosis or disease recurrences developed in the studied cases.

Intestinal transit recovery in the patients of the two groups was monitored and evaluated at 3 months and at 12 months postoperatively. Thus, three parameters were assessed: the number of stools in 24 hours, the delay of defecation and gas continence (table no. 5).

If at 3 months postoperatively, 44.44% of patients in group A had 3 stools per day compared to 22.45% of patients in group B ($p = 0.0554$), at one year, 75% of group A patients had 2 stools per day compared to 10.20% of group B patients ($p < 0.0001$). It was also observed that group B patients continued to have more than 3 stools per day at one year postoperatively in a proportion of 89.79%, with a statistically significant difference compared to group A patients, 25% ($p < 0.05$) (table no. 5).

Defecation could be delayed by 45' in 27.78% of group A patients at 3 months postoperatively and in 63.89% at 12 months postoperatively, with a significant difference compared to group B patients ($p < 0.05$) (table no. 5).

Regarding intestinal gas transit, group A patients had complete gas continence both at three months and at one year postoperatively, with a significant difference compared to group B patients ($p < 0.05$) (table no. 5).

Table no. 5. Distribution of patients depending on the number of stools per day

	Group A (n = 36)	**Group B (n = 49)**	**p** †
Number of stools/24 h			
3 months			
3 stools	16 (44.44%)	11 (22.45%)	**P = 0.0554*** **
4 stools	14 (38.89%)	24 (48.98%)	P = 0.4816***
≥ 5 stools	6 (16.67%)	14 (28.57%)	P = 0.3081***
12 months			
2 stools	27 (75%)	5 (10.20%)	**P < 0.0001*** **
3 stools	7 (19.44%)	29 (59.18%)	**P = 0.0006*** **
≥ 4 stools	2 (5.56%)	15 (30.61%)	**P = 0.0099*** **
Time by which defecation can be delayed			
3 months			
15'	3 (8.33%)	8 (16.33%)	P = 0.4480***
30'	23 (63.89%)	38 (77.55%)	P = 0.2549***
45'	10 (27.78%)	3 (6.12%)	**P = 0.0148*** **
12 months			
15'	0	5 (10.20%)	P = 0.1314***
30'	13 (36.11%)	28 (57.14%)	P = 0.0896***
45'	23 (63.89%)	16 (32.65%)	**P = 0.0084*** **
Gas continence			
3 months			
Absent	2 (5.56%)	10 (20.41%)	P = 0.1036***
Satisfactory	10 (27.78%)	34 (69.39%)	**P = 0.0004*** **
Complete	24 (66.67%)	5 (10.20%)	**P < 0.0001*** **
12 months			
Absent	1 (2.78%)	8 (16.33%)	P = 0.0991***
Satisfactory	6 (16.67%)	15 (30.61%)	P = 0.2233***
Complete	29 (80.56%)	26 (53.06%)	**P = 0.0168*** **

****Comparison of proportions test*

† $p < 0.05$ shows a statistically significant difference between the studied groups

DISCUSSIONS

Colon and rectal cancer is the third most frequent cancer in men and women. The American Cancer Society (ACS) estimates that 972,020 new colon cancer cases and 43,030 new rectal cancer cases will occur in 2018; the number of expected rectal cancer cases is 25,920 in men and 17,110 in women. To estimate deaths, ACS combines colon and rectal cancers; about 50,630 deaths caused by colorectal cancer are expected to occur in 2018.(6)

The incidence of colorectal malignancies is slightly higher in men than in women. The global incidence of colorectal cancer adjusted for age in all races was 48.9 per 100,000 population for men and 37.1 per 100,000 population for women in the period 2008-2012, with a male-to-female ratio of 1.32:1.(7) This is also found in our study.

The literature confirms an increase in the incidence of colorectal cancer after the age of 35 years and a rapid increase after the age of 50 years, with the highest value in the seventh decade of life. More than 90% of colon cancers occur after the age of 50.(8) The incidence rate of rectal cancer has increased by 3.2% per year in patients aged between 30 and 39 years, and in those aged between 40 and 54 years the incidence rate has increased by 2.3% per year starting with 1990.(9) From 2004 to 2013, the incidence of colorectal cancer increased by

approximately 2% per year in adults aged less than 50 years, largely due to the increase in the number of rectal cancer cases.(7) This finding is also present in our study.

The standard of care for patients with rectal cancer is to save the anal sphincter with the restoration of intestinal function by mechanical colorectal anastomosis or coloanal anastomosis and to preserve the genitourinary function, by preservation of hypogastric nerves.(10,11) The solutions for the restoration of digestive continuity after mesorectal resection are dictated by the length of the residual stump. In the case of a sufficiently long stump, low anterior resection (Dixon surgery) is performed. In the case of a short stump, there are two options, either low anterior resection, which is more difficult and more risky in this situation (particularly in obese patients or patients with a narrow pelvis), or coloanal anastomosis – which are alternatives to rectal amputation.(12) In other words, the shorter the distance from the anus, the more difficult to perform is manual anastomosis, especially for adenocarcinomas located in the lower third of the rectum. In this study, low resection of the rectal tumor was possible by using a linear stapler in 69.44% of cases, compared to 42.85% of cases in which this device was not used. Also, the development of transanal circular staplers has significantly facilitated this type of anastomosis.(13)

Regarding postoperative complications, the rate of anastomotic fistula ranges between 2 and 11% (14,15), which is also confirmed by the current study. This is why protective external diversion is indicated in low and very low anastomoses. Ileostomy is the best solution, given the lower risk of complications (prolapse, suppuration, eventration, etc.) and the easiness in performing and suppressing it.(16,17,18,19) In this study, this was carried out temporarily in all low resection cases (the lower and middle 1/3 of the rectum).

Very low colorectal anastomoses situated in the proximity of the anal orifice are associated in 40% of the cases with intermittent fecal losses, incontinence and urgent stools in up to 50% of the cases.(20) After such a surgery, patients should know that they may have mild sphincter dysfunction. This is confirmed by our study, which shows an incontinence of more than 4 stools per day in 20% of the entire group of patients at one year postoperatively, with a statistically significant difference between the groups.

CONCLUSIONS

The following can be concluded based on the results obtained:

From a demographic point of view, there is an increased incidence of the disease in male patients during the third – eighth decades of life, with a predominantly lower location. At this level, rectal resection could be achieved in a proportion of 69.44% using a linear stapler, compared to 42.85% of cases undergoing manual resection, with a statistically significant difference ($p = 0.017143$). This highlights the importance of using a linear stapler in low rectal tumour resection.

Using a linear stapler shortened the operative time by 15 minutes ± 4 minutes compared to manual resection ($p < 0.0001$). The advantage of using a linear stapler consists of obtaining a mechanical suture of the rectal stump and of eliminating the septic time given by the opening of the rectal lumen, as is the case in manual resection.

An important role in preventing anastomotic fistula is played by temporary ileostomy. This was carried out in the majority of the patients in which a linear stapler was used for resection and mechanical suture of the rectal stump compared to the other group of patients (88.89% vs. 38.77%, $p = 0.000002$). The incidence of anastomotic fistula was present in patients undergoing rectal resection in the lower and middle 1/3 of the rectum, without a statistical difference between the two groups, but all patients in group A who did not undergo temporary ileostomy subsequently developed anastomotic fistula compared to group B, with a statistically significant difference ($p = 0.001509$).

At 12 months postoperatively, patients with mechanical suture of the rectal stump recover a normal lifestyle: 2 stools/day (75%), defecation delayed by 45 minutes (63.89%), and complete gas continence (80.56%). Patients with manual suture of the rectal stump are left with major difficulties: 3-4 stools/day (89.79%), defecation can be delayed by 45 minutes in 32.65% of patients, and complete gas continence is present only in 53.06%.

The use of surgical staplers is safe both for surgeons and patients regarding sphincter preservation and consequently, the improvement of quality of life. However, their cost plays an important role in the treatment plan of these patients. The results of this comparative study can help the surgeon to counsel patients in this regard.

REFERENCES

1. Heald RJ, Husband EM, Ryall RD. The mesorectum in rectal cancer surgery-the clue to pelvic recurrence? Br J Surg. 1982;69(10):613-616.
2. Radu I, Aniţei MG, Scripcariu V, Dragomir C. Rezecţia anterioară joasă de rect cu excizie totală de mezorect – tehnică. Anatomie şi tehnici chirurgicale - Jurnalul de Chirurgie, Iaşi, ISSN 1584 – 9341. 2011;7(4):692.
3. Heald RJ. The Holy Plane of rectal surgery. J R Suc Med. 1988;81(9):503-508.
4. Popovici A. Chirurgia colonului, rectului şi canalului anal. Edit. Medicala. 2002;I:91-93.
5. Tsunoda A, Tsunoda Y, Narita K, Watanabe M, Nakao K, Kusano M. Quality of life after low anterior resection and temporary loop ileostomy. Dis Colon Rectum. 2008;51(2):218-222.
6. American Cancer Society. Cancer Facts & Figures 2018. American Cancer Society. Available at https://www.cancer.org/content/dam/cancer-org/research/cancer-facts-and-statistics/annual-cancer-facts-and-figures/2018/cancer-facts-and-figures-2018.pdf. Accessed: January 30, 2018.
7. Surveillance, Epidemiology, and End Results Program. SEER Stat Fact Sheets: Colon and Rectum Cancer. National Cancer Institute. Available at http://seer.cancer.gov/statfacts/html/colorect.html. Accessed: May 14, 2015.
8. Giovannucci E, Wu K. Cancers of the colon and rectum. Schottenfeld D, Fraumeni J, eds. Cancer. Epidemiology and Prevention. 3rd ed. Oxford University Press; 2006.
9. Siegel RL, Fedewa SA, Anderson WF, Miller KD, Ma J, Rosenberg PS, et al. Colorectal Cancer Incidence Patterns in the United States, 1974–2013. J Natl Cancer Inst. 28 February 2017. 109
10. Baxter NN, Garcia-Aguilar J. Organ preservation for rectal cancer. J Clin Oncol. 2007 Mar 10. 25(8):1014-20.
11. McNamara DA, Parc R. Methods and results of sphincter preserving surgery for rectal cancer. Cancer Control. 2003;10:212.
12. Parks AG, Percy JP. Resection and sutured colo-anal anastomosis for rectal carcinoma. Br J Surg. 1982;69:301.
13. Nicholls RJ, Lubowski DZ, Donaldson DR. Comparison of colonic reservoir and straight colo-anal reconstruction after rectal excision. Br J Surg. 1988;75:318.
14. Kim JS, Cho SY, Min BS, Kim NK. Risk factors for

anastomotic leakage after laparoscopic intracorporeal colorectal anastomosis with a double stapling technique. J Am Coll Surg. 2009;209(6): 694-701.
15. Xiao L, Zhang WB, Jiang PC, Bu XF, Yan Q, Li H, et al. Can transanal tube placement after anterior resection for rectal carcinoma reduce anastomotic leakage rate? A single-institution prospective randomized study. World J Surg. 2011;35(6):1367-77.
16. Chude GG, Rayate NV, Patris V, Koshariya M, Jagad R, Kawamoto J, et al. Defunctioning loop ileostomy with low anterior resection for distal rectal cancer: should we make an ileostomy as a routine procedure? A prospective randomized study. Hepatogastroenterology. 2008;55(86-87):1562-7.
17. Kim JS, Cho SY, Min BS, Kim NK. Risk factors for anastomotic leakage after laparoscopic intracorporeal colorectal anastomosis with a double stapling technique. J Am Coll Surg. 2009;209(6):694-701.
18. Rondelli F, Reboldi P, Rulli A, Barberini F, Guerrisi A, Izzo L, et al. Loop ileostomy versus loop colostomy for fecal diversion after colorectal or coloanal anastomosis: a meta-analysis. Int J Colorectal Dis. 2009;24(5):479-88. Epub 2009 Feb 12.
19. Tilney HS, Sains PS, Lovegrove RE, Reese GE, Heriot AG, Tekkis PP. Comparison of outcomes following ileostomy versus colostomy for defunctioning colorectal anastomoses. World J Surg. 2007;31(5):1142-51.
20. Nicholls RJ, Lubowski DZ, Donaldson DR. Comparison of colonic reservoir and straight colo-anal reconstruction after rectal excision. Br J Surg. 1988;75:318.