AORTIC ARCH DEBRANCHING-HYBRID TECHNIQUE- CASE PRESENTATION

CLAUDIU GHIRAGOSIAN[1], MARIUS HARPA[2], RADU BĂLĂU[3], HUSSAM AL-HUSSEIN[4], HORAȚIU SUCIU[5]

[1,2,3,4,5]Emergency Institute for Cardiovascular Diseases and Transplantation Tîrgu-Mureș, [2,3,4,5]University of Medicine and Pharmacy Tîrgu-Mureș

Keywords: *aortic dissection, aortic aneurysm, aortic debranching, stent grafting*

Abstract: *Aortic arch pathologies are possible life-threatening conditions with demanding management caused, in general, by anatomic aspects as well as patient's age and comorbidities. We present the case of a 59-year old male with dissected aortic aneurysm involving the aortic arch and descending thoracic portion. Hybrid intervention was performed, more precisely aortic arch debranching using polyester prosthesis and subsequently stent implantation at the level of aortic arch and descending thoracic aorta with excellent results. This method of approach is safer considering the elimination of cardiopulmonary bypass and deep hypothermic circulatory arrest.*

INTRODUCTION

The term aortic aneurysm (AA) assumes dilatation of an aortic segment greater then 50 % than expected for the same aortic portion in healthy individuals of the same age and sex.(1) The classification of AA is based on their location, size, form, cause and morphology. Thoracic AA is less common compared to abdominal AA due to increased amounts of elastin.(2) The percentage of ascending AA is the highest, about 60%, followed by descending aorta-35% and aortic arch- less then 10%.(3)

Over the last decades, less invasive medical technique were developed and are in constant improvement. The purpose is to avoid conventional surgical therapy of aortic arch aneurysms because it involves cardiopulmonary bypass and deep hypothermic circulatory arrest in order to replace the aortic arch. Sidestepping deep hypothermic circulatory arrest is avoided higher morbidity and mortality on account of neurologic and metabolic complication. Since Dake and colleagues performed the first endovascular stent graft repair of thoracic aneurysm in 1994, this meted have become more and more accessible over the years as an alternative for surgical intervention or for reducing the extend of surgical intervention. The success of thoracic endovascular aortic repair (TEVAR) is well demonstrated in the repair of pathologies of the descending aorta.(4) It has the benefit of reducing the risks of conventional surgery, especially in older patients or in the presence of significant comorbidities. Nevertheless, the treatment of aortic arch aneurysms remains demanding.(5-6)

Aortic arch debranching using a hybrid platform is less invasive compared with total open surgical approach for treating aortic pathology; this corresponds to lower morbidity and mortality rates, even in high-risk patients.(6) Management of aortic diseases, dissections or aneurisms, continues to evolve as endovascular options, thus playing an increasing role in treating thoracic aortopathies. Although in patients with old age and/or high disease comorbidity index, there is significant associated morbidity and mortality, the gold standard for treating aortic arch disease still remains conventional surgery.(7)

The hybrid arch management essentially implies three main principles: (I) open surgical approach for debranching of the great vessels; (II) providing adequate landing zones and (III) stent grafting of the aortic arch in the same session or postboned. For good technical results of the implantation it should be at least 2 cm of landing zone available at the proximal and distal end of the aorta to achieve a good seal without over-extending distal graft landing in view of the fact that increases the risk for spinal cord ischemia. In selected cases ,total or partial revascularization of the supra-aortic branches is required in order to avoid a series of neurologic and vascular complications.(8,9)

CASE PRESENTATION

A 59-year-old male with a history of III degree hypertension, obesity, with no previous surgical interventions, complaining about progressive back pain was evaluated in our clinic following the denial for repair of a thoracoabdominal aortic aneurysm with chronic dissection at several other medical centers. Computed tomography angiography (angio-CT) revealed aneurysmal fusiform disease throughout the arch and into the three great vessels and a maxim diameter of 58 mm was noted just distally to the right subclavian artery. The dissection actually extended from the aortic arch distally into the thoracic section. All visceral and iliac vessels were fed by true lumen. (figure no. 1). Further investigations - echocardiography and coronarography- revealed no pathological findings.

Figure no. 2. Intimal flap of the thoracic aorta seen on CT angiogram

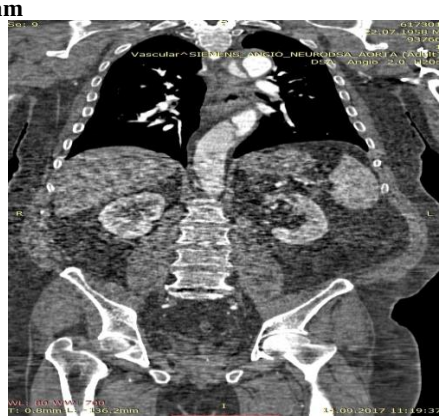

[2]Corresponding author: Marius Harpa, Str. Gheorghe Marinescu, Nr. 50, Tîrgu-Mureș, România, E-mail:ccv.tgm@gmail.com, Phone: +40740 751422
Article received on 21.08.2018 and accepted for publication on 03.09.2018
ACTA MEDICA TRANSILVANICA September 2018;23(3):35-38

Surgical technique

To repair the lesion, we decided to perform an open surgical intervention via total sternotomy to debranch the aortic arch followed by subsequently stent implantation onto thoracic aorta. Techniques include intraoperative neuromonitoring- near-infrared spectroscopy (NIRS) and cerebrospinal fluid management using lumbar drain, beside basic monitoring- central venous pressure, pulmonary artery catheter, transesophageal echocardiography and invasive blood pressure measurement at different sites. After exposing the ascending aorta, the supraaortic vessels were dissected and the innominate vein was encircled for better exposure. Then, the ascending aorta was tangentially clamped after systemic heparinization (some authors see the need for cardiopulmonary bypass before they tangentially clamp the ascending aorta- i.e., in patients with proximal ascending aortic aneurysms whose landing zone extends almost to the level of the sinotubular junction), and a longitudinal arteriotomy was performed.(10) An end-to side anastomosis between the main body of the bifurcated polyester prosthesis (14x7x7 mm Dacron) and the ascending aorta was done with a 4-0 Prolene running suture. The cross clamp was then released and the air was removed from the graft. End-to-end anastomosis was performed between the left subclavian artery (LSA) and left common carotid artery (LCCA) with branches of the prosthesis. Subsequently, an end-to- side 8-mm polyester linear graft was sewn onto the right branch of the polyester graft for subsequent anastomosis to the brachiocephalic trunk (BT). BT was cross-clamped followed by end-to-end anastomosis with the 8 mm prosthesis. Each anastomosis was followed by proximal ligature of the vessel to prevent a type II endoleak. It is highly recommended that a large, atraumatic side biting clamp be used for the ascending aorta and that the blood pressure be lowered considerable so as to minimize the risk of ascending aortic dissection. The innominate vein was not transected, the grafts were placed under it, to prevent specific complications following this manoeuvre. The anastomosis was reinforced with Teflon-pfleges (figure no. 2)

Figure no. 2. Intraoperative image of supra-aortic vessels debranching

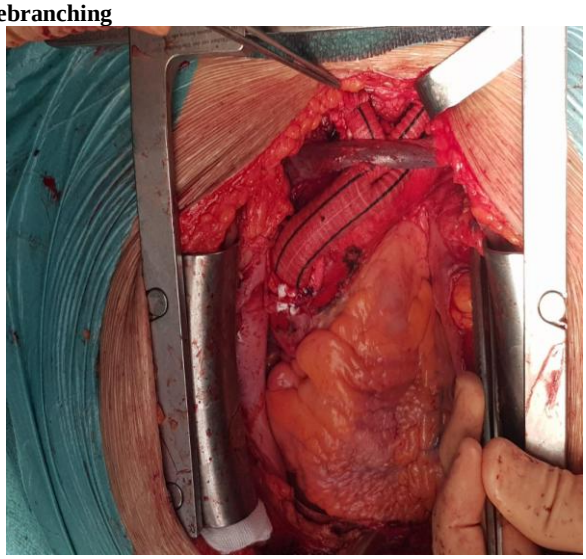

Immediately after surgical intervention we proceeded to stent implantation. Through a right femoral puncture a 7-French arterial sheath was inserted. Two Proglide-type vascular closure devices were placed. A 11-French arterial sheath was placed, crossed by a 5.2-French Pig tail catheter up to the ascending aorta, the position in the true lumen was checked. A super-stiff 0.035" Meyer back-up guide was inserted up to the ascending aorta followed by expansion of Jotec E vita Thoracic vascular endoprosthesis at the aortic arch level and towards descending aorta. The 18-French arterial sheath was introduced, a 5.2-French Pig tail catheter was pass through vascular endoprosthesis to the ascending aorta. Control angiography showed good apposition of the endoprosthesis (figure no. 3) The right femoral puncture site was closed with Proglide devices. Post-intervention the patient was hemodynamic and respiratory stable without intra or post-procedural complications, with 24 hours staying in the Intensive Care Unit (ICU) department, no inotropic support needed, he was discharged 7 days after.

Figure no. 3. Angiographic result after stent implantation at the aortic arch level towards the descending aorta

DISCUSSIONS

Eliminating the use of cardiopulmonary bypass and hypothermia, the technique for arch debranching was first introduced in the mid-2000s. The philosophy behind this procedure is to reconnect the vessels which would be obstructed by the stent graft to blood flow-ascending aorta in our case; there are some variation for this purpose: carotid-carotid bypass, carotid-subclavicular bypass - tailored to the case particularities. Therefore, to ensure optimal clinical outcome and minimize complications when the stent graft is placed in zones 0, 1, or 2 of the arch, we must perform the revascularization of the arch vessels first. Total aortic arch debranching provides the most secure proximal landing zone, aspect of high importance for securing the stent to the aortic wall. The application of traditional TEVAR requires a proximal and distal landing zone of at least 2 cm. Regarding zone 2-left subclavian artery-some discussions arises. In urgent situations, this zone can be covered without initial revascularization. Some particular situations demand revascularization of the subclavian artery: cases with anterior descending artery revascularization using the internal thoracic artery, poor vertebral arterial network ipsi- and contralateral, femoral artery revascularization with an axillary-femural bypass, arteriovenous fistula located at the left arm. Disregarding these indications can lead to spinal cord ischemia, myocardial infarction, vertebra-basilar insufficiency and upper extremity ischemia. EUROSTAR registry reported high incidence of stroke or spinal cord ischemia (8,4%) in patients

without previous left subclavian artery revascularization compared to cases with revascularization.(11)

Figure no. 4. Thoracic aortic landing zones (Z). Z0- ascending aorta up to the innominate artery, Z1- aorta from the innominate artery to the left carotid artery, Z2- the aorta from the left carotid to the left subclavian artery, Z3- includes the proximal descending aorta distal to the left subclavian artery, Z4- the mid descending aorta. (adapted from Cheung AT, Weiss SJ. Diseases of the aorta. In: Oxorn DC, ed. Intraoperative Echocardiography. Philadelphia: Saunders; 2012:161-182)

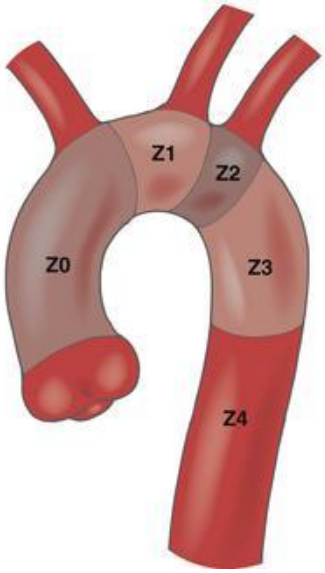

In general, arch aneurysms have no secure landing zone regarding zones 1 or 2 (figure no. 4) and the effectiveness of the arch branch preservation techniques should be assessed only when the left common carotid artery is involved. The revision of 18 studies comprising 195 patients with supra-aortic arch debranching, but excluding all carotid-subclavian bypasses, reported a 9% incidence of endoleak and stroke rates and perioperative mortality of 9% and 7%, respectively.(12) The type of aortic arch debranching is dictated by the classification of the thoracic aortic landing zones.

Having in mind the fact that the majority of the patients with aortic arch pathology are elderly and conventional surgical intervention entails cardiopulmonary bypass and hypothermic cardiac arrest, the intervention carries greater risks for neurological events even with the usage of retrograde or antegrade cerebral perfusion. As well, a substantial number of patients with aortic arch aneurysms has the added risk of a “redo” sternotomy after Bentall or ascending aorta repair. Many of patients in these categories will be considered unfit for total surgical reconstruction. There are studies emphasizing the postoperative mortality depending on patient age: less than 75 years at 9% and patients aged more than 75 years at 36%.(13) However, direct comparisons between conventional open and hybrid repairs are very difficult, as the former involve heterogeneous groups with different operative techniques and methods of intra-operative cerebral perfusion. Additionally, such comparisons between the outcomes of conventional open and hybrid repair should be cautious, because high-risk surgical patients with significant co-morbidities were usually excluded from open repair. Further refinement of stent graft technology and increasing experience with endovascular techniques might reduce both technical failure and stent-graft-related mortality figures.(14)

Studies revealed excellent bypass graft patency with the use of polytetrafluoroethylene, especially Byrne and colleagues analyzed 143 carotid and subclavian reconstruction for embolic and occlusive disease- the 5-year patency rate was 92%.(15)

Classification of the thoracic aortic landing zones determines the type of supra-aortic debranching.

CONCLUSIONS

To conclude, we have presented a technique for total surgical de-branching of the aortic arch and afterwards completely covering it with endovascular stent graft, which is a advantageous procedure since CPB and deep hypotermic circulatory arrest are avoided, thus lowering morbidity and mortality rates. Hybrid repair of complex aortic arch disease with revascularization of the supra-aortic branches prior to stent graft deployment has evolved as an alternative treatment option for selected patients who are high surgical risk for conventional open repair.

Debranching of supra-aortic vessels for thoracic aorta aneurysm facilitating second-stage endostent grafting proved to be safe and effective. This enables a complete repair in patients with dilatation of the distal thoracic aorta. These results are encouraging and demonstrate a role for an extensive approach in treatment of aortic arch pathology.

Due to improvement in interventional vascular procedures over the last years, the number of surgical aortic arch debranching with consecutive stent-graft implantation has increased on account of risk minimizing and fewer post-procedural complications compared to classic total median sternotomy and aortic cross clamping.

Hybrid aortic arch repair request excellent skills in surgery and endovascular interventions, especially pertinent as cardiac surgeons have to confront with pathologies in progressively older patients with significant higher morbidity. Suitable procedures and fewer postoperative adverse events of an arch debranching technique are detrimental factors that need to be considered for encourage proper outcomes of hybrid repair. Increasing interest in endovascular approach of the aortic arch pathology promotes the use of total endovascular platform.

REFERENCES

1. Jain RK, Raju T, Dhall A. Endovascular Management of Aortic Aneurysm and Dissection. Cardiac Catheterisation and imaging. 2015;55:876-895.
2. Saratzis A, Bown MJ. The genetic basis for arotic aneurysmal disease. Heart. 2014;100 (12):916-922.
3. Kuzmik GA, Sang AX, Elefteriades JA. Natural history of thoracic aortic aneurysms. J VascSurg. 2012;56(2):565-571.
4. Cheng D., Martin J., Shennib H., Dunning J., Muneretto C., Schueler S. Endovascular aortic repair versus open surgical repair for descending thoracic aortic disease: a systematic review and meta-analysis of comparative studies. J Am Coll Cardiol. 2010;55(10):986–1001.
5. Szeto WY, Bavaria JE, Bowen FW, Woo EY, Fairman RM, Pochettino A. The hybrid total arch repair: brachiocephalic bypass and concomitant endovascular aortic arch stent graft placement. J Card Surg. 2007;22:97–102.
6. Schoder M, Grabenwöger M, Hölzenbein T, et al. Endovascularrepair of the thoracic aorta necessitating anchoring of the stent graft across the arch vessels. J Thorac Cardiovasc Surg. 2006;131:380 –7.
7. Prashanth Vallabhajosyula, Wilson Y. Szeto, Nimesh Desai, Caroline Komlo, Joseph E. Bavaria. Type II arch

hybrid debranching procedure. Ann Cardiothorac Surg. 2013 May; 2(3):378–386
8. Görich J, Asquan Y, Seifarth H, et al. Initial experience with intentional stent-graft coverage of the subclavian artery during endovascular thoracic aortic repairs. J Endovasc Ther. 2002;9:39–43.
9. Tiesenhausen K, Hausegger KA, Oberwalder P, et al. Leftsubclavian artery management in endovascular repair of thoracic aortic aneurysms and aortic dissections. J Card Surg. 2003;18:429 –35.
10. Szeto WY, Bavaria JE, Bowen FW, Woo EY, Fairman RM, Pochettino A. The hybrid total arch repair: brachiocephalic bypass and concomitant endovascular aortic arch stent graft placement. J Card Surg. 2007;22:97–102.
11. Buth J, Harris PL, Hobo R, et al. Neurologic complications associated with endovascular repair of thoracic aortic pathology: incidence and risk factors. a study from the European Collaborators on Stent/Graft Techniques for Aortic Aneurysm Repair (EUROSTAR) registry. J Vasc Surg. 2007;46:1103-1110.
12. Antoniou GA, El Sakka K, Mamady M, Wolfe JHN. Hybrid treatment of complex aortic arch disease with supraaortic debranching and endovascular stent graft repair. Eur J Vasc Endovasc Surg. 2010;39:683-690.
13. Milewski RK1, Szeto WY, Pochettino A, Moser GW, Moeller P, Bavaria JE. Have hybrid procedures replaced open aortic arch reconstruction in high-risk patients? A comparative study of elective open arch debranching with endovascular stent graft placement and conventional elective open total and distal aortic arch reconstruction.Hybrid Treatment of Complex Aortic Arch Disease with Supra-aortic Debranching and Endovascular Stent Graft Repair. J Thorac Cardiovasc Surg. 2010 Sep;140(3):590-7.
14. Byrne J, Darling RC, Roddy SP, et al. Long term outcome for extra-anatomic arch reconstruction. An analysis of 143 procedures. Eur J Vasc Surg 2007;34:444 –50.
15. Criado FJ, Barnatan MF, Rizk Y, Clark NS, Wang CF. Technical strategies to expand stent-graft applicability in the aortic arch and proximal descending thoracic aorta. J Endovasc Ther. 2002;9:II32–II38.