MULTIMODAL INVESTIGATION OF HEART METASTASIS PRESENTED AS MYOCARDIAL BRIDGING IN A PATIENT WITH RENAL CELL CARCINOMA: A CASE REPORT

ALINA IOANA NICULA[1], ANDREEA NICOLETA MARINESCU[2], ANDREI VICTOR MARINESCU[3], MIHAI DUMITRU[4], ROMICA CERGAN[5], GHEORGHE IANA[6]

[1,2,3,4] *"Carol Davila" University of Medicine and Pharmacy, Bucharest*

Keywords: *myocardial bridging, metastasis, renal cell carcinoma, cardiac MRI*

Abstract: *Cardiac metastases are rare, but more frequent than primary tumors of the heart, and present usually with pericardial effusion. We present the case of a 67 year old male with acute coronary syndrome as first manifestation of a heart metastasis from renal cell carcinoma. The patient was investigated with echocardiography, coronarography, cardiac magnetic resonance and computed tomography, revealing a contralateral recurrence of renal cell carcinoma with a myocardial metastasis which exerted external compression on the left anterior descending coronary artery (LAD), mimicking myocardial bridging. This case underlines the importance of complementary examination in the differential diagnosis of oncologic patients.*

INTRODUCTION

Cardiac metastases are considered a rare complication of a neoplastic disease,(1) with recent studies, however, suggesting an incidence of up to 15%.(2) Most are detected at necropsy, but some are symptomatic, causing pleural effusion and arrhythmias.(3) Myocardial ischemia is a rare occurrence, most likely caused by coexisting atherosclerotic disease.(3,4)

We present the case of an external compression of the LAD by a myocardial metastasis, an exceedingly rare occurrence.(5)

CASE REPORT

A 67-year old male was admitted with clinical signs of an acute cardiac episode.

On previous admission the transoesophageal echocardiography discovered a 3 cm mass on the anterior wall of the left ventricle (figure no. 1, yellow arrows).

Figure no. 1. Transesophageal echocardiography revealing the mass

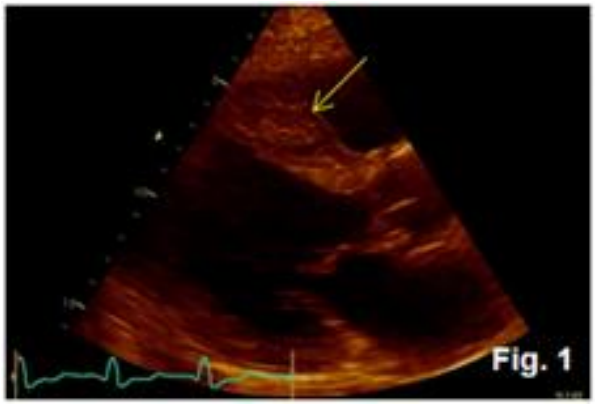

Other associated pathology: stenting the 1st diagonal branch due to myocardial bridging (figure no. 2); left nephrectomy for renal cell carcinoma (RCC).

Figure no. 2. Coronarography revealing the myocardial bridge

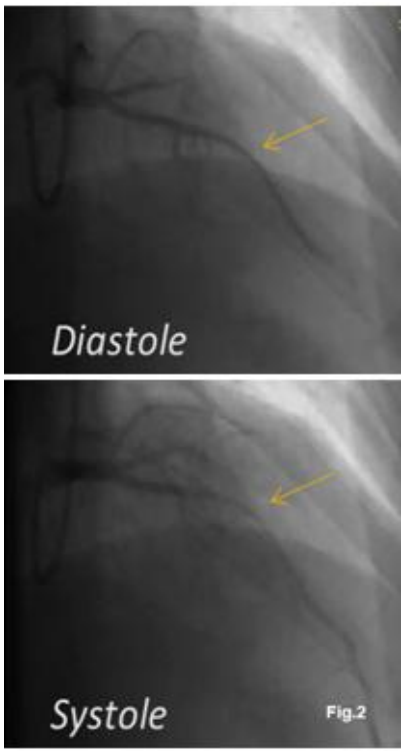

Transthoracic echocardiography revealed a moderate septal hypertrophy, no pericardial effusion, and an ejection fraction of 50%.

The patient was referred for cardiac magnetic resonance (CMR) in order to assess and characterize the suspected myocardial mass. An ECG- gated CMR was performed.

Steady state free precession (SSFP) cine sequences demonstrated normal ventricular function - EF of 54%, and also

[4]Corresponding author: Mihai Dumitru, Str. Sarandy Frosa, Nr. 1, Bl. 33, Sc. A, Ap. 12, București, România, E-mail: orldumitrumihai@yahoo.com, Phone: +40721 752318
Article received on 26.07.2018 and accepted for publication on 31.08.2018
ACTA MEDICA TRANSILVANICA September 2018;23(3):39-43

the presence of a cardiac mass (yellow arrows, figure no. 3) which encompasses the anterior half of the IVS, at base level and medium chamber, the anterior left ventricular (LV) wall and minimal involvement of the free wall of the adjacent right ventricle (RV). The mass had lower mobility than the unaffected myocardium.

Figure no. 3. Cardiac MRI – analyzing cardiac function

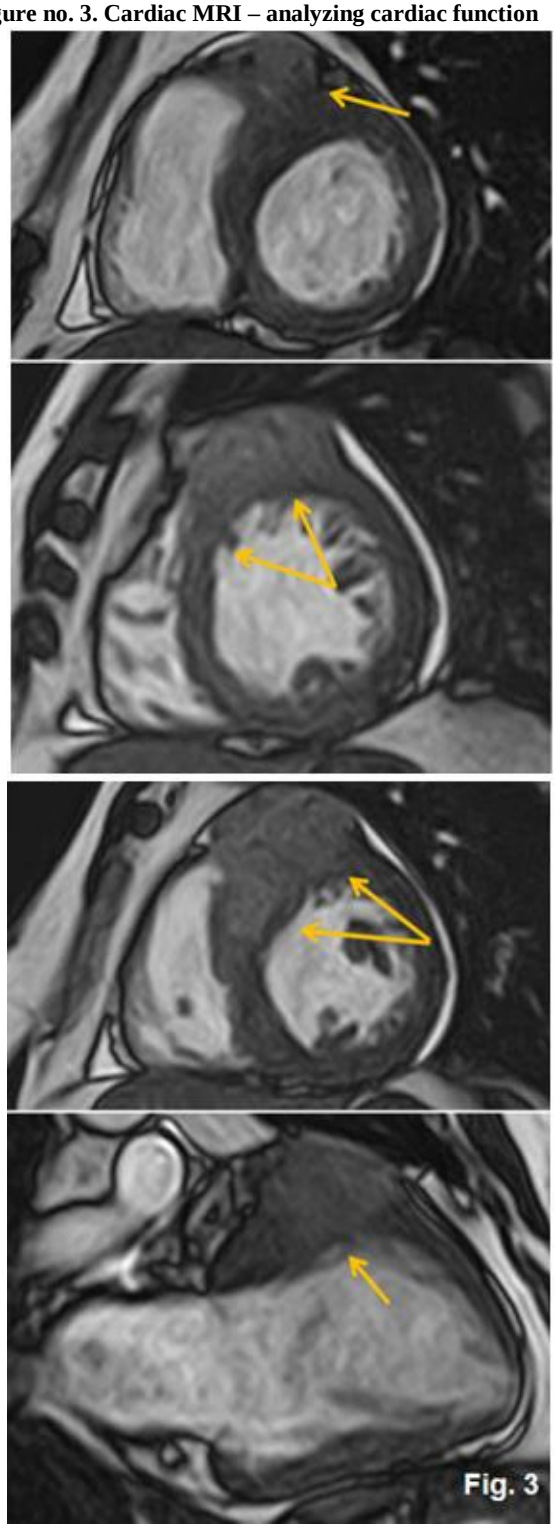

The mass showed hyperintensity on T2 weighted images (yellow arrows, figure no. 4), with two small areas with flow void (white arrows); the adjacent pericardium also showed hypersignal (arrowhead).

Figure no. 4. T2 sequence on MRI of the case

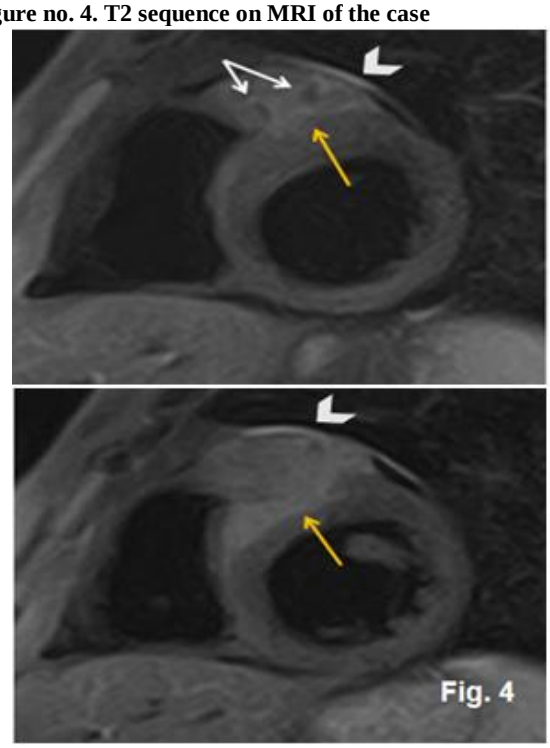

T1 FatSat images (figure no. 5) showed no fatty components and no delimitation between the mass and the pericardium.

Figure no. 5. T1 sequence on MRI of the case

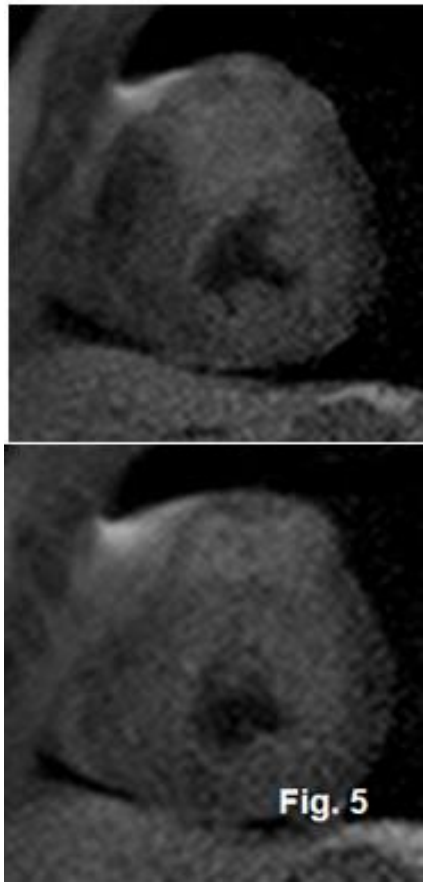

Delayed contrast enhanced images (figure no. 6) revealed heterogeneous enhancement of the mass which

encompassed all myocardial layers (yellow arrow) and the pericardium (white arrowhead).

Figure no. 6. Contrast enhanced MRI sequence

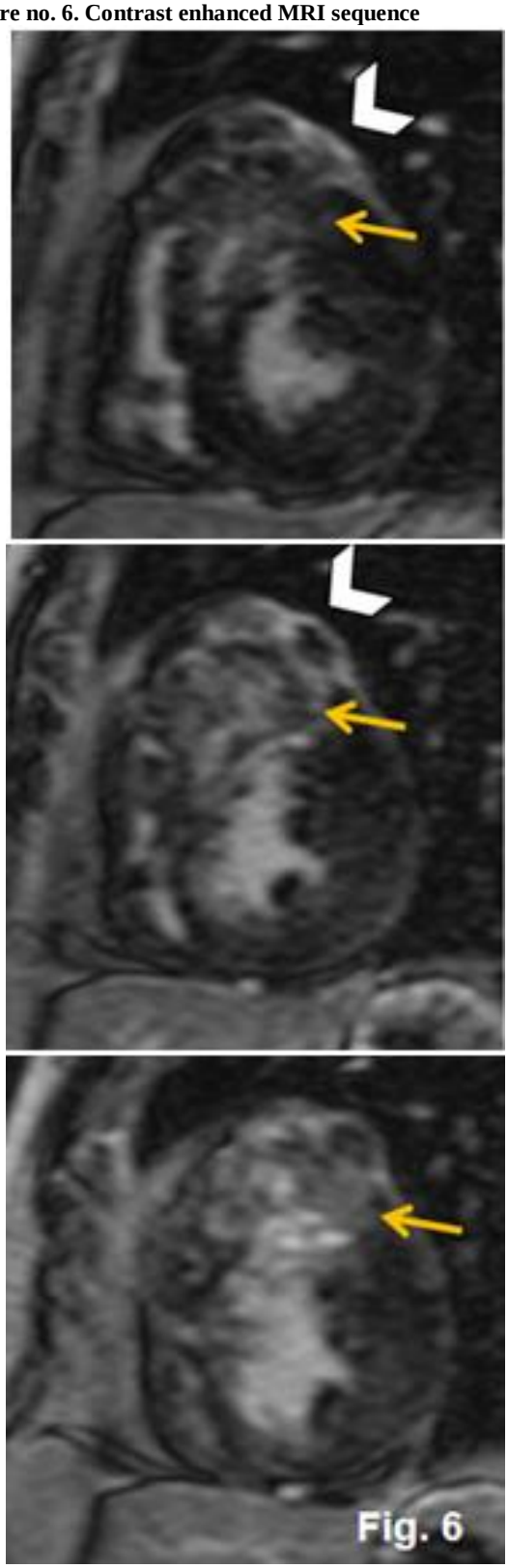

We performed a contrast enhanced CT scan revealing that the mass enveloped the mid LAD segment and that the mass had the same imaging features of a right renal carcinoma. Thus the final diagnosis was determined to be recurrent RCC, with single mio-pericardial metastasis.

Considering the patient's history, a contrast-enhanced CT scan of the thorax and abdomen was performed. It confirmed the CMR findings and showed the mass enveloping the mid LAD segment (red arrow, figure no. 7).

Figure no. 7. Contrast CT in the same case

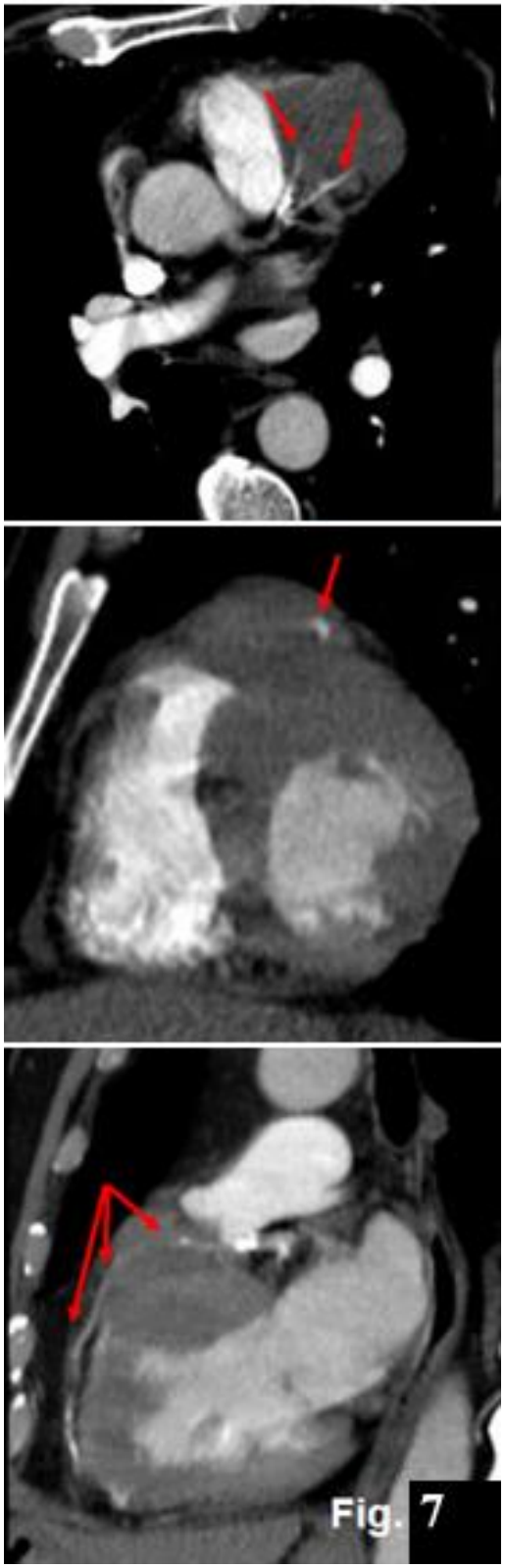

CT examination of the abdominal region revealed a large left renal mass (figure no. 8) with the imagistic features of a RCC (heterogeneous mass – a, b, orange arrow; the presence of the collateral circulation – a, red arrow; an intrarenal aneurismal dilatation – b, red arrow; disrupted the renal architecture - d, red arrow). This kidney mass presented the same tomodensitometric signs with the cardiac mass.

Figure no. 8. Abdominal CT scan for renal mass analysis

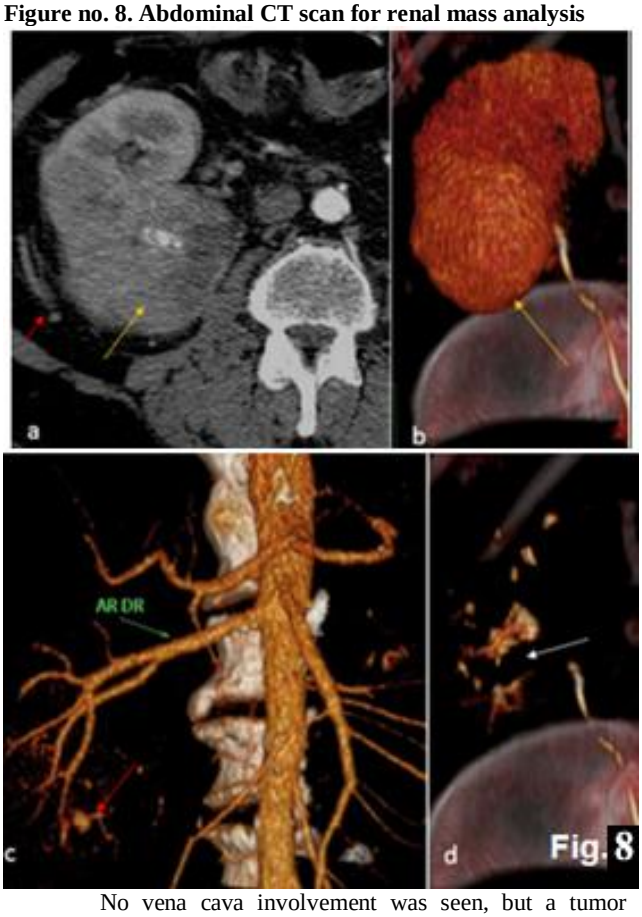

No vena cava involvement was seen, but a tumor thrombus in the right renal vein could be noticed.

The patient was diagnosed with recurrent RCC (renal biopsy confirmed our diagnostic) with most probably heart metastasis (the patient refused cardiac biopsy), for which he received conservative treatment, with antiplatelets, beta blockers, diuretics and nitrates, and showed a positive evolution. On discharge he had normal cardiac function, with an elevated creatinine level of 2 mg/dl and was directed toward an Oncology specialist.

Over the next 6 months he returned twice, in October and December 2016 with acute chest pain and dyspnea, diagnosed as recurrent anterior NSTEMI, for which he received conservative treatment, adding anticoagulants and statins to his medication. During this period the patient maintained elevated creatinine levels and developed mild anemia. He did not pursue Oncology treatment. During December admittance his EF was 35%.

In January 2017 he was admitted for severe dyspnea. On admittance he had tachycardia, elevated creatinine, and numerous ventricular extrasystoles on the EKG. TTE showed a EF of 15-20% with severe myocardial metastatic infiltration and discrete pleural effusion.

On the chest X-Ray, multiple pulmonary nodules, alongside pleural effusion were identified. This was followed by a chest CT without contrast material on which the pulmonary nodules, pleural and pericardial effusions were confirmed, and an osteolytic lesion was identified on the 12th thoracic vertebral body.

During his last admission he had a steady decline in cardiac function, despite maximal medical treatment with the development of severe anemia and increasing creatinine levels, up to a value of 5.7mg/dl. He eventually went into cardiac arrest for which CPR was unsuccessful.

DISCUSSIONS

The clinical manifestations of cardiac metastases are nonspecific and depend on their location, with most being clinically silent and diagnosed only postmortem.(6) When symptomatic, the most common symptoms are dyspnea and arrhythmias.(7,8) Considering the recent increase in the incidence of cancer patients that show signs of cardiac metastases, this differential diagnosis needs to be taken into account.(9)

While, as we have discussed, heart metastases are not as uncommon as first thought, heart metastases being the first sign of a recurrence are rare. Therefore, the most common sites that cause heart metastases need to be known. Tumors can spread to the heart by direct extension, through the bloodstream, through the lymphatic system and by intracavitary diffusion through either the inferior vena cava or the pulmonary veins.(1) The most common cancers that spread to the heart are breast, lung, lymphomas and melanomas.

While TTE is the routine examination of the heart and can adequately identify a cardiac mass, it has some limitations including operator dependence, a restricted field of view, and limited imaging of the right heart and mediastinum and extracardiac structures. CT is useful in characterizing heart masses, including the vasculature and presence of fat or calcification, particularly when EKG-gated.(10) It does come at the cost of using ionizing radiation which is to be of particular importance in a oncologic case. Lastly, MR imaging offers higher temporal resolution and additional tissue characterization than CT, and MR imaging does not expose patients to ionizing radiation.(11)

As stated by Möhlenkamp et al., myocardial bridging can occasionally generate clinically important complications, despite usually being a benign condition.(12) This is true for true myocardial bridging, whereas the case presented highlights the need for a thorough investigation of the lesion. While coronarography identified the bridging, CMR and CT were able to identify it as a metastatic nodule, while CT identified the likely source. This opened up therapeutic options adequate for the underlying disease at the time of diagnosis.(13)

CONCLUSIONS

We present a case which required multimodal investigation of heart metastasis presented as myocardial bridging in a patient with renal cell carcinoma. Such complex cases reunite the effort of specialists from different fields of activity: diagnostic imaging, cardiology, cardiac surgery, general surgery, and oncology. Unfortunately in spite of extreme medical measures we recorded patient's exitus.

REFERENCES

1. Bussani R, De-Giorgio F, Abbate A, Silvestri F. Cardiac metastases. J Clin Pathol. 2007;60:27–34. doi:10.1136/jcp.2005.035105.
2. Mukai K, Shinkai T, Tominaga K, Shimosato Y. The incidence of secondary tumors of the heart and pericardium: a 10-year study. Jpn J Clin Oncol. 1988;18:195–201. Available:

https://www.ncbi.nlm.nih.gov/pubmed/3411785.
3. Wolver SE, Franklin RE, Abbate A. ST segment elevation and new right bundle branch block: broadening the differential diagnosis. Int J Cardiol. 2007;114:247–248. doi:10.1016/j.ijcard.2005.11.056.
4. Kopelson G, Herwig KJ. The etiologies of coronary artery disease in cancer patients. Int J Radiat Oncol Biol Phys. 1978;4:895–906. Available: https://www.ncbi.nlm.nih.gov/pubmed/361663.
5. Weinberg BA, Pinkerton CA, Waller BF. External compression by metastatic squamous cell carcinoma: a rare cause of left main coronary artery narrowing. Clin Cardiol. 1990;13:360–366. Available: https://www.ncbi.nlm.nih.gov/pubmed/2347127.
6. Al-Mamgani A, Baartman L, Baaijens M, de Pree I, Incrocci L, Levendag PC. Cardiac metastases. Int J Clin Oncol. 2008;13: 369–372. doi:10.1007/s10147-007-0749-8
7. Yusuf SW, Bathina JD, Qureshi S, Kaynak HE, Banchs J, Trent JC, et al. Cardiac tumors in a tertiary care cancer hospital: clinical features, echocardiographic findings, treatment and outcomes. Heart Int. 2012;7:e4. doi:10.4081/hi.2012.e4
8. James TN, Carrera GM. Pathogenesis of arrhythmias associated with metastatic tumors of the heart. N Engl J Med. 1959;260:869–871. doi:10.1056/NEJM195904232601707.
9. Goldberg AD, Blankstein R, Padera RF. Tumors metastatic to the heart. Circulation. 2013;128:1790–1794. doi:10.1161/CIRCULATIONAHA.112.000790.
10. ASCI CCT & CMR Guideline Working Group, Tsai I-C, Choi BW, Chan C, Jinzaki M, Kitagawa K, et al. ASCI 2010 appropriateness criteria for cardiac computed tomography: a report of the Asian Society of Cardiovascular Imaging Cardiac Computed Tomography and Cardiac Magnetic Resonance Imaging Guideline Working Group. Int J Cardiovasc Imaging. 2010;26 Suppl 1:1–15. doi:10.1007/s10554-009-9577-4.
11. Motwani M, Kidambi A, Herzog BA, Uddin A, Greenwood JP, Plein S. MR imaging of cardiac tumors and masses: a review of methods and clinical applications. Radiology. 2013;268: 26–43. doi:10.1148/radiol.13121239.
12. Möhlenkamp S, Hort W, Ge J, Erbel R. Update on myocardial bridging. Circulation. 2002;106:2616–2622. Available: https://www.ncbi.nlm.nih.gov/pubmed/12427660.
13. Cham WC, Freiman AH, Carstens PH, Chu FC. Radiation therapy of cardiac and pericardial metastases. Radiology. 1975;114:701–704. doi:10.1148/114.3.701.