THERAPEUTIC APPROACH IN PANCREATIC BLUNT TRAUMA IN PEDIATRIC POPULATION

TAMAS TOTH[1], ANA MARIA PRIŞCĂ[2], SAROLTA-BEÁTA KÁVÁSI[3], RADU PRIŞCĂ[4]

[1,3]Student, University of Medicine and Pharmacy Târgu-Mureș, [2]Lotus Life-Integrative Medicine Centre, Târgu-Mureș, [4]University of Medicine and Pharmacy Târgu-Mureș

Keywords: *pancreatic blunt trauma, pediatric population*

Abstract: *Therapeutic approach in pancreatic blunt trauma can be challenging in pediatric population. Pancreatic trauma can be subtle and difficult to diagnose. We report two different cases with non operative and operative management of abdominal injuries. The first case had a second degree injury with a complication of a recurrent pseudocyst formation and the second case had a third degree injury described on the imaging studies. The evolution of the cases based on the injury grading was contradictory; the lower degree injury had to be operated. The conservative treatment of the third degree injury was resolved by the absorption of the fluid collection. However, recent studies demonstrated that the conservative treatment is safe and justified even in complete transaction of the pancreatic duct, randomized studies are needed for better algorithm outcomes*.

INTRODUCTION

Blunt abdominal trauma can cause pancreas damage in 3-12% of the cases in pediatric population.(1) The pancreas is the fourth most commonly injured solid organ in children.(2) Although is rarer than other solid organ injuries, these are the most commonly seen injuries in children following handlebar trauma. The mechanism of the trauma is due to direct compression of the pancreas against the spinal column. The pancreas damage can be present from a simple contusion to a duct or parenchyma damage. According to the impact side of the trauma, the damaged part of the pancreas can be presumed. In case of frontal compression the damaged part is the corpus. Left flank compression causes tail injury and can be associated with spleen injury. Following a right flank compression, the head of the pancreas is damaged and it can be associated with duodenum injury.(3,4) The most common injury site is the pancreatic body in the pediatric population. Children have normal baseline pancreatic function and concomitant injuries are uncommon. The mechanism of the trauma, the presence or absence of coexisting injuries and major duct injury are the main points of a correct early and accurate diagnosis.

It occurs in only 0.2% to 4% of all abdominal injuries so the management remains a challenge.(5) The aim of this article is to present, with two different cases, both therapeutic approaches in pancreatic blunt trauma: non operative and operative management of the injury.

CASE PRESENTATION

Case 1. A previously healthy 3 year old girl who sustained an abdominal blunt trauma was referred to us with complaints of abdominal pain and vomiting. The clinical examination revealed a distended abdomen without any traumatic bruise. The emergency ultrasound and X-ray did not describe any lesion. Her hemoglobin level was 10.1 g/dl, white blood cell count: $6.5x10^3/\mu l$, serum amylase: 546 U/L and glucose was 417 mg/dl. The abdominal CT scan with contrast from the next morning suspected a pancreatic lesion. An exploratory laparotomy with the drainage of the fluid collection was done because of her worsened general condition. A hemoperitoneum with retroperitoneal hematoma was detected. The hematoma was located in the left flank from the pancreas and left kidney to the Douglas space. Other solid organ injures were not described intraoperatively. The serum amylase level normalized (58U/L) after 3 days of hospitalization. The ultrasound revealed a 53/29 mm sized hyperechogenic pancreatic mass. She was discharged after two weeks of hospitalization, when her clinical evolution was favourable due to a rigorous hydroelectric rebalance and broad spectrum antibiotherapy. She returned after a week to the emergency department for diffuse abdominal pain. She was admitted to our department to evaluate her condition. She was discharged when the serum amylase level decreased from 290 U/L to 150U/L and the abdominal pain disappeared. The patient remained asymptomatic for almost four months when she presented diffuse abdominal pain, vomiting. The emergency ultrasound described a cystic mass at approximately 3 cm from the splenic hilum and tail of the pancreas. She was admitted again to our service for specific treatment. The serum amylase level was 223 U/L and an abdominal CT scan was performed on admission. The CT scan showed two cystic masses: 12 respectively 19 mm, fluid collection in the pararenal space and free fluid in the abdominal cavity. A pancreatic and a subhepatic drain were mounted during the exploratory median laparotomy. The postoperative evolution was favourable, but in 6 days she complained about diffuse abdominal pain. The control CT showed size increase of the mess from the pararenal space with 87/120/71 mm. According to the imaging finding a retroperitoneal and peritoneal drainage was implemented. Postoperatively, the patient was transferred to the ICU. Another laparotomy was necessary for the evacuation of the retroperitoneal fluid collection and a double drainage with a retrogastric and retropancreatic tube. The follow-up imaging studies showed the decreasing volume of the fluid collections. She was discharged from our service after 62 days without any

[1]Corresponding author: Tamas Toth, P-ța Trandafirilor, Nr. 34-35, Ap. 31, Cod 540053, Târgu-Mureș, România, E-mail: tamas.toth@yahoo.com, Phone: +40743 840279
Article received on 22.08.2018 and accepted for publication on 03.09.2018
ACTA MEDICA TRANSILVANICA September 2018;23(3):64-66

fluid collection sign on the ultrasounds. She was asymptomatic another 7 months when she presented colicative abdominal pain in the epigastric region with spontaneous remission. The ultrasound revealed a pancreatic pseudocyst which was confirmed by CT scan with the appreciation of its size of 7.9/5.2/5.25 cm. Pseudocyst-jejunal anastomosis was performed with good results.

Case 2. A previously healthy 13 year old boy presented to the emergency department due to an abdominal trauma after a bicycle accident. The clinical examination revealed a distended abdomen with a traumatic sign in the epigastric region. His hemoglobin level was 15.7 g/dl, white blood cell count: $21.37x10^3/\mu l$, serum amylase: 59 U/L, glucose: 113 mg/dl, and AST: 44 U/L, total bilirubin of 0.7 mg/dl. The ultrasound and X-ray did not describe any pancreatic lesion on admission. The emergency CT showed sanguinolent fluid collection of 70/43 mm in the peripancreatic space with a duodenal wall hematoma. The case was treated conservatively by monitoring the fluid collection with serial ultrasound examination. A second day follow-up ultrasound revealed a 70/40 mm sized hyperechogenic mass at the projection area of the duodenum. A broad spectrum antibiotherapy, hydroelectric rebalance, anti-inflammatory, antisecretory, gastro- and hepatoprotector medication was initialized. The highest serum amylase level with a value of 1816 U/L was observed on the second day of the hospitalization. The size of the peripancreatic fluid collection was regressive, his clinical condition was favourable. He was discharged after 17 days of hospitalization in good health with strict diet and specific recommendations.

DISCUSSIONS

The diagnosis of the isolated pancreatic injury can be demanding. Serum amylase and lipase analysis, ultrasonography and computed tomography are the used criteria to diagnose acute pancreatic injury. The most used grading system for pancreatic trauma was elaborated by the American Association for the Surgery of Trauma. Low grade pancreatic injuries (grade 1 and 2) do not involve the injury of the pancreatic duct and cause varying levels of pancreatitis. High grade injuries include the damage of the pancreatic body/tail (grade 3) and the pancreatic head/neck (grade 4 and 5).(6) Non operative management of other solid organs is demonstrated to be safe and effective, but in high grade injuries of the pancreas there are controversies in the therapeutic approach.(7) Some authors prefer early operative intervention (8) and others non operative approach.(9) Our tendency is to provide non operative treatment in case of pancreatic blunt trauma if the patient is stable hemodynamically.

The pancreatic injury of the first case was classified as low grade injury (grade 2) and the second case as high grade injury (grade 3) with the inclusion of the pancreatic body. The evolution of the cases based on the injury grading was contradictory, the first case needed surgical intervention and the second case had favourable outcome with conservative treatment. Our Case 1 developed a pseudocyst, however the probability of pseudocyst formation increases in patients with grade 3 injury and higher.

We reported two different cases of pancreatic injury encountered in our department. Both of them suffered a blunt trauma to their abdomen from an accident: the first one in a traffic accident and the second one from the handle bar of the bicycle. It is hard to establish pancreatic injury guidelines similar to the adult population because of the limited number of pediatric patients presenting to a single institution.

The particularity of the first case was that the pancreatic trauma was not visualized on admission on the imaging studies. The surgeon had to decide the therapeutic approach according to his experience level and the condition of the patient. Intraoperatively, he did not find any pancreatic duct tract transaction, but the patient developed as a delayed complication a pseudopancreatic cyst. The most common site of cyst formation is at the junction of the body and the tail as it occurred in both of our cases. The uniqueness of the second case was a normal range serum amylase level on admission; however it increased ten times until the next day. The severity of the injury was not correlated with the enzyme level. Figure no. 1 presents the changing of serum amylase level in both of the cases.

Figure no. 1. Serum amylase level during hospitalization. Case 1: undulatory evolution Case 2: gradual decreasing level until normalization

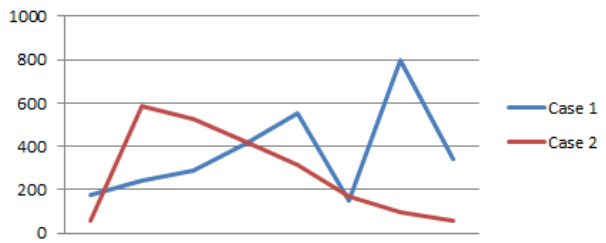

As we can see it, the serum amylase level is time dependent after blunt pancreatic trauma. Elevated levels of this enzyme can also be observed in injuries of the salivary gland, hepatic and duodenal trauma, and in intoxicated children.(10) The persistent elevated or rising amylase level is suggestive for pancreatic trauma but it does not indicate the severity of the injury. If laboratory findings are not sensitive or specific for pancreatic trauma, the imaging studies will have higher diagnostic accuracy.

As our case report demonstrated, ultrasound can be a cost effective imaging study in emergency cases but it is more reliable in the follow-up process of the pancreatic injury complications. The ultrasound did not describe the injury of the pancreas in the first case. The most frequent complications of the trauma are due to pancreatic duct rupture or stenosis so it is important to check the integrity of this structure. The accuracy of detecting by CT scan a major duct injury is 43%.(11) The CT can be normal in 20-40% in the first 12 hours after the trauma because of low changes in density.(12) A traumatic pseudocyst can be detected and monitored on serial US examinations as we did in the second case. We recorded the size changes of the fluid collection and would change the therapeutic approach if needed.

Mora and her colleagues did not find large impact on patient outcome according to the therapeutic approach.(13) The group of the delayed operative management had the worst outcomes. Beres and his group (14) found a significantly higher complication rate in the non operative managed patients. Our cases showed the contrary. The early operative management was followed by recurrent pseudocyst formation and the conservative treatment resolved the absorption of the fluid collection.

CONCLUSIONS

Mortality and morbidity are 5% and 26.5% of the pancreas injury in pediatric population, indicating the difficult managing of these patients. Early pancreatic injury can be missed on imaging studies. CT scanning after 24 hours is more reliable. The initial serum amylase level is not specific or sensitive for pancreatic injury; it supports clinical suspicion of the trauma. Non operative management is the treatment of

choice in majority of solid organ injuries. It is hard to establish a therapeutic algorithm for pancreatic injury in pediatric population because of its low incidence. Therapy should be individualized.

However, recent studies demonstrated that the conservative treatment is safe and justified even in complete transaction of the pancreatic duct, randomized studies are needed for better algorithm outcomes.

REFERENCES

1. Shilyansky J, Sena LM, et al. Non-operative management of pancreatic injuries in children. J Pediatr Surg. 1998;33;343-9.
2. Grosfeld JL, Cooney DR:Pancreatic and gastrointestinal trauma in children.Pediatr Clin North Am 1975; doi.10.1016/S0031-3955(16)33136-4.
3. Cirillo RL, Koniaris LG Detecting blunt pancreatic injuries.J Gastrointest Surg. 2003;6:587-98.
4. Arkovitz MS, Johnson N, Grcia VF. Pancreatic truma in children: mechanisms of injury. J Trauma. 1997;42:49-53.
5. Ko LS, Bulger EM, Parks DL, et al. Predictors of morbidityafter traumatic pancreatic injury. J Traum. 2003;55:898-905.
6. Moore EE, Cogbill TH, Malngoni MA, et al. Organ injury scaling, II: pancreas, duodenum, smll bowel, colon and rectum. J Trauma. 1990;30:1427-9.
7. Bindi Naik-Mathuria. Practice variability exists in the management of high-grade pediatric pancreatic trauma. Pediatr Surg Int. 2016; doi.10.1007/s00383-016-3917-y.
8. Canty TG, Weinmann D. Management of major pancreatic duct injuries in children. J Trauma. 2001;50:1001-7.
9. Loungnarth R, Blanchard H, Saint Vil D, et al. Blunt pancreatic injuries in children. Ann Chir. 2001;126:992-5.
10. Wright MJ, Stanski C. Blunt pancreatic trauma: a difficult injury. South Med J. 2000;93:383-5.
11. Gupta A, Stuhlfult JW, Fleming KW, et al. Blunt trauma of the pancreas and biliary tract: a multimodality imaging approach to diagnosis. Rdiographics, 2004;24:1381-95.
12. Cirillo RL, Koniaris LG. Detecting blunt pancreatic injuries. J Gastrointest Surg. 2002;6:587-598.
13. Mora MC, Kaitlyn EW, Friderici J, et al. Operative vs non operative management of pediatric blunt pancreatic trauma: Evaluation of the National Trauma Data Bank. J Am Coll Surg. 2015;12:1-6.
14. Beres AL, Wales PW, Christison-Lagay, et al. Non-operative management of high grade pancreatic trauma: is it worth to wait? J Pediatr Surg. 2013;48:1060-4.