CLINICAL ASPECTS OF CUTANEOUS ADVERSE EFFECTS INDUCED BY GLUCOCORTICOSTEROIDS

MIHAELA BALABAN[1], CĂTĂLIN MIHAI POPESCU[2], RALUCA POPESCU[3], GABRIELA TURCU[4], ALICE BRÎNZEA[5], ROXANA IOANA NEDELCU[6], ADRIANA DINU[7], BOGDANA VÎRGOLICI[8], MARIA MOHORA[9]

[1,2,3,4,5,6,7,8,9] "Carol Davila" University of Medicine and Pharmacy Bucharest, [1,4,6] "Derma360" Clinic, Bucharest, [2,3,4,5] Colentina Clinical Hospital Bucharest

Keywords: *glucocorticosteroids; adverse effects; atrophy; striae distensae*

Abstract: *Glucocorticosteroids are anti-inflammatory drugs, whose prolonged administration at high doses induces various adverse effects, such as the suppression of the hypothalamic-pituitary-adrenal axis and iatrogenic Cushing syndrome. Cutaneous side effects, such as skin atrophy, striae distensae, telangiectasia, acneiform eruption, purpura, rosacea-like eruption can be the result of both systemic and topical administration. The aim of this article is to emphasize the clinical aspects of cutaneous adverse effects induced by a prolonged administration of glucocorticosteroids.*

INTRODUCTION

Glucocorticosteroids represent a group of drugs with anti-inflammatory properties, used in the treatment of inflammatory, allergic and immunologic conditions, associated with multiple side effects.(1) In addition to their anti-inflammatory property, other roles (anti-proliferative, vasoconstrictive and immunosuppressive) had been demonstrated.(2) Their administration can be intravenous, oral, topical, intralesional, intraarticular, intramuscular and inhalation.(1)

The structure of the glucocorticosteroids contains the sterane nucleus, composed of four condensed cycles: three hexane cycles and one pentane cycle. These drugs can be differentiated by glucocorticoid potency, mineralocorticoid effects, time of action and clearance. Systemic glucocorticosteroids can be short-acting (cortisone, hydrocortisone), intermediate-acting (prednisone, prednisolone, methylprednisolone, triamcinolone) and long-acting (dexamethasone, betamethasone).(3) Cortisol (hydrocortisone) is the major natural glucocorticoid produced in the adrenal cortex.(4) Topical products are derived from hydrocortisone and their skin penetration property, the lipophilic characteristic, the solubility and the influence on the glucocorticoid receptor from the basal keratinocyte layer are related to their chemical structure.(3)

The aim of this article is to bring into attention the side effects involving the skin induced by corticotherapy.

A prolonged administration of systemic and topical glucocorticosteroids may be responsible for the development of iatrogenic (or exogenous) Cushing syndrome (by suppressing the hypothalamic-pituitary-adrenal (HPA) axis) which is the most frequent clinical form of hypercortisolemia.(5,6) Moreover, it is important to differentiate it from endogenous Cushing syndrome, which is caused by a pituitary or an ectopic hyper-secretion of adrenocorticotropic hormone (ACTH) or by an excessive production of cortisol from the adrenal glands.(7)

Regardless of the etiology, the cutaneous manifestations of Cushing syndrome are affined (6) and consist of purpura, atrophy, *striae*, telangiectasias, pseudoscars, acneiform eruption, rosacea-like eruption, perioral dermatitis, facial plethora, delayed wound healing.(3) In addition, the redistribution of the adipose tissue within specific areas, such as the face, nuchal and supraclavicular regions contributes to the appearance of Cushingoid aspect, described as "moon facies" and "buffalo hump".(7) Facial plethora (facial erythema) accompanies the clinical picture. Some of these effects are mediated through the glucocorticoid receptor from the basal layer of the epidermis, through the inhibition of keratinocytes growth factor and through collagen gene expression.(8)

A prolonged use of topical steroids can determine the appearance of localized atrophy, telangiectasias and hypopigmentation confined to the site of application.(3) Moreover, depending on various factors, the topical product may penetrate the skin and reach the bloodstream, thus producing HPA axis suppression, iatrogenic Cushing syndrome and adrenal suppression.(9-13)

First of all, the stratum corneum has a protective role, which hinders the penetration of the drug, especially in regions where skin thickness is maximum, such as palmoplantar area.(9) In contrast, other regions like the mucous membranes, scrotum, vulva and eyelids, where the skin is thinner, are more susceptible to become affected by localized cutaneous effects.(9) It also contributes to an enhanced absorption in the blood.(9) Moreover, the skin folds offer conditions for a higher penetration as stratum corneum is thinner, humidity is higher, permits natural occlusion and local temperature is higher.(14)

When the cutaneous protective barrier is abnormal, as in the case of a patient suffering from a skin condition characterized by erosions, inflammation or desquamation, the risk of percutaneous absorption is increased.(9,10) Depending on their potency, locally applied steroids are classified into seven groups, based on skin blanching property (vasoconstrictor capacity).(9) The most potent class (class 1- Ex: clobetasol propionate) is associated with a higher probability to induce systemic side effects.(9)

Other important factors that interfere with the likelihood of systemic effects are the chronic administration, especially the one involving large areas of the body, the use of corticosteroids at an increased concentration, the application of a great amount of the product, the type of the vehicle used (especially ointments) or the occlusive application.(9,10,14) The risk of systemic side effects is smaller when only a small region, such as the face, is topically treated.(15,16) In contrast to an adult, a child is more prone to develop HPA suppression and

[1]Corresponding author: Mihaela Balaban, Str. Comana, Nr. 3A, Bucharest, România, E-mail: mihaela.balaban@icloud.com, Phone: +40726 294446
Article received on 21.10.2018 and accepted for publication on 28.11.2018
ACTA MEDICA TRANSILVANICA December 2018;23(4):28-31

systemic effects, taking into consideration that he has a greater body surface area-to-weight ratio.(9,10,14,17)

Cutaneous adverse effects of corticosteroids

1. Atrophy

Both epidermis and dermis are affected by atrophy when using corticosteroids.(7) In the epidermis, the proliferation of the keratinocytes is inhibited.(14,18,19) In the dermis, the production of collagen 1 and 3 is diminished, as well as the synthesis of the hyaluronic acid from the extracellular matrix.(14,18,19) The fibroblast activity becomes abnormal.(14,18,19) Clinically, it presents as fragile, transparent skin with a "cigarette-paper" aspect, especially in intertriginous areas (axillae, groin) and genitals, where the penetration of the topical steroid is higher compared to other body regions (figure no.1).(20) In Cushing syndrome, atrophy of the dorsal part of the hands and elbows appears more frequently in children.(7) In the genital region, skin disorders that can mimic steroid-induced atrophy are lichen sclerosus and age-induced atrophy.(18,21)

Figure no. 1. Atrophy and striae distensae after systemic corticotherapy

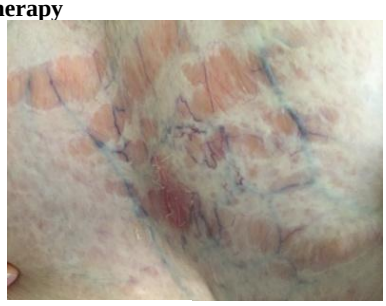

2. Striae distensae

Striae distensae are linear bands of wrinkled, fibrotic and erythematous skin arranged perpendicular to the skin tension lines (figures no. 1,2).(14,22) They appear related to mechanical stress and injury of the dermis, in the context of endocrinological anomaly, as the activity of the fibroblast is disrupted and the amount of collagen decreases.(23) Inflammation predominates in the initial phase and lately, thin collagen fibers are deposited following the lines of mechanical stress, as scar tissue.(14,24)

Clinically, the differentiation from those encountered in obesity, pregnancy or rapid growth is based on colour and dimension.(7,25)

Figure no. 2. Striae distensae after prolonged topical corticotherapy (Courtesy of dr. Cătălin Popescu)

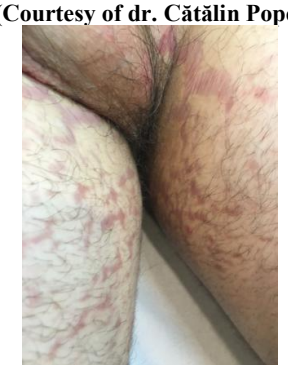

Those that are related to hypercortisolemia are more violaceous and exceed one cm in diameter whilst the striae associated with other causes are pink-silvery and narrower.(7,25) Ulceration and dehiscence may complicate the lesions, especially in patients treated with anti-endothelial growth factor therapy, which contributes to impaired wound healing.(26)

In iatrogenic Cushing syndrome striae can extend over large portions of the body (13), but in case of topical steroids the lesions appear in the treated area.

3. Acneiform eruption

Usually, it appears after systemic use of glucocorticosteroids. The clinical picture consists of an eruption that involves the upper back, upper extremities, face and cervical region as multiple red monomorphic papules and pustules (figure no. 3).(3,7)

Figure no. 3. Acneiform eruption in a patient taking systemic corticotherapy (Courtesy of dr. Raluca Popescu)

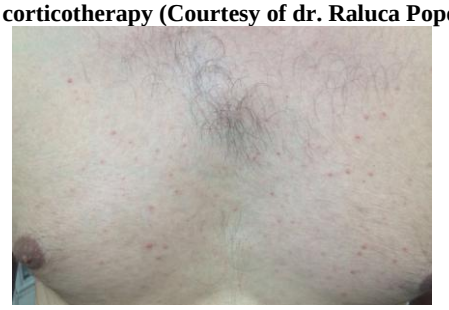

Topical products may favour the development of localized lesions.(16) The differential diagnosis includes other drug-induced acneiform eruptions (isoniazid, anabolic steroids, bromides, epidermal growth factor receptor inhibitors, phenytoin etc), occupational acne (cutting oils, chlorinated aromatic hydrocarbons) and tropical acne (induced by high temperatures).(27)

4. Telangiectasias

The lesions result from stimulation of nitric oxide release from the dermal endothelial cells, which produces an abnormal dilatation of the arterioles and the capillaries.(14,19,28) Clinically, telangiectasias present as erythematous small sized vessels visible on the skin.(29) Differential diagnosis may include hereditary hemorrhagic telangiectasia, spider angioma, poikiloderma of Civatte or sun-induced telangiectasias, mastocytosis (telangiectasia macular eruptive perstans), autoimmune diseases (CREST syndrome that consists of calcinosis, Raynaud phenomenon, esophageal dysmotility, sclerodactyly, and telangiectasia).(29)

5. Rosacea-like eruption

This type of eruption usually appears after chronic use of topical steroids on the face and resembles rosacea.(30) It consists of redness, telangiectasias, thinner skin, sometimes admixed with papules and pustules, involving the central part of the face (figure no. 4).(30).

Figure no. 4. Rosacea-like eruption (atrophy, telangiectasias, papules and pustules) after abusive use of a potent topical corticosteroid on the face (Courtesy of dr. Raluca Popescu)

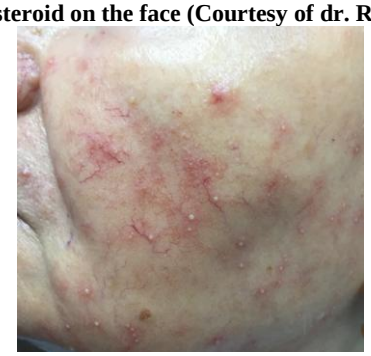

Moreover, after cessation of topical corticosteroid administration, the lesions tend to worsen, condition described as "topical steroid dependent face".(16,31)

Other causes of drug-induced rosacea-like eruption, such as topical immune modulators, epidermal growth factor inhibitors, vitamin B complex and vitamin D, calcium channel blockers, must be ruled out.(30)

6. Perioral dermatitis

This disorder is similar to the rosacea-like eruption, with erythematous follicular papules and pustules on a red background surrounding the mouth in individuals that overuse topical steroids on the face (figure no. 5).(14)

Figure no. 5. Perioral dermatitis after topical corticotherapy. (Courtesy of dr. Raluca Popescu)

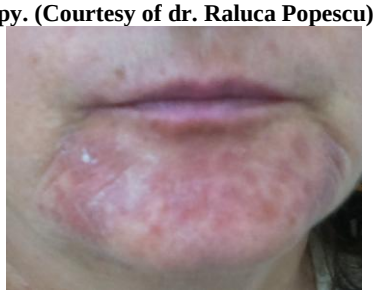

It can also be triggered by inhaled corticosteroids. Women are more frequently affected, but the condition can occur as well in children and men.(14,32) Other cutaneous eruptions such as cutaneous lupus erythematosus, irritative contact dermatitis, *lupus miliaris disseminatus faciei*, seborrheic dermatitis should be excluded.(33)

7. Purpura

Corticosteroid-induced purpura is a consequence of the loss of support around vessels from damaged collagen, dermal atrophy, which contribute to vascular wall fragility.(14,19,34) Clinical examination reveals purpuric macule and patches that can appear after minor trauma (figure no. 6).(35)

Figure no. 6. Purpura and pseudoscars after topical corticotherapy (Courtesy of dr. Gabriela Turcu)

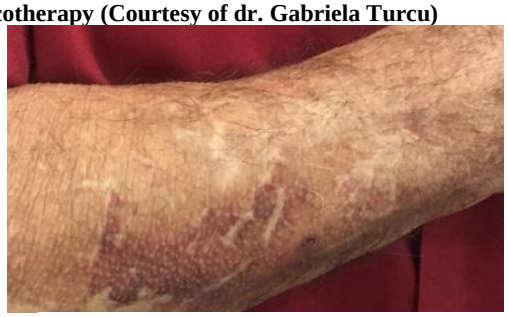

Other drugs, such as sulfonamides, thiazide diuretics, phenothiazines, furosemide have been associated with purpuric and hemorrhagic eruptions.(36)

8. Pseudoscars

Pseudoscars may appear on the background of atrophic skin with purpura and telangiectasia, mimicking actinic purpura of Bateman in older patients.(14) The lesions can have a stellate irregular shape, being commonly distributed over the extremities (figure no. 6).(14)

9. Delayed wound healing

Various factors are involved in delayed wound healing. First of all, epidermal atrophy and impaired reepithelization are the results of the steroid on the keratinocyte.(14,37) Moreover, dermal atrophy and striae are the consequence of decreased collagen production and intercellular matrix and telangiectasia and purpura appear because of the loss of support around vessels.(14,37) There is also a defect in the angiogenesis, regarding granulation tissue synthesis.(14,37)

10. Hypopigmentation

It may be the result of topical applied steroids due to their melanopenic property.(16) It may appear as a depigmented or hypopigmented macules at the site of chronic application that can resemble vitiligo or postinflammatory hypopigmentation (figure no. 7). The lesion can also be induced by intralesional or intraarticular administration of corticosteroids.

Figure no. 7. Hypopigmentation after topical corticotherapy. (Courtesy of dr. Cătălin Popescu)

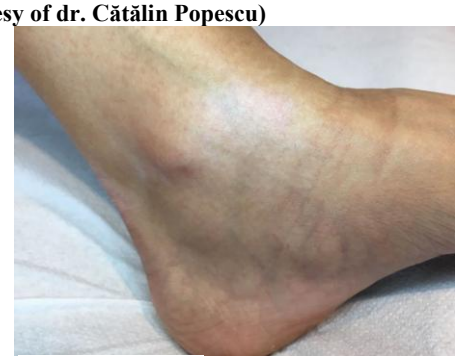

11. Hair disorders

Cushing syndrome may manifest as telogen effluvium, with diffuse hair loss.(38) Moreover, vellus hairs can accompany skin findings of "cushingoid aspect".(14)

12. Predisposition to cutaneous infections

Corticosteroids, through immunosuppressive properties, create favourable conditions for the development of various skin infections: pityriasis versicolor, dermatophytoses, candida infections.(14) Tinea incognito defines the abnormal aspect of a typical lesion of mycosis (tinea, which is initially described as an annular slightly elevated erythematous scaly plaque), after using topical steroids. Diaper dermatitis locally treated with local steroids for a long period may suffer granulomatous transformation, a disorder known as "*granuloma gluteale infantum*".(14)

CONCLUSIONS

The identification of the cutaneous adverse effects induced by glucocorticosteroids has a major importance in the dermatological practice.

REFERENCES

1. Nieman L. Pharmacologic use of glucocorticoids [Internet]. UPTODATE. [cited 2017 Dec 13]. Available from: https://www.uptodate.com/contents/pharmacologic-use-of-glucocorticoids?source=see_link#H2.
2. Dey VK. Misuse of topical corticosteroids: A clinical study of adverse effects. Indian Dermatol Online J. 2014;5(4):436-40.
3. Jackson S, LT NJ. Glucocorticoids. In: Bolognia J, Jorizzo J, Schaffer J, editors. Bolognia Dermatology. 3RD Editionş 2014. p. 2075-87.
4. Mehta A, Nadkarni N, Patil S, Godse K, Gautam M, Agarwal S. Topical corticosteroids in dermatology. Indian J Dermatology, Venereol Leprol. 2016;82:371-8.
5. Hopkins RL, Leinung MC. Exogenous Cushing's syndrome and glucocorticoid withdrawal. Endocrinol Metab Clin North Am. 2005;34:371-84.
6. Sahıp B, Celık M, Ayturk S, Kucukarda A, Mert O, Dıncer N, et al. Iatrogenic Cushing's Syndrome After Topical Steroid Therapy for Psoriasis. Indian J Dermatol. 2016;61(1):120.
7. Lause M, Kamboj A, Fernandez Faith E. Dermatologic manifestations of endocrine disorders. Transl Pediatr.

2017;6(4):300-12.
8. Stratakis CA. Skin manifestations of Cushing's syndrome. Reviews in Endocrine and Metabolic Disorders; 2016.
9. Dhar S, Seth J, Parikh D. Systemic side-effects of topical corticosteroids. Indian J Dermatol. 2014;59(5):460-4.
10. Coondoo A, Phiske M, Verma S, Lahiri K. Side-effects of topical steroids: A long overdue revisit. Indian Dermatol Online J. 2014;5(4):416-25.
11. Kerner M, Ishay A, Ziv M, Rozenman D, Luboshitzky R. Evaluation of the pituitary-adrenal axis function in patients on topical steroid therapy. J Am Acad Dermatol. 2011;65:215-6.
12. Nieman LK. Consequences of systemic absorption of topical glucocorticoids. J Am Acad Dermatol. 2011;65(1):250-2.
13. Sahana PK, Sarma N, Sengupta N, Somani PS. A florid case of Iatrogenic Cushing's syndrome induced by topical steroid with osteoporosis and hypogonadism. Indian J Dermatol. 2015;60(4):420.
14. Hengge UR, Ruzicka T, Schwartz RA, Cork MJ. Adverse effects of topical glucocorticosteroids. J Am Acad Dermatol. 2006;54(1):1-15.
15. Rathi S. Abuse of topical steroid as cosmetic cream: A social background of steroid dermatitis. Int J Dermatol. 2006;51:154-5.
16. Manchanda K, Mohanty S, Rohatgi P. Misuse of Topical Corticosteroids over Face: A Clinical Study. Indian Dermatol Online J. 2017;8(3):186-91.
17. Laws PM, Young HS. Topical treatment of psoriasis. Expert Opin Pharmacother. 2010;11(12):1999-2009.
18. Schoepe S, Schäcke H, May E, Asadullah K. Glucocorticoid therapy-induced skin atrophy. Exp Dermatol. 2006;15(6):406-20.
19. Abraham A, Roga G. Topical steroid-damaged skin. Indian J Dermatol. 2014;59(5):456-9.
20. Cornell R, Stoughton R. The use of topical steroids in psoriasis. Dermatol Clin. 1984;2:397-408.
21. Johnson E, Groben P, Eanes A, Iyer P, Ugoeke J, Zolnoun D. Vulvar Skin Atrophy Induced by Topical Glucocorticoids. J Midwifery Women's Heal. 2012;57(3):296-9.
22. Rogalski C, Haustein UF, Glander HJ, Paasch U. Extensive striae distensae as a result of topical corticosteroid therapy in psoriasis vulgaris [4]. Acta Derm Venereol. 2003;83(1):54-5.
23. Gilmore SJ, Vaughan BL, Madzvamuse A, Maini PK. A mechanochemical model of striae distensae. Math Biosci. 2012;240(2):141-7.
24. Nigam PK. Striae Cutis Distensae. Int J Dermatol. 1989;28:426-8.
25. Jabbour SA. Cutaneous manifestations of endocrine disorders: A guide for dermatologists. Am J Clin Dermatol. 2003;4:315-31.
26. Wheeler H, Black J, Webb S, Shen H. Dehiscence of corticosteroid-induced abdominal striae in a 14-year-old boy treated with bevacizumab for recurrent glioblastoma. J Child Neurol. 2012;27(7):927-9.
27. Zaenglein A, Thiboutot D. Acne vulgaris. In: Bolognia J, Jorizzo J, Schaffer J, editors. Bolognia Dermatology. 3rd Editio; 2014. p. 545-59.
28. Hettmannsperger U, Tenorio S, Orfanos CE, Detmar M. Corticosteroids induce proliferation but do not influence TNF- or IL-1 B-induced ICAM-1 expression of human dermal microvascular endothelial cells in vitro. Arch Dermatol Res. 1993;285(6):347-51.
29. Oakley A. Telangiectasia. [Internet]. [cited 2017 Dec 12]. Available from: https://www.dermnetnz.org/topics/telangiectasia/.
30. Rezakovic S, Mokos ZB, Pastar Z. Drug-Induced Rosacea-like Dermatitis. Acta Dermatovenerologica Croat. 2016;24(1):49-54.
31. Bhat YJ, Manzoor S, Qayoom S. Steroid-induced rosacea: a clinical study of 200 patients. Indian J Dermatol. 2011;56:30-2.
32. Hasan Hafeez Z. Perioral dermatitis: An update. Int J Dermatol. 2003;42:514-7.
33. Lipozenčić J, Hadžavdić S. Perioral dermatitis. Clin Dermatol. 2014;32(1):125-30.
34. Bork K. Cutaneous adverse drug reactions. In: Burgdorf WHC, Plewig G, Wolff HH, Landthaler M, editors. Braunn-Falco's dermatology. 3rd ed. 2009. p. 460.
35. Shinkai K, Fox L. Cutaneous vasculitis. In: Bolognia J, Jorizzo J SJ, editor. Bolognia Dermatology. 3rd ed; 2014. p. 389.
36. Braunn-Falco O, Plewig G, Wolff H, Burgdorf W. Reactions to medications. In: Braun-Falco O, Plewig G, Wolff H, Burgdorf W, editors. Braunn-Falco's dermatology. 2nd ed; 2000. p. 418.
37. Truhan A, Ahmed A. Corticosteroids: a review with emphasis on complications of prolonged systemic therapy. Ann Allergy. 1989;62(5):375-91.
38. Lefkowitz EG, Cossman JP, Fournier JB. A Case Report of Cushing's Disease Presenting as Hair Loss. Case Rep Dermatol. 2017;9(1):45-50.