RARE CASE OF CONTRALATERAL AXILLARY LYMPH NODE METASTASIS IN BREAST CANCER

CIPRIAN TĂNĂSESCU [1], MIHAI FAUR[2], DAN BRATU[3], DENISA TĂNĂSESCU[4]

[1,2,3]"Lucian Blaga" University of Sibiu, Emergency County Clinical Hospital, Sibiu, [4]Emergency County Clinical Hospital, Sibiu,

Keywords: *breast cancer, contralateral axillary lymph node metastasis*

Abstract: *Breast cancer is the most common form of cancer in females, 1 out of 8 women are at risk of developing breast cancer during their lifetime. Approximately 5% of mammary cancers develop due to mutation in BRCA1 or BRCA2 genes. Although the risk factors are not different from those of unilateral cancer, their individual or combined intake is difficult to assess. The authors present the case of a 64-year-old woman with left breast cancer who received neoadjuvant chemotherapy, followed by Madden left mastectomy, with approximately 1 year postoperative decubitus controllateral lymph node. Right axillary lymphadenectomy has been practiced with favourable evolution.*

INTRODUCTION

Generally, cancer is an obsessive problem of the society we live in. The impact of breast cancer on public health is a significant segment of pathology with a large scale in recent years. In our country, breast cancer is the most commonly diagnosed cancer and the leading cause of female mortality.

Breast cancer is the most common malignant tumour seen in women, with increasing mortality and morbidity, although there have been remarkable advances in diagnosis and therapeutic management over the recent years. The metastasis present in the breast neoplasm is predominantly localized in bones or at visceral, pulmonary, cerebral or hepatic level. Remote metastasis in the contralateral axilla without affecting the contralateral breast is extremely rare.(1,2)

Over time, breast cancer treatment has been improved year after year, leading to an increase in survival, but also in postoperative quality of life.

Epidemiology of cancers provides important data on incidence, dynamic evolution of new cases, population groups at risk. Epidemiology applies statistical techniques to study disease in a given population by establishing interrelations or explanatory patterns and contributing to addressing major public health problems. Analytical epidemiology studies are carried out in several stages: defining the geographical area, setting the time interval and indicating the diagnostic methods. The resulting data is recorded and processed through population and cancer registries. Analytical epidemiology studies groups of individuals with a risk of cancer by exposure to risk factors, prospectively and retrospectively.(2)

Breast cancer is the second most common form of cancer worldwide and by far the most common cancer in women, with approximately 1.67 million new cases of cancer diagnosed in 2012 (25% of all cancers). It is the most common cancer in women both in less developed regions (883,000 cases) and in the most developed (794,000) ones. Incidence rates vary almost four times across different regions of the world, with rates ranging from 27 to 100,000 in West Africa and East Asia to 92 in North America.(3)

Surgery remains the main way to treat breast cancer and other neoplasms, along with radiotherapy, hormone therapy, immunotherapy and chemotherapy.(4,5)

Depending on the stage of cancer, the surgeon must choose from the various surgical procedures, the most appropriate treatment.

In early breast cancer, conservative surgical therapy has earned a well-deserved place, being one of the most important advances in the surgical treatment of breast cancer.

Halsted and Meyer were the first to achieve successful results with radical mastectomy, thus introducing the modern era of surgical treatment for breast cancer.(1,6)

Axillary lymph node dissection provides accurate prognostic information. The status of the axillary lymph nodes remains the most important prognostic factor: survival at 10 years is 70% at No, 40% at 1-3 positive ganglia and below 20% in patients with 4-10 positive ganglia.(7,8,9)

The axillary lymph node should be large enough to allow for identification of possible lymph node metastases when they exist, but not to be mutilated by the resection of the small pectoral. It must allow a correct assessment of the condition of the axillary lymph node impregnation.

The axillary lymph node can be performed by an independent oblique axillary incision or by prolonging the mammary incision in tumours located in external dials. The removal of the lymph nodes has a curative purpose and the correct setting of the stage.(10,11)

CASE REPORT

We present the case of a 64-year-old patient, known with a history of left breast neoplasm for which a Madden-modified radical mastectomy with left lymph nodes evidement was performed one year ago. At that time, chemotherapy was practiced according to oncology protocols. The patient presented in the Clinic of Surgery for the appearance of a right axillary tumour of approximately 4 cm, well defined, mobile up and down, spontaneously not painful and on palpation, occurring about 3 months ago, which progressively increased in size.

The patient performed axillary ultrasound showing a non-infiltrative adenopathic block in the supra and underlying

[1]Corresponding author: Ciprian Tănăsescu, B-dul Corneliu Coposu, Nr. 2-4, Sibiu, România, E-mail: tanasescuciprian@yahoo.fr, Phone: +40722 490048
Article received on 20.07.2018 and accepted for publication on 22.11.2018
ACTA MEDICA TRANSILVANICA December 2018;23(4):65-66

plans with Doppler vascular signal present. Biochemically, no significant pathological changes were noticed.

After a proper preoperative preparation, surgery was performed on October 3, 2017, intraoperatively evidencing a right axillary adenopathic block (figure no.1), for which it was decided and practiced right total axillary lymphadenectomy (figure no. 2), drainage, while sending the surgical specimen to histopathological examination.

Figure no. 1. Right axillary adenopathic block

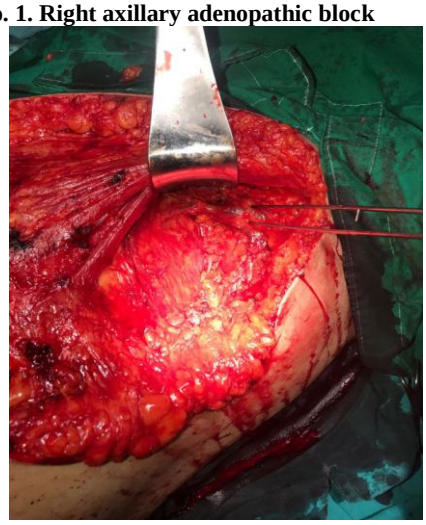

Figure no. 2. Right total axillary lymphadenectomy

Favourable postoperative progression, balanced hemodynamic and respiratory status, with no reaction and under healing wound, with permeable drain tube with minimal lymph drainage, suppressed 8 days postoperatively.

The histopathological result of the surgical piece revealed massive lymph nodes metastases of invasive breast carcinoma in 12 of the 14 lymph nodes collected from the axilla and at the level of the Rotter interpectoral lymph node sampled intraoperatively. Immunohistochemistry: 80% estrogen receptors, 30% progesterone receptors. HER2 receptors - negative (0), Ki67 – 30%.

DISCUSSIONS

The current concepts envisage a "multimodal" treatment adapted to each stage of a systemic disease. Breast cancer therapy includes at least three methods: surgical, medical, radiological. In our case, although surgical treatment was radical by performing Madden modified radical mastectomy and axillary lymph node evidement, the patient completely having followed all the post-operative chemotherapy sessions, this contralateral axillary recurrence occurred.

One can discuss about the appearance of relapse (reappearance, return of a disease after it has clinically healed, relapse.) or about remote metastasis (secondary localization away from the primary focus of a disease). Taking into account the fact that the patient was not considered to be cured after completing the multimodal treatment, we interpreted this contralateral axillary tumour as a distal metastasis of the primary tumour. The histopathological result confirmed our hypothesis.

CONCLUSIONS

Cancer, in general, is an obsessive problem of the society in which we live; therefore, the early detection of the disease, the multidisciplinary treatment and the patient's constant follow-up should take place according to some national protocols.

Remote metastasis in the contralateral axilla without affecting the contralateral breast is extremely rare, but it should be taken into consideration in the periodic evaluation of the patient with breast cancer who has undergone all the multimodal treatment sequences.

REFERENCES

1. Meyer W. An improved method of the radical operation for carcinoma of the breast. New York Medical Record. 1894;46:746-749.
2. Mazilu V, Ghelase Sm, Badea P, Ghelase F, Vilcea V. Aspecte epidemiologice în cancerul mamar. Chirurgia, Bucuresti. 2003;98:319.
3. http://globocan.iarc.fr. Accessed on 13.06.2018.
4. Goldhirsch A, Wood WC, Coates AS, et al. Strategies for subtypes—dealing with the diversity of breast cancer: highlights of the St Gallen International Expert Consensus on the Primary Therapy of Early Breast Cancer 2011, Ann Oncol. 2011;22:1736-1747.
5. The Cancer Genome Atlas Network Comprehensive molecular portraits of human breast tumours, Nature. 2012;490:61-70.
6. Halsted WS. The Results of Operations for the Cure of Cancer of the Breast Performed at the Johns Hopkins Hospital from June, 1889, to January, 1894. Annals of Surgery. 1894;20(5):497-555.
7. http://www.ghid-cancer.ro/info/imunoterapia-in-cancer. Accessed on 12.04.2018.
8. Smidt ML, Kuster DM, van der Wilt GJ, Thunnissen FB, Van Zee KJ, Strobbe LJ. Can the Memorial Sloan-Kettering Cancer Center Nomogram predict the likelihood of nonsentinel lymph node metastases in breast cancer patients in the Netherlands? Ann Surg Oncol. 2005;12(12):1066-1072.
9. Specht MC, Kattan MW, Gonen M, Fey J, Van Zee KJ. Predicting nonsentinel node status after positive sentinel lymph biopsy for breast cancer: clinicians versus nomogram. Ann Surg Oncol. 2005;12(8):654-659.
10. Winchester DP, Cox JD. Standards for Breast-Conservation Treatment in CA Cancer J Clin, May/June 1992;42(3):134-162.
11. Bland KI, Copeland E. III – Breast in "Principles of Surgery", Sixth Edition, sub red. Schwartz S. I. Ed. McGraw-Hill, Inc; 1994. p. 531-594.