SURGICAL MYOCARDIAL REVASCULARISATION CONCOMITANT WITH ASCENDING AORTA TO BIFEMORAL BYPASS IN A PATIENT WITH SEVERE GENERALISED ATHEROMATOSIS (CASE REPORT)

RADU BĂLĂU[1], MARIUS HARPA[2], CLAUDIU GHIRAGOSIAN[3], HUSSAM AL HUSSEIN[4] TUDOR CĂPÎLNĂ[5], HORAŢIU SUCIU[6]

[1,2,3,4,5,6]*University of Medicine and Pharmacy Târgu-Mureş,* [1,2,3,4,6]*Emergency Institute for Cardiovascular Diseases and Transplantation Târgu Mureş*

Keywords: *concomitant heart and legs revascularisation*

Abstract: *Generalised atheromatosis is the leading cause of mortality and morbidity in Western Europe and the United States. The main determinations are cardiac, cerebral and lower limbs. Usually, they require serial surgical procedures. We report a case of a 65 year-old patient with severe tricoronary stenosis and high abdominal aorta occlusion. The impossibility of using the abdominal aorta as an inflow source for revascularisation of the lower limbs and the severity of symptoms required concomitant myocardial and lower limb revascularisation using the ascending aorta as an inflow source for both procedures. The postoperative outcome was favourable, without complications, the patient being discharged at 9 days postoperatively. At first and 6 month postoperative follow-up, the patient was asymptomatic. In conclusion, the ascending aorta is a good inflow source to the lower limb revascularisation, and the combination of the two procedures can be performed in selected cases with good results.*

INTRODUCTION

Systemic atherosclerosis is a pathology characterised by the reduction of vascular lumen due to lipid deposits that form plaques of atheroma in the arterial walls, causing reduction of blood supply to tissues and generating ischemic type disorders.(1) This pathology is the main cause of mortality and morbidity in developed countries.(2)

The association in the context of generalized atherosclerosis of coronary heart disease with aortic - iliac obstructive disease is quite common in clinical practice.(3,4,5,6) The surgical management of these patients usually involves staged revascularisation interventions, most often myocardial revascularisation preceding lower limb revascularisation. The infrarenal abdominal aorta is the primary source for inflow for aortic-iliac occlusive disease surgical management.(7) The impossibility of using abdominal aorta as an inflow source in a patient with severe lower limb ischaemia and severe coronary stenosis may require concomitant revascularisation of the myocardium and lower limbs using the ascending aorta as the source of inflow for both femoral and coronary arteries.(8,9)

CASE REPORT

A 65-year-old male, high-smoker, dyslipidemic, hypertensive was admitted to the Cardiovascular Surgery Clinic, complaining about intermittent claudication in the lower limbs with a dysbasic index <20 m, and constrictive precordial pain at low exercise.

The objective examination on admission revealed bilateral absence of pulses at the femoral and below femoral level, pale teguments, with bilateral low temperature at the lower limbs, no trophic modifications. The patient presents rhythmic heartbeats, without precordial or cervical murmurs, on the heart listening. The arterial blood pressure at admission was 130/60 mmHg, the patient being on treatment with beta blocker, nitrite, angiotensin converting enzyme inhibitors (IECA), diuretic.

Electrocardiogram (ECG) on admission showed a sinus tachycardia, ventricular rate of 106 bpm, Q wawe on D III, a ventricular fibrillation (VF) derivations, interval between S wave and T wave on electrocardiogram (ST) depression in V5 and V6 derivations, isolated ventricular premature beats.

Echocardiography on admission revealed a heart with normal cavities, with effective left ventricle, left ventricular ejection fraction (LVEF) 55%, and no valvulopathies.

Coronarography revealed a dominant right coronary system, left main trunk with no stenosis, 80% left anterior descending artery (LAD) calcified stenosis, 70% obtuse marginal artery (OM) I stenosis, right coronary artery (RCA) occlusion on origin, with controlateral recharge of posterior interventricular artery (figure no. 1).

Figure no. 1. Coronarographic aspect, with LAD and CX stenosis and RCA occlusion with retrograde reperfusion

[2]Corresponding author: Marius Harpa, Str. Gheorghe Marinescu, Nr 50, Târgu-Mureş, Jud. Mureş, E-mail: cardiochirurgiemures@gmail.com, Phone: +40740 751422
Article received on 03.04.2019 and accepted for publication on 03.06.2019
ACTA MEDICA TRANSILVANICA June 2019;24(2):41-43

Peripheral arteriography showed abdominal aorta occlusion immediately below renal arteries emergence, with poor loading through arterial collateral of the right deep femoral artery. The left lower limb vascularisation was not visualized. (figure no. 2)

Figure no. 2. Arteriographic aspect showing infrarenal aortic occlusion

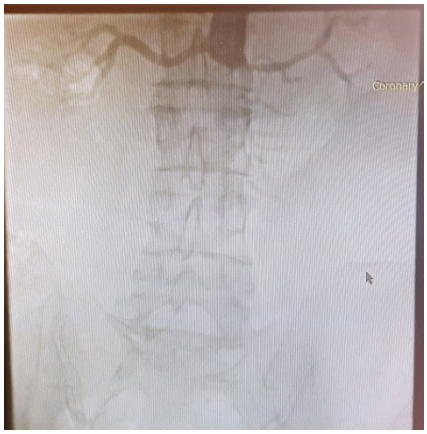

In order to complete the investigations and establish the therapeutic decision, abdomino-pelvic angio computer tomography was performed, which revealed infrarenal abdominal aorta occlusion extended to bilateral common iliac arteries, bilateral external iliac arteries and common bilateral femoral arteries, with repermeabilisation of the distal segment of common femoral arteries; stenoses up to 50% in the middle third of bilateral superficial femoral arteries; severe stenosis in the proximal third of bilateral anterior and posterior tibial arteries (figure no. 3.)

As a result of these paraclinical findings, considering the impossibility of using the infrarenal abdominal aorta as an inflow source for revascularisation of the inferior limbs, the unsatisfactory results reported on medium and long term follow up of axial-bifemoral extraanatomic revascularisation, as well as the presence of severe associated coronary and peripheral lesions, it was decided to perform simultaneous interventions of myocardial and lower limb revascularisation, using ascending aorta as an inflow source.

Figure no. 3. Angio CT image showing infrarenal aortic occlusion with femoral repermeabilisation

The intervention was performed by 5 surgeons who worked in parallel in two teams to reduce the duration of the surgery. The intervention started with a longitudinal presternal incision, followed by medial sternotomy and longitudinal pericardotomy for heart exposure. In parallel, longitudinal incisions centered on the common femoral arteries and their bifurcations were performed. At the inspection and palpation of the structures, a severe ateromatous ascending aorta and also common, deep and superficial bilateral femoral arteries with atherosclerotic walls are detected.

Subcutaneous tunnelling of a Dacron bifurcated prosthesis with a diameter of 10x10x10 mm was performed in front of rectus abdominis muscle on the right side, from the ascending aorta to the bifurcation of the bilateral femoral artery.

The harvested left internal mammary artery had an unsatisfactory flow and calibre, and for this reason it was not used as a conduct.

On partial cardiopulmonary bypass, with arterial cannulation in the ascending aorta and venous cannulation with a two-stage cannula inserted through the right atrial appendage, the ascending aorta was clamped and cardioplegic cardiac arrest was performed. Subsequently, we performed successive anastomosis of autologous internal saphenous vein grafts on left anterior descending artery, first obtuse marginal artery and posterior interventricular artery from the right coronary artery, distal of the obstruction site. Given severe atheromatosis of the ascending aorta, to avoid side clamping at this level and the risk of rupture or atherosclerotic embolism, it was decided to perform proximal anastomosis of the bifurcated Dacron prosthesis and saphenous vein graft previously anastomosed to obtuse marginal artery, on the arrested heart.

In parallel, after endarterectomy of bilateral common femoral arteries bifurcation, at this level we performed distal anastomosis of the two ends of bifurcated Dacron prosthesis. After de-airing the prosthesis, the aorta was unclamped, with the resumption of cardiac activity. Also, because of atheromatosis of the ascending aorta, the proximal end of the venous graft previously anastomosed to the left anterior descending artery and posterior interventricular artery were anastomosed end-to-side to Dacron prosthesis. Measurements performed with the flowmeter showed adequate flow rates on both venous grafts and femoral arteries. The cardio-pulmonary bypass was suppressed, the patient being hemodynamically stable with a reduced dose of Dopamine, which was removed 5 hours postoperatively. The aortic cross clamping time was 107 minutes, and the cardio-pulmonary bypass time was 148 minutes. The total duration of the intervention was 4 hours and 45 minutes.

Figure no. 4. Intraoperative aspect with proximal anastomosis of two venous saphenous grafts in Dacron vascular graft

RESULTS

The postoperative evolution was favourable, the patient being extubated 6 hours postoperatively. Thoracic drainage was 325 ml within the first 24 hours, and the thoracic drainage tubes were suppressed later. A serum drainage of the left femoral wound of approximately 200 ml per day persisted for 6 days postoperatively, which diminished and subsequently disappeared after administration of Ibuprofen. The bacteriological examination in the drained liquid was negative. Postoperative echocardiography showed a left ventricle with no contractility changes, with LVEF 55%, without pericardial effusion. Postoperatively, the patient presented a bilateral well-beated femoral and popliteal pulse, and poorly perceptible, but with the Doppler signal present in the bilateral posterior tibial and dorsal pedal arteries.

The patient was discharged at home after one day of stay in the ICU and 9 days of total postoperative hospitalisation.

Clinical, echocardiographic and arterial Doppler follow-up was performed at one month and 6 months postoperatively, the patient being asymptomatic, without echocardiographic changes and with Doppler signal present to the lower limb extremities.

DISCUSSIONS

Surgical revascularisation of the myocardium, respectively surgical revascularisation of the lower limbs, as separate procedures represent routine interventions in cardiovascular surgery. In most of the cases, the inflow source for lower limb revascularization in aortic-iliac occlusive disease is provided by the infrarenal abdominal aorta, and in the case of associated coronary obstructive disease, myocardial revascularisation usually precedes peripheral revascularisation. When abdominal aorta cannot be used as an inflow source (abdominal aortic hypoplasia, high occlusion of the abdominal aorta), taking into account that medium and long term results in the use of the axillary artery as the source of inflow were disappointing (10,11), the ascending aorta becomes an option taken into consideration. Association of severe tricoronary lesions requiring revascularisation increases the intervention complexity by increasing surgery duration and the number of anastomoses. Other factors that led to the increased complexity of the operation were severe atheromatosis from the ascending aorta level which determined the increase of the aortic clamping time by the necessity of making two proximal anastomoses with the heart arrested, and the severe calcifications at the level of bifurcation of both common femoral arteries, requiring extensive endarterectomies and wider anastomoses. Also, severe ascending aorta atheromatosis required the use of aorto-bifemal bypass prosthesis as the location of proximal anastomosis for saphenous veins grafted to LAD and RCA, aspect which we have not previously found in the specialized literature. The subcutaneous tunnelling of aorto-bifemoral bypass prosthesis, in front of rectus abdominis muscle, is easy to perform, eliminating the disadvantage of the necessity of opening the peritoneal cavity and the complications that may result from this procedure.(12) The ascending aorta is a noncompresible inflow site and, in comparison with the axillar artery, flow to the arm is not jeopardized and subclavian artery stenosis is not a contraindication for the procedure.(13)

CONCLUSIONS

In conclusion, the ascending aorta is a good source of inflow for revascularization of the lower limbs in the case of impossibility of using the abdominal aorta, and the combination of myocardial and peripheral surgical revascularization can be performed in selected cases with very good results.

REFERENCES

1. Aschoff L. Introduction. In: Cowdry EV, editor Arteriosclerosis: A Survey of the Problem. New York: Macmillan; 1933.
2. Beaglehole R, Magnus P. The search for new risk factors for coronary heart disease: occupational therapy for epidemiologists? Int J Epidemiol.20020;31:1117-1122.
3. Hertzer NR, Beven EG, Young JR, O'Hara PJ, Ruschhaupt WF 3d, Graor RA, et al. Coronary artery disease in peripheral vascular patients. A classification of 1000 coronary angiograms and results of surgical management. Ann Surg. 1984;199:223-233.
4. Jamieson WRE, Janusz MT, Miyagishima RT, Gerein AN. Influence of ischemic heart disease on early and late mortality after surgery for peripheral occlusive vascular disease. Circulation. 1982;66(Suppl 1):92-97.
5. Sukhija R, Aronow WS, Yalamanchili K, Sinha N, Babu S. Prevalence of coronary artery disease, lower extremity peripheral arterial disease, and cerebrovascular disease in 110 men with an abdominal aortic aneurysm. Am J Cardiol. 2004; 94:1358-1359.
6. Dieter RS, Tomasson J, Gudjonsson T, et al. Lower extremity peripheral arterial disease in hospitalized patients with coronary artery disease. Vasc Med. 2003;8:233-236.
7. Dimick JB, Cowan JA Jr., Henke PK, Wainess RM, Posner S, Stanley JC et al. Hospital volume-related differences in aorto-bifemoral bypass operative mortality in the United States. J Vasc Surg. 2003;37:970-975
8. Suma H, Sato H, Fukumoto H, Takeuchi A. Combined revascularization of coronary and femoral arteries: a propsed alternative. Ann Thorac Surg. 1989;48:434-6.
9. Inciura D, Benetis R. Simultaneous coronary artery bypass grafting and vascular operations: early and mid-term results. J Cardiovasc Surg. 2006;47:337-347.
10. Martin D, Katz SG. Axillofemoral bypass for aortoiliac occlusive disease. Am J Surg. 2000 Aug;180(2):100-3.
11. Schneider JR, McDaniel MD, Walsh DB, Zwolak RM, Cronenwett JL. Axillofemoral bypass: outcome and hemodynamic results in high-risk patients. J Vasc Surg. 1992 Jun;15(6):952-62; discussion 962-3.
12. Autschbach R, Falk V, Walther T, Vettelschoss,M, Diegeler, A, Dalichau H et al. Simultaneous coronary bypass and abdominal aortic surgery in patients with severe coronary disease–indication and results. Eur J Cardiothorac Surg. 1995;9:678-68
13. Baird RJ, Ropchan, GV,. Oates TK, Weisel RD, Provan JL. Ascending aorta to bifemoral bypass-a ventral aorta. Journal of vascular surgery. 1986;3(3):405-410.