CLINICAL-EPIDEMIOLOGICAL CHARACTERISTICS OF SOFT TISSUE TUMOURS. STATISTICAL STUDY ON A SERIES OF 312 OPERATED SOFT TISSUE TUMOURS

SANDA DURA[1]

[1] *"Lucian Blaga" University of Sibiu*

Keywords: *soft tissue tumours, epidemiology, malignancy, surgical cure, prognosis*

Abstract: *The aim of the paper is to describe the clinical and morpho-histological characteristics as well as the prognosis of soft tissue tumours, with reference to 312 cases of soft tissue tumours operated within a general surgery service. The parameters studied were the location, age, sex, benign / malignant nature and surgical cures type. Immediate and one-year follow-up results are presented. The results indicate that soft tissue tumours are a common pathology in surgical practice, and can be resolved in over 90% of cases in outpatient setting, in local anaesthesia and with low medical costs. Simple excision of the tumour provides for the safe healing of benign formations with an insignificant share of local recurrences, solvable by simple re-intervention. Excision due to oncological reasons provides an important percentage of cure, but late evolution depends on the degree of local invasion, the histopathological nature of the tumour, the localization of the formation, the time of intervention, and the age of the patient.*

INTRODUCTION

Soft tissues comprise all extraskeletal tissue structures of the limbs and the chest wall, which belong to the class of connective tissues, except for the muscles, tendons, ligaments, cartilage and bones. Thus, soft tissue tumours include: lipomas, fibromas, pericytoma, histiocytoma, vascular tumours (e.g. angioma) and undifferentiated tumours (which cannot be related to normal tissue, e.g., synovial tumours).(1,2)

The degree of malignancy of the tumour is determined by the summation of the mitotic activity, the presence of necrosis and the degree of cell differentiation (1,2), but the age of the patient, the location of the tumour (superficial or deep) or consistency of the formation also play an important part. Only 1% of soft-tissue tumours are malignant, and over 90% of them have no signs of metastatic dissemination.(3,4)

AIM

The purpose of the paper is to describe the clinical and morpho-histological features by evaluating a series of 312 soft tissue tumours operated within a general surgery service.

MATERIALS AND METHODS

The study group consists of 312 cases of soft tissue tumours diagnosed and operated within the General Surgery Department of Brad Municipal Hospital. The demographic and clinical parameters of casuistry are shown in table no. 1.

RESULTS AND DISCUSSIONS

At the head and neck level, 116 (37.1%) cases were recorded. Benign tumours, 85 (73.3%), were sebaceous cysts (42 cases), lipomas (18 cases), fibromas (3 cases), serous cysts (4 cases), nevi (6 cases), pyogenic granuloma (4 cases), hyperkeratosis papilloma (4 cases), melanocytic and keratotic nevi (4 cases).Malignant tumours in 31 cases (26.7%) included metastases in cervical ganglia (5 cases), basal cell epithelioma (10 cases), spino-cellular epithelioma (13 cases), malignant melanoma (2 cases), cystic adenoid basal cell carcinoma (1 case). There is an over-morbidity of the male sex and a progression of incidence along with age, the incidence identified in our study being close to that quoted by the specialty literature.(5-8)

Tumours with thoracic localization accounted for 76 cases (24.3%). The histopathological examination identified 66 benign tumours (84.5%), represented by sebaceous cysts (26 cases), lipomas (20 cases), pigmented nevi (9 cases), external cavernous hemangioma (5 cases), papilloma (6 cases). 10 (15.18%) malignant tumours were metastasis in axillary lymph nodes (4 cases), basal cell epithelioma (1 case), schwannoma Antoni A (1 case), fibrosarcoma (2 cases), squamous papilloma (2 cases). There is a predominance of female sex and a degree of relative uniformity in the incidence of soft tissue tumours in the age decades over 40.(3,4,8,9)

Figure no. 1. Topography of tumours in relation to sex

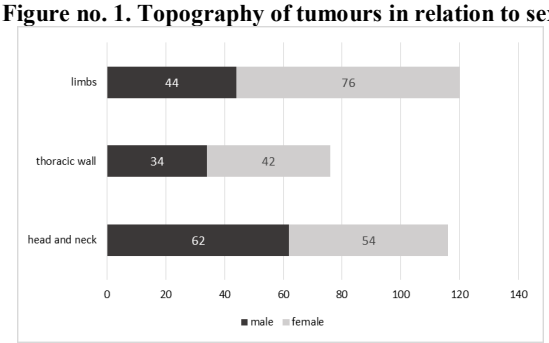

Tumours of the extremities were represented by 120 cases (38.4%). The histopathological structure consisted of 114 (94.8%) benign tumours: synovial cysts (10 cases), serous cysts (4 cases), tendinous cysts (14 cases), lipomas (16 cases), helomas (18 cases), nevi (4 cases), warts (4 cases), pyogenic granuloma (4 cases), fibroma (3 cases), foreign body granuloma (4 cases), capillary hemangioma (3 cases), teleangiectatic granuloma (2 cases), angiomas (3 cases), dermoid cyst (3 cases), chondromas (6 cases).

[1]Corresponding author: Sanda Dura, Str. Lucian Blaga, Nr. 2A, 550169, Sibiu, România, E-mail: sanda.dura@yahoo.com, Phone: +40728 856116
Article received on 23.04.2019 and accepted for publication on 03.06.2019
ACTA MEDICA TRANSILVANICA June 2019;24(2):70-72

Table no. 1. Clinical and epidemiological characteristics of soft tissue tumours (nr of cases)

Tumour localisation	Tumour type		Gender		Age (years of age)						
	B	M*	M**	F	≤20	20—29	30-39	40-49	50-59	60-69	≥70
Head and neck	85 (73,3%)	31 (26,6%)	62	54	4	8	14	21	26	23	20
Thoracic wall	66 (84,9%)	10 (15,1%)	34	42	3	7	9	14	17	14	12
Limbs	114 (84,8%)	6 (5,2%)	44	70	12	9	34	15	21	21	8

B-benign; M*-malign; M**-male; F-female

Malignant tumours with localization at extremities' level were 6 (5.2%) and were represented by fibrosarcoma (2 cases), schwannomas (2 cases), malignant melanoma (1 case) and schwannoma Antony A (1 case). There was a predominance of female sex and an increased incidence of tumours in age decades of 30-39 and over 50 years.(3,4,8,9)

Figure no. 2. Benign/malignant nature of the tumour according to localization

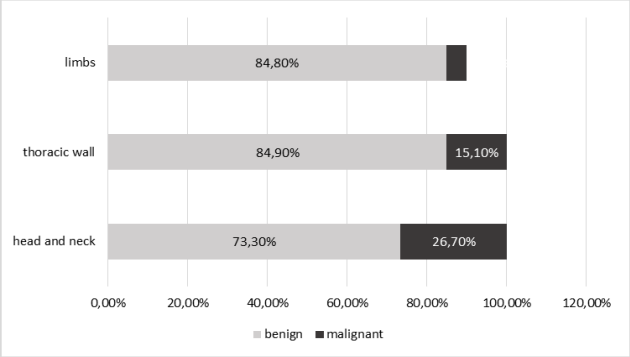

Figure no. 3. Tumour distribution according to patient age and location

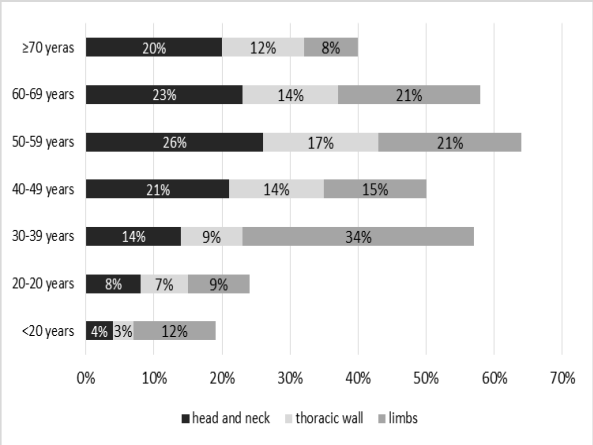

The surgical cure of the tumours was performed by surgical intervention in 86 cases (27.5%) and in ambulatory surgery for small surgeries or in outpatient surgery in 226 cases (72.1%). Thus, the study demonstrates literature data regarding the opportunity of small surgical interventions in small tissue tumours surgery.(8.9)

Of the group of patients with soft-tissue tumours, 66 cases (21.1%) were hospitalized either due to the degree of surgery or reduced geographical accessibility (long distance to the hospital unit) or insufficient family medicine practices in rural areas.(8,9)

General anaesthesia was used by oro-tracheal intubation for interventions in lip and fascial tumours (7 cases), spinal anesthesia (25 cases) and locoregional anesthesia (280 cases). In all cases, regional adenopathy was evaluated.

The tumour formations were excised with a safe area of 0.5 to 5 cm. All suspected formations were excised without tumour maltreatment and were sent for histopathological examination. We performed oncology-based interventions and significant tissue sacrifice in lower lip tumours, with plastic observance of the lip, with or without ganglionic evidence. For certain or suspected malignant tumours, the electric knife was routinely used.

There were no intraoperative complications, and perioperative complications were negligible. There was no intraoperative or postoperative early death attributed to surgery.

There have been 3 recurrences in facial sebaceous cysts and 3 recurrences of lipomas, followed by surgical re-intervention and definitive healing.

47 cases of malignant tumours (15%) were identified in the studied group. Malignancy assessment based on location indicated: 26.7% malignant tumours with cervical and cephalic localization, 15% malignancy in cases with thoracic localization and 5% malignancy in soft tumours of the extremities. Histo-pathologically, 44 of the 47 cases of malignant tumours were in stage I and 3 cases in stage II (regional tumour adenopathies). After the histopathological result was communicated and the patient was informed, the health education of the patient focused on the disease was done and the oncological observational sheet was drawn up, establishing the pace of the clinical check-ups.(10)

A total of 18 patients were referred to a regional oncology institute and 8 patients were directly monitored by the Department of Oncology of the local hospital. No case required surgical re-intervention. 6 patients followed radiotherapy and 3 patients received chemotherapy.

For the study group, postoperative outcomes were as follows:

- 9 patients with cervical and axillary lymph nodes died in the next 6-12 months due to primitive cancer tumour progression;
- 3 patients with malignant melanoma died in the first two years of surgery due to regional and remote metastases (pulmonary, hepatic or cerebral);
- a patient with lower lip spine cell epithelium died 2 years after surgical cure of the tumour through pulmonary and bone metastases.

The rest of the patients with malignant soft tissue tumours operated were further monitored by regular check-ups at 3-6-12 months.

CONCLUSIONS

Soft tissue tumours are a frequent pathology in surgical practice and require a thorough knowledge of local signs that indicate the transformation of the tumour to malignancy. All soft tissue tumours diagnosed in any clinical service should be referred to surgical consultation, and collaboration with the dermatologist is salutary.

Simple excision of the tumour provides for the safe healing of benign formations with a negligible share of local recurrences, solvable by simple re-intervention. Excision due to

oncological reasons provides an important percentage of cure, but late evolution depends on the degree of local invasion, histopathological nature of the tumour, localization of the formation, the time of intervention, and the age of the patient.

Collaboration between the surgeon and the oncologist is imperative in order to properly resolve the cases where necessary.

Soft tissue tumours are a typical example of surgical conditions that can be resolved in over 90% of cases in outpatient setting, under local anaesthesia and with low medical costs.

REFERENCES

1. Katemkamp K, Katenkampf D. (2009) Soft Tissue Tumours. New Perspective on Classification and Diagnosis; Dtsch Arztebl Int. 2009 Sep;106(39):632-636; https://www.ncbi.nlm.nih.gov/pmc/articles/PMC2770206 /Accessed on 22.02.2019.
2. NHS (2016) Soft Tissue Sarcomas. https://www.nhs.uk/conditions/soft-tissue-sarcoma/. Accessed on 12.03.2019.
3. Cleveland Clinic (2019) Malignant Soft Tissue Tumours. https://my.clevelandclinic.org/health/diseases/17203-malignant-soft-tissue-tumors, Accessed on 22.02.2019.
4. Canadian Cancer Society (2019) Non-cancerous soft tissue tumours. https://www.cancer.ca/en/cancer-information/cancer-type/soft-tissue-sarcoma/treatment/?region=bc, accessed at 2019 febr 10.
5. Cancer Research UK (2018) Soft Tissue Sarcoma; https://www.cancerresearchuk.org/about-cancer/soft-tissue-sarcoma/types, Accessed on 12.02.2019.
6. Singer S, Nielsen T, Antonescu CR. (2011) Molecular biology of soft tissue sarcoma. In: DeVita VT Jr, Lawrence TS, Rosenberg SA: Cancer: Principles and Practice of Oncology. 9th ed. Philadelphia, Pa: Lippincott Williams & Wilkins; 2011. p. 1522-32.
7. Singer S, Maki RG, O'Sullivan B. (2011) Soft tissue sarcoma. In: DeVita VT Jr, Lawrence TS, Rosenberg SA: Cancer: Principles and Practice of Oncology. 9th ed. Philadelphia, Pa: Lippincott Williams & Wilkins. 2011; p. 1533-77.
8. National Cancer Institute (2019) Adult Soft Tissue Sarcoma Treatment (PDQR) – Patient Version; https://www.cancer.gov/types/soft-tissue-sarcoma/hp/adult-soft-tissue-treatment-pdq, Accessed on 12.02.2019.
9. Midis G.P, Pollock R.E, Chen N.P et al. (1998) Locally recurrent soft tissue sarcoma of the extremities. Surgery. 1998;123(6):666-71 [PUBMED Abstract], Accessed on 12.02.2019.
10. Osaka S, Sugita H, Osaka E, Yoshida Y, Ryu J. Surgical management of malignant soft tissue tumours in patients aged 65 years or older; J Orthop Surg (Hong Kong). 2003 Jun;11(1):28-33. https://www.ncbi.nlm.nih.gov/pubmed/12810968, Accessed on 10.02.2019.