ACTA MEDICA TRANSILVANICA March;25(1):57-60
DOI: 10.2478/amtsb-2020-0015
Online ISSN 2285-7079

CUSTOMIZED CORONAL CONFORMATION SYSTEMS FOR LATERAL TEETH'S DIRECT RESTORATIONS

ELENA-CRISTINA MARCOV[1], NARCIS MARCOV[2], MIHAI BURLIBAȘA[3], CAMELIA IONESCU[4], MARIA GLENCORA COSTACHE[5], RUXANDRA STĂNESCU[6], IOANA VOINESCU[7], IRINA DONCIU[8], MĂDĂLINA MALIȚA[9], OLIVIA POPOVICIU[10], SORANA CORNELIA LIXANDRU DOHOTARIU[11], IULIANA BABIUC[12], DANA CRISTINA BODNAR[13], GABRIELA TĂNASE[14], ILEANA IONESCU[15]

[1,2,3,4,5,6,7,8,9,10,12,13,14,15] "Carol Davila" University of Medicine of Pharmacy Bucharest, [11]Ministry of Health

Keywords: *customized conformation systems, lateral teeth*

Abstract: *The restoration of a proximal wall depends on several factors, the conformation system playing one of the most important parts of the working protocol. The vertical, transversal and sagittal adaptation of the matrix band implies the use of one or two wedges and of a sectional matrix device (usually with a ring shape) with tines. The size, configuration and the material the tines are made of determine most of the quality of the adaption and stabilization of the matrix band. Even if these standardized tines have various designs and variable flexibility, a truly efficient tine should have a customized configuration which can be obtained after taking the impression of the initial proximal wall. The clinical situations that allow the customization of the standard tines imply proximal caries that have not interrupted the proximal wall or that have interrupted it less than one third of the transversal distance.*

INTRODUCTION

The standardized sectional coronal conformation systems for direct adherent restorations on lateral teeth have different designs and they are made of various materials.(1-4)

Most of the modern versions have matrix rings with lateral tines that adapt the matrix bands to the rest of the proximal hard tissues.(1,4-7)

The tines may be incorporated into the configuration of the rings or may be removable. The tines are usually made of flexible materials and they have various sizes and shapes. This diversity is intended to fit any proximal features of any proximal configuration, the tines adapting the matrix band to the curved surface of the remaining dental structure.(2,3,8-11)

When the proximal caries have not interrupted the proximal wall or they have interrupted it less than one third of the transversal distance, the customization of the tines appear to be the most efficient way to adapt the matrix band vertically, transversally and sagitally. Broadly, at the beginning of the working protocol, a matrix ring with simple and plain metal tines is applied on the tooth. An impression of the tines and of the neighbouring proximal area is then taken using a flowable and light-curable resin. The customized ring is then removed and kept aside till the restorative stage.(12-21)

AIM

The aim of this study was to assess the clinical efficiency of some customized matrix systems for lateral teeth.

MATERIALS AND METHODS

The materials used in this study were:

- the Palodent Plus EZ Coat (Dentsply) metal matrix bands;
- a Palodent (Dentsply) classic metal ring (round or oval);
- MyCustom Resin (Polydentia).

MyCustom Resin (Polydentia) is a microhybrid flowable and light-curable resin, similar to a liquid dam. It has tetramethylene dimethacrylate and it has a blue dyestuff for good visibility. The manufacturer claims that this product has a good thyxotropy and a final hardness which allows a proper customization of the metal tines of the matrix rings.

The study had forty patients (twenty-six men, fourteen women) with the age ranging from eighteen to forty-two years old, involving the treatments of sixty primary, proximal caries on lateral maxillary and mandibular teeth.

The treatments were carried out in a private practice dental office, in Bucharest, between January 2019 and December 2019.

Every clinical case was assessed along one, two or three treatment sessions, depending on the absence/presence and the degree of inflammation of the gingival papillae.

The working protocol followed the standard steps for the treatment of proximal caries, the specific features of every clinical case adapting certain stages.

The main steps of the protocol were:

1. Cleaning of the surfaces of the teeth.
2. Clinical examination and radiological assessment.
3. The clinical sheet.
4. The evaluation of the characteristics of the clinical case.
5. The brief presentation to the patient, in understandable terms, of the main steps of the treatment.
6. The patient's agreement to dental treatment protocol and to taking part into the study.
7. The determination of the tooth colour.
8. The recording of the occlusal contacts.
9. General and gingival additional moisture control.
10. Pre-wedging.
11. The application of a round or oval Palodent (Dentsply) ring

[2]Corresponding author: Narcis Marcov, Str. Plevnei, Nr. 19, Sector 1, București, România, E-mail: mburlibasa@gmail.com, Phone: +40723 472632
Article received on 14.01.2020 and accepted for publication on 24.02.2020

on the tooth, adapting the tines on the proximal area,

12. The application of several layers of MyCustom Resin (Polydentia) on the tines and on the proximal neighbouring areas of the teeth and the 20 second polymerization of every layer.
13. The removal of the customized ring.
14. The excavation of the necrotic dentine and of the demineralized and unsupported enamel and the finishing of the margins of the cavity.
15. The cleaning of the cavity with warm water.
16. Disinfection of the internal surfaces of the cavity.
17. Application of a Palodent Plus EZ Coat (Dentsply) metal matrix band, the customized Palodent ring and a new wedge.
18. Pulpal and dentinal layer protection: Ionoseal (Voco) was used as a pasive liner/base in medium / deep cavities and Dycal (Kerr Dental) was chosen as the active liner in the very deep areas of the preparations.
19. Application of the hybrid composite using an anatomical layering technique.
20. Removal of the conformation system.
21. Finishing and polishing.
22. Clinical and paraclinical assessment of the restoration.

The restorations were evaluated at the end of the procedure, after three months, six months and one year by three observers. They were private practice practitioners with different degrees of clinical training and skills in the field of restorative dentistry.

One randomly chosen observer also watched over the working protocol of every clinical case, the instructions of use of every product being thoroughly followed.

The clinical and radiological assessments were accomplished using the following criteria:

- the quality of the marginal sealing;
- the aspect of the proximal wall (including the contact area);
- the aspect of the occlusal portion.

During each session, the observers assigned scores to every restoration:

1. correct restoration;
2. incorrect restoration (in need for correction);
3. incorrect restoration (in need for reapplication).

The scores were the basis of the statistical charts which indicated the clinical efficiency of the customized conformation systems.

RESULTS

The clinical case of a first left upper premolar with a distal decay was considered significant to be presented in this section.

The patient R.R., 33 years old, requested the treatment of a supposed coronal lesion situated on the left maxillary premolars, the inter-dental space being frequently charged with food retention. The clinical examination and the radiological exam revealed a distal decay on the first premolar (figure. no. 1).

Figure no. 1. Distal decay on the first left upper premolar

The distal wall being intact, a customized conformation ring was accomplished (figure no. 2).

Figure no. 2. The impression of the proximal walls

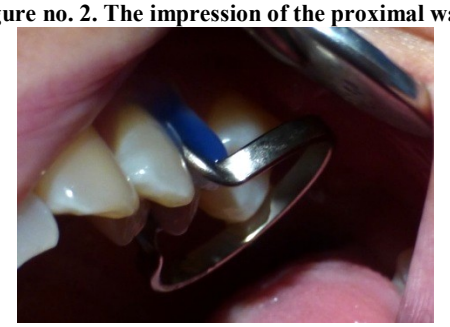

A round classic Palodent ring was adapted on the distal wall of the first left upper premolar. The custom resin was, then, applied on the tines and in the inter-dental buccal and oral spaces between the two premolars. The resin was applied in several layers, the final result implying tines covered with thick, rigid and extended structures of impression material.

After the polymerization, the ring was removed and kept for the future restorative stage (figure no. 3).

Figure no. 3. The customized conformation ring

After the preparation, cleaning and disinfection of the proximal cavity, a Palodent Plus EZ Coat (Dentsply) metal matrix band, the customized Palodent ring and a new wedge were applied (figure no. 4, figure no. 5).

Figure no. 4. The customized conformation system (occlusal view)

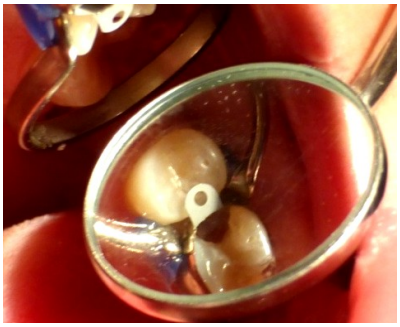

The metal band was burnished in the contact area using a manual instrument with a big-rounded head.

The hybrid composite was applied using an anatomical layering technique and OptraContact (Ivoclar Vivadent) was used in the contact area, in order to obtain a proper proximal contact.

After the polymerization of the final layer, the customized ring, metal band and wooden wedge were removed. New series of polymerization followed this stage. In the end, the surfaces of the restoration were finished (in static and dynamic occlusion) and polished (figure no. 6).

Figure no. 5. The customized conformation system (anterior view)

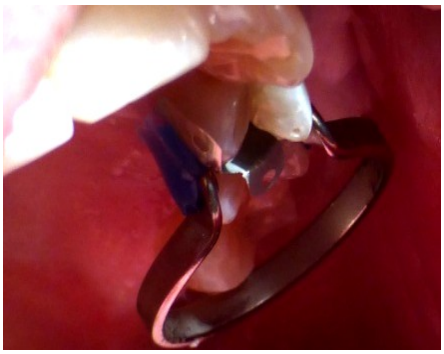

Figure no. 6. The distal restoration of the first left upper premolar

The quality of the configuration of the restored proximal wall was assessed using a bitewing radiography, the radiological image revealing a correct conformation of the distal wall of the first left upper premolar.

The first assessment, after the treatment, indicated two restorations that needed replacement because of incorrect gingival marginal sealing detected on the radiography. There were not restorations that needed corrections.

After three months, fifty-six restorations were correct, three of them needing corrections of one/two mm long segments of the oral/occlusal marginal sealing. Only one restoration was replaced because of a large defect in the marginal ridge area. The restoration was applied using a customized conformation system of the same type (figure no. 7).

Figure no. 7. The evaluation of the restorations after 3 months

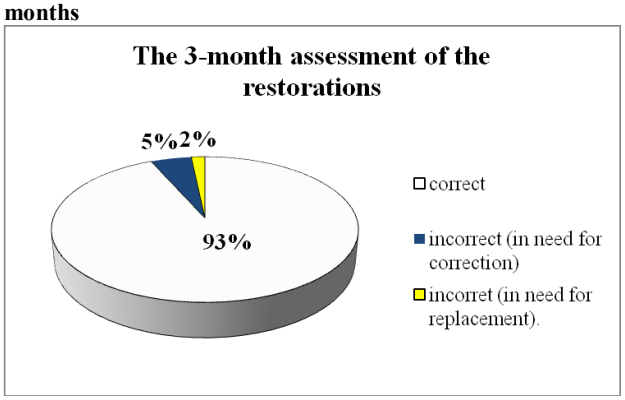

After six months, only two restorations needed improvement. One of them needed minor corrections of a one mm long segment of the marginal sealing in the oral area and the other one had a large loss of restorative material in the middle of the marginal ridge. These restorations were different from the incorrect ones detected during the three-month assessment (figure no. 8).

Figure no. 8. The evaluation of the restorations after 6 months

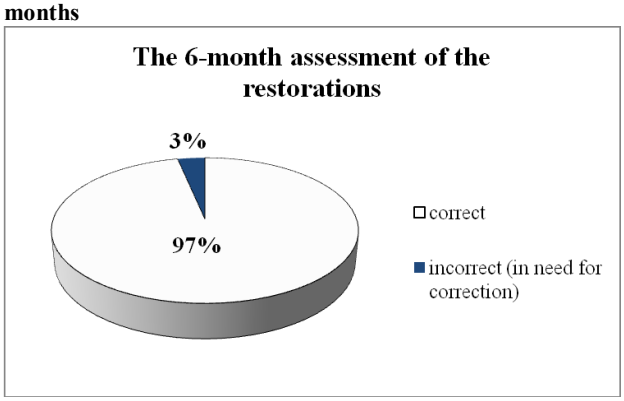

Three restorations had minor correctable defects in the area of the marginal ridge after twelve months. One of them had also been detected with defective areas after six months (figure no. 9).

Figure no. 9. The evaluation of the restorations after 12 months

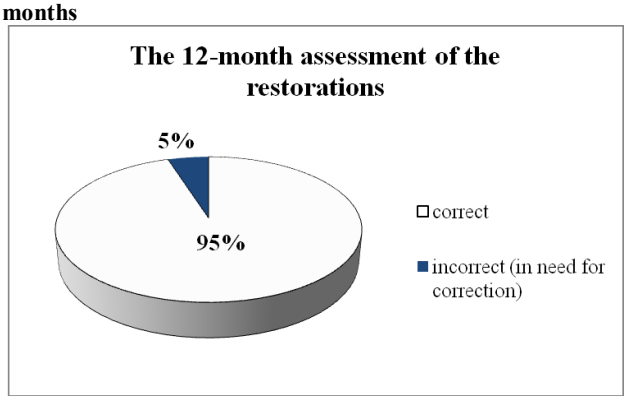

DISCUSSIONS

Most of the incorrect restorations had defects that had not had any connection with the use of the customized coronal system (figure no. 10).

It is understandable that the defective portions of the restorations may be due to several factors, the clinical inefficiency of the coronal system being only one of them. The only situations with incorrect gingival marginal sealing were detected only during the first evaluation, after the treatment. They were replaced using the same customized coronal conformation system and they had not presented any defects after three months, six months and one year from application.

The restorations that had oral or buccal defects after the second evaluation have also been considered correct after the next two assessments.

One of the restorations that needed correction during the 6-month and the 12-month assessments belonged to a young patient that agreed to the fact that sticky and hard candies belong to his every day's diet. The restoration of the mesial wall of the first right lower molar had, in both cases, loss of composite mass located in the middle area of the marginal ridge extended towards the centre of the occlusal surface.

Considering these results, the associated use of the Palodent Plus EZ Coat (Dentsply) metal matrix bands, the Palodent (Dentsply) classic round/oval metal ring and MyCustom Resin (Polydentia) drove to good results proving themselves to generate good clinical results.

Figure no. 10. The defective sites of the restorations: 1 - incorrect gingival sealing; 2 - incorrect oral sealing; 3 - incorrect buccal sealing; 4 - loss of the restorative material in the area of marginal ridge-occlusal surface

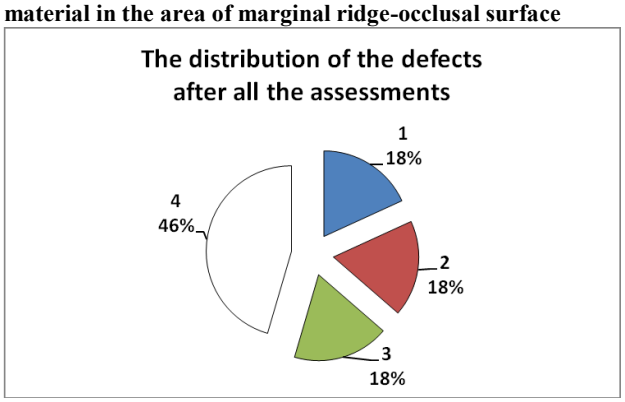

CONCLUSIONS

The customized coronal conformation system has proved to be a reliable tool during the working protocol of the direct adherent treatment of the proximal caries on the lateral teeth.

One of the most important aspects is the stiffness of the polymerized material, the metal band needing rigid enough three-dimensional pieces specifically designed to adapt it on the remaining areas of proximal hard tissues.

These conformation modified devices have an easy protocol of production, the impression material used in this study being specifically conceived for this purpose.

The practitioner considered insignificant the extra time involved in its production in comparison with the provided benefits.

The good clinical results registered in this study and the easy method of obtaining, recommend the customized coronal system as a useful tool.

Nevertheless, the features of the clinical case represent the main factors that decide the use of a standard or of a customized conformation system in the direct adherent treatments of lateral teeth's proximal caries.

Acknowledgement: *In this article, all the authors have equal contributions.*

REFERENCES

1. Marcov EC, Marcov N, Burlibașa M, et al. Comparison of several proximal conformation systems' clinical efficiency in restorative dentistry. Acta Medica Transilvanica. 2016;21(3):84-87.
2. Marcov EC. Manual de odontoterapie restauratoare, vol. II. Instrumentarul utilizat în odontoterapia restauratoare. Editura Ars Docendi, București; 2012.
3. Heymann H, Swift EJ, Ritter AV, Sturdevant CM. Sturdevant's Art and Science of Operative Dentistry; 6th ed. St. Louis, MO: Elsevier/Mosby; 2013.
4. Kampouropoulos D, Paximada C, Loukidis M, Kakaboura A. The influence of matrix type on proximal contact in class II resin composite restorations. Operative Dentistry. July 2010;35(4):454-62.
5. Godinot J. Le point de contact interdentaire: revue des moyens à disposition du praticien pour sa reconstitution en odontologie restauratrice. Thesis. May; 2012.
6. El-Badrawy W.A., Leung B.W., El-Mowafy O., Rubo J.H., Rubo M.H. Evaluation of proximal contacts of posterior composite restorations with 4 placement techniques. J Can Dent Assoc. 2003;69:162-7.
7. Liebenberg WH. The proximal precinct in direct posterior composite restorations: Interproximal integrity. Pract Proced Aesthet Dent. 2002;14:587-94.
8. Huysmans MC. Restoration techniques and marginal overhang in Class II composite resin restorations. J Dent. 2009;37:712-7.
9. Summitt JB, Robbins JW, Schwartz RS, dos Santos J. Fundamentals of operative dentistry: A contemporary approach. 3rd ed. University of Michigan: Quintessence Pub; 2006.
10. Marcov EC. Protocol de restaurare aderentă directă a leziunilor carioase simple proximale din zona laterală. In: Pădure L., Marcov E.C, Burcea C.C, Lupușoru M., editors. Actualități în asistența medicală, Editura Ars Docendi; București. 2013;4:19-54.
11. Marcov EC, Marcov N. Electron microscopy validation of ICDAS codes 5 and 6 for proximal caries. Romanian Journal of Oral Rehabilitation. 2013;5(3):92-96.
12. da Silva-Junior M.E Fagundes Jordao-Basso T.P.L.K.C., Ferrarezi de Andrade M. Reestablishment of interproximal contact with custom ring technique. Scientific Journal of Dentistry. 2015;2:46-49.
13. Burlibașa M, Muntianu L, Tănase G, Bucur MB, Comes CA, Ionescu CA. Study on microbial contamination of biomaterials in medical practice. Metalurgia International. 2010;Vol. XV, Spec. Issue No. 2, p. 163-166.
14. Tănase G, Burlibașa M, Muntianu L, Simion I, Bucur MB, Ionescu CA. Testing the antibacterial potential of biomaterials in medical practice. Metalurgia International. 2010;Vol. XV, Spec. Issue No. 2, p. 160-162.
15. Burlibașa M, Tănase G, Muntianu L, Murgu AI, Teodorescu E, Malița C. Quality of life, a multidisciplinary concept with economic and social impacts in medical practice. Metalurgia International. 2010; Vol. XV, Spec. Issue No. 4, p. 88-90.
16. Ispas DC, Eftene OA, Burlibașa M, Bucur MB, Tănase G, Cristache CM. Implications of titanium in orthodontics and dental facial orthopedics. Metalurgia International. 2011; Vol. XVI, No. 10, p. 72-74.
17. Burlibașa M, Cernușcă-Mițariu M, Burcea CC, Mițariu M, Ferechide D. Halogen compounds – theoretical, physiological and practical aspects regarding the decontamination, disinfection and sterilisation of instruments and biomaterials in dental medicine practice. Metalurgia International. 2012; Vol. XVIII, Spec. Issue No. 3, p. 54-57.
18. Burlibașa M, Cernușcă-Mițariu M, Cernușcă-Mițariu S, Mițariu M, Malița M. Theoretical and practical aspects related to biomaterials decontamination in dental medicine (with reference to dental prosthetics). Metalurgia International. 2013; Vol. XVIII, No. 4, p. 261-267.
19. Burlibasa L, Domnariu C. Epigenetic landscape of human diseases. Acta Medica Transilvanica. 2018;23(2):33-37.
20. Bodnar DC, Burlibașa L, Vârlan C, Marcov N, Georgescu SR, Marcov CE. Mercury, biocompatibility and its impact on environment. Metalurgia International. 2009;14:95-100.
21. Cristache CM, Burlibașa M, Cristache G, Drafta S, Popovici IA, Iliescu AA, Zisi S, Burlibașa L. Zirconia and its biomedical applications. Metalurgia International. 2011; Vol. XVI, No. 7, p. 18-23.