ACTA MEDICA TRANSILVANICA December 25(4):44-46
DOI: 10.2478/amtsb-2020-0070
Online ISSN 2285-7079

GASTRO-INTESTINAL-STROMAL TUMORS (GIST) – AN UNEXPECTED FINDING IN TWO CASES

DAN BRATU[1], VICTORIA GÎRA[2], FLORIN FLUTURE[3]

[1]Lucian Blaga University of Sibiu, [1,2,3]Clinical Emergency County Hospital of Sibiu

Keywords: *gastro-stromal-intestinal tumour, relapse, surgery*

Abstract: *Being considered a rare form of malignant neoplasm, stromal tumours are part of sarcomas group, they account for ~5% of all sarcomas (1), which develop from the supporting tissues of the body and have as a starting point special cells located in the wall of the gastrointestinal tract, called interstitial cells - described by Cajal. Although this type of tumour formations poses the problem of diagnosis, when it is made early and surgical and oncological treatment is prompt, the prognosis improves considerably.*

INTRODUCTION

This pathology is found in about 5000-10000 cases per year (USA), which represents 0.1-3% of gastrointestinal neoplasms, respectively over 80% of mesenchymal gastrointestinal cancers. It has a higher incidence in males and interests decades of age between 4 and 7.(1)

Population studies in Iceland, the Netherlands, Spain and Sweden report annual incidence rates ranging from 6.5 to 14.5 cases per million.

Population studies in Iceland, the Netherlands, Spain and Sweden report annual incidence rates ranging from 6.5 to 14.5 cases per million.

Stout and his colleagues classify in 1940 the stromal-type neoplasms of the gastrointestinal tract as being derived from smooth muscles. In 1984 it was discovered that this type of neoplasia is based on elements of autonomic neural tissue. In the mid-1990s, immunohistochemical studies showed that GIST-type tumours were related to Cajal cells.(1,2)

CASE REPORT

We present the case of a 67-year-old female patient, known with multiple history of major surgery for intergastro-splenic colic tumour.

In each of the two previous operations, the histological result was old hematoma. Within two years and one year, respectively, the formation relapsed.

She was hospitalized in our clinic, for abdominal pain in epigastrium and left hypochondrium, with posterior irradiation, nausea, vomiting with fecal content, absence of intestinal transit for feces. At the clinical examination, the patient complains of pain in the left hypochondrium, a tumour mass being also palpated at this level.

The CT examination of the abdomen reveals inhomogeneous mass, with blood densities included, with dimensions of about 5.5 / 7 cm, in intimate contact with the great gastric curvature and with the splenic angle of the colon, as well as inhomogeneous dense accumulation with densities similar to that described above, in the left flank in contact with the intestinal loops, with a diameter of about 5 cm.

Figures no. 1, 2 CT scan aspect of the tumours

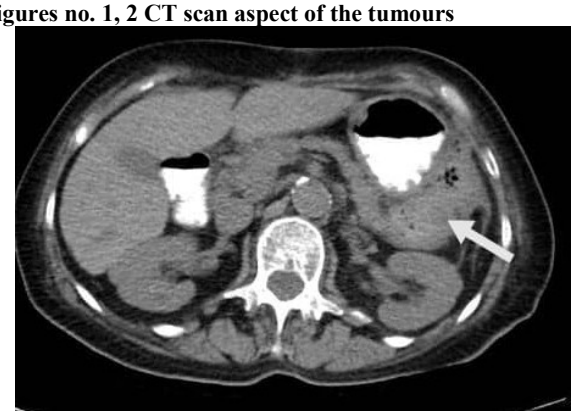

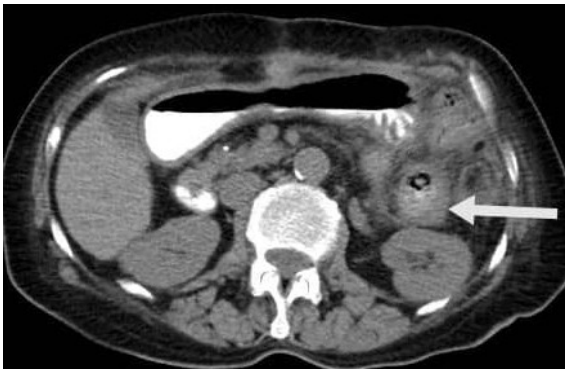

She underwent surgery under general anesthesia with oro-tracheal intubation, an iterative exploratory laparotomy was performed. Upon exploration of the peritoneal cavity, an approximately 8/6 cm tumour was detected, plunging into the meso of the descending colon, the tumour that infiltrates the transverse mesocolon, comes into intimate contact with the duodeno-jejunal angle and the first jejunal loop, being near the inferior mesenteric vein. The tumour invades the serosa of the descending colon, significantly reducing its lumen and was evolving posteriorly to the retroperitoneum.

[2]Corresponding author: Victoria Gîra, Str. Daliei, Nr. 2, Bl. 2, Ap.17, Sibiu, România, E-mail:victoria_gira@yahoo.com, Phone: +40755 525917
Article received on 03.10.2020 and accepted for publication on 02.12.2020

Also, on the great curvature of the stomach and in the tail of the pancreas, a tumour of about 6/5 cm is detected in intimate contact with the stomach, the tail of the pancreas, the splenic pedicle and the splenic angle of the colon. The tumour walls invade the colon and the tail of the pancreas, with white-purple inhomogeneous appearance content, with a gelatinous consistency that raises the suspicion of cystadenocarcinoma or GIST.

Taking into account the invasion of the tumours in the descending colon, segmented colectomy (transverse and descending) was performed with right upper quadrant stoma, lavage and multiple peritoneal drainage.

Postoperatively, the patient's evolution was favourable. It is discharged on the 14th day postoperatively in good general condition.

Histopathological examination reveals microscopic and immunohistochemical appearance of gastrointestinal stromal tumour (GIST) - malignant with high mitotic index, necrosis and multiple abdominal localization - pT3N0M1.

Figures no. 3,4. Resection pieces with tumours included - intraoperative appearance

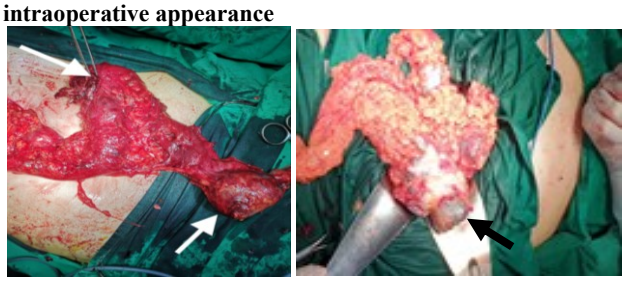

Another similar case is of a 69-year-old patient, who also presents in our Clinic with a voluminous straight ovarian tumor, for which laparoscopic intervention is initially performed and multiple disseminated formations are detected at the level of the transverse mesocolon, with cystic-parenchimatos appearance.. It was later decided to convert the surgery, opting for the classic approach by exploratory laparotomy that highlights cystic-parenchymal tumour in the transverse mesocolon with a diameter of about 8/6 cm, which invades posteriorly. Also, at the level of the tail of the pancreas, closely adhering to it, another similar tumour was detected and was removed. Subsequently, a right annexectomy was performed for the ovarian tumour. The histopathological result was similar to that of the previous case.

DISCUSSIONS

More than half of stromal tumours develop in the stomach and a large part in the small intestine. A limited number of GIST's develop outside the digestive tract, at the level of the omentum or peritoneum. Mesenchymal tumours of gastric interest are found in about 50-70%, in the small intestine - in 20-30% of cases and in the colon - less than 10% of cases.(2,3)

Confirmation of the definite diagnosis is made by anatomo-pathological and immunohistochemical examination.
The anatomo-pathological examination of the colorectal tumour section, with hematoxylin-eosin, presents morphological variants depending on the appearance of the tumour sky:

- spindle-cell type - 70%,
- round, polygonal cell type (epithelioid) - 20%,
- mixed type - 10%.

Immunohistochemical examination involves evaluating the expression of a tumour-specific marker:

C-KIT, CD34, smooth muscle specific actin, S-100 protein, KI67 desmin.

C-KIT (CD117), 145-KD glycoprotein is a positive defining diagnostic marker in 95% of GISTs.(2,4,5,6)

KIT and PDGFRA gene mutations are most often spontaneous in only 5% of cases being familial.

Mutations in the KIT and PDGFRA genes are transmitted autosomal dominantly, requiring a single copy of the affected gene to manifest the disease. Both genes can have both de novo and germline mutations and are responsible for the occurrence of both familial and sporadic cases. Another genetic cause may be SDH (succinate dehydrogenase) and BRAF, a gene occasionally associated with malignant melanoma or colorectal cancer.(7,8)

The clinical diagnosis in establishing the presence of this pathology, involves performing a comprehensive objective examination.

The symptoms and signs of this pathological entity are clinically evident in 72% of cases depending on the location of the tumour, the rate of growth and the diameter of the tumour.

Stromal gastrointestinal tumours can be silent until they reach large sizes and can manifest nonspecifically through abdominal pain, anemia or fatigue. They may present as a palpable tumour (50-70%) or may initially manifest as a complication (upper gastrointestinal bleeding, hemoperitoneum - 25%), tumour perforation, intestinal occlusion or obstructive jaundice).(7,9,10,11)

From imaging point of view, the evaluation of gastrointestinal mesenchymal tumor formations require a series of paraclinical investigations such as: eso-gastric barium transit, echo-endoscopy, abdominal and pelvic computed tomography, nuclear magnetic resonance or PET-CT.(12)
But the definite diagnosis remains the anatomo-pathological one.

Surgery is the treatment of choice for resectable gastrointestinal stromal tumours and follows some basic principles:

- complete surgical resection 'en bloc'
- avoiding tumour rupture
- avoidance of lymphadenectomy (tumours tend to affect the entire parietal structure with the invasion of neighbouring organs without lymphatic metastasis)
- wide omentectomy due to frequent peritoneal disseminations.(13,14,15)

On the other hand, medical treatment focuses on tyrosine kinase inhibitors.

Imatinib was the first approved tyrosine kinase inhibitor in antineoplastic therapy to revolutionize this field.

There has been a significant improvement in survival through a more specific action and with a very limited toxicity in the localized disease, Imatinib is administered after surgery, in order to prevent or delay recurrence.

In the conditions of an extended disease, the duration of administration is indefinite and depends on maintaining control over the disease but also on the tolerability of the treatment. In certain situations, especially where there are mutations in exon 9 of the KIT gene, it is decided to double the dose of Imatinib.Stromal tumors that show these mutations are considered with increased aggression and as a result have a negative prognosis.(16,17)

The main side effects of Imatinib are water retention, rush, nausea, fatigue and less often muscle pain, bleeding or liver cytolysis.

Sunitinib - another tyrosine kinase inhibitor, which also has an antigiogenic effect. Regorafenib is the latest tyrosine kinase inhibitor entered into therapeutic protocols after the ineffectiveness of the first two preparations.(8,9,17,18)

Radiation therapy is not routinely used in the treatment of GISTs. In some situations, palliative radiotherapy is used.

The five-year survival rate for all stromal tumours is

around 76% with limits above 90% for localized tumors and over 45% for metastatic tumours.(1)

Tumours with a rare frequency in surgical practice in recent decades have become more and more common in surgical practice. Although the diagnosis is histological, the suspicion of a GIST-type tumor may be raised by the surgeon, during the operation, based on the macroscopic examination.

It is therefore useful for surgeons to be advised, and so the surgical attitude should be accordingly.

CONCLUSIONS

In the situation of an early diagnosis, of an optimal surgical attitude and of an accurate histopathological diagnosis and under specific oncological therapy, this type of tumour has a good survival rate.

When one of the previously mentioned stages is missing or insufficient, the patient's evolution can be dramatic.

REFERENCES

1. Søreide K, Sandvik OM, Søreide JA, Giljaca V, Jureckova A, Bulusu VR. Global epidemiology of gastrointestinal stromal tumours (GIST): A systematic review of population-based cohort studies. Cancer Epidemiol. 2016 Feb;40:39-46. doi: 10.1016/j.canep.2015.10.031. Epub 2015 Nov 24. PMID: 26618334.
2. Zhao X, Yue C. Gastrointestinal stromal tumor. J Gastrointest Oncol. 2012;3(3):189-208. doi:10.3978/j.issn.2078-6891.2012.031.
3. Bădulescu A, Bădulescu F, Constantinoiu S, Popescu C, Schenker M. Tumorile gastrointestinale stromale (GIST)--un nou concept diagnostic şi terapeutic [Gastrointestinal stromal tumors (GIST)-a new diagnostic and therapeutic paradigm]. Chirurgia (Bucur). 2006 Jan-Feb;101(1):87-99. Romanian. PMID: 16623384.
4. Miettinen M, Lasota J. Gastrointestinal stromal tumors. Gastroenterol Clin North Am. 2013 Jun;42(2):399-415. doi: 10.1016/j.gtc.2013.01.001. Epub 2013 Mar 13. PMID: 23639648; PMCID: PMC3644178.
5. El-Menyar A, Mekkodathil A, Al-Thani H. Diagnosis and management of gastrointestinal stromal tumors: An up-to-date literature review. J Cancer Res Ther. 2017 Oct-Dec;13(6):889-900. doi: 10.4103/0973-1482.177499. PMID: 29237949.
6. Popescu I, Andrei S. Gastrointestinal stromal tumors. Chirurgia (Bucur). 2008;103(2):155-70.
7. Miettinen M, Lasota J. Gastrointestinal stromal tumors--definition, clinical, histological, immunohistochemical, and molecular genetic features and differential diagnosis. Virchows Arch. 2001 Jan;438(1):1-12. doi: 10.1007/s004280000338. PMID: 11213830 and differential diagnosis. Virchows Arch., 2001, 438:1.
8. DeMatteo RP. The GIST of targeted cancer therapy: a tumor (gastrointestinal stromal tumor), a mutated gene (c-kit), and a molecular inhibitor (STI571). Ann Surg Oncol. 2002 Nov;9(9):831-9. doi: 10.1007/BF02557518. PMID: 12417503.
9. Roberts PJ, Eisenberg B. Clinical presentation of gastrointestinal stromal tumors and treatment of operable disease. Eur J Cancer. 2002 Sep;38 Suppl 5:S37-8. doi: 10.1016/s0959-8049(02)80601-3. PMID: 12528771.
10. Negreanu LM, Assor P, Mateescu B, Cirstoiu C. Interstitial cells of Cajal in the gut-a gastroenterologist's point of view. World J Gastroenterol. 2008;14(41):6285-8.
11. Chandrajit P. Raut, Stanley W. Ashley. How I Do It: Surgical Management of Gastrointestinal Stromal Tumors. J Gastr Surg. 2008;12(9):1592-1599.
12. Fletcher CD, Berman JJ, Corless C, Gorstein F, Lasota J, Longley BJ, Miettinen M, O'Leary TJ, Remotti H, Rubin BP, Shmookler B, Sobin LH, Weiss SW. Diagnosis of gastrointestinal stromal tumors: A consensus approach. Human Pathol. 2002;33(5):459-65
13. Pasalega M, Mesinã C, Vîlcea D, Cheie M, Vasile I. Tumora stromalã gastrointestinalã (GIST) cu localizare jejunalã, sursã rarã de hemoragie digestive, Chirurgia, 100 (4):385-390.
14. Tanasescu C, Faur M, Gherman C. Difficult diagnosis in a case of transverse colon neoplasm invading the greater gastric curvature Acta Medica Transilvanica. 2020;25(2):55-57.
15. Otani Y, Furukawa T, Yoshida M, Saikawa Y, Wada N, Ueda M, Kubota T, Mukai M, Kameyama K, Sugino Y, Kumai K, Kitajima M. Operative indications for relatively small (2-5 cm) gastrointestinal stromal tumor of the stomach based on analysis of 60 operated cases. Surgery. 2006;139(4):484-92.
16. D'Amato G, Steinert DM, McAuliffe JC, Trent JC. Update on the biology and therapy of gastrointestinal stromal tumors. Cancer Control. 2005;12(1):44-56.
17. Pidhorecky I, Cheney RT, Kraybill WG, Gibbs JF. Gastrointestinal stromal tumors: current diagnosis, biologic behavior, and management. Ann Surg Oncol. 2000 Oct;7(9):705-12. doi: 10.1007/s10434-000-0705-6. PMID: 11034250.
18. Akahoshi K, Oya M, Koga T, Shiratsuchi Y. Current clinical management of gastrointestinal stromal tumor. World J Gastroenterol. 2018 Jul 14;24(26):2806-2817. doi: 10.3748/wjg.v24.i26.2806. PMID: 30018476; PMCID: PMC6048423.