ACTA MEDICA TRANSILVANICA September27(3):47-49
Online ISSN 2285-7079

RECTAL SYPHILIS – A DIAGNOSTIC CHALLENGE IN THE ENDOSCOPY DEPARTMENT

LUCIAN SORIN ANDREI [1], ALEXANDRU MICU[2], ADRIANA CORINA ANDREI[3], RADU SORIN POPIȘTEANU[4]

[1,3]Mediproct Clinic, Bucharest, [1,2,3,4]Fundeni National Institute, Bucharest

Keywords: *syphilis, rectal, ulceration, endoscopic*

Abstract: *Rectal syphilis is a rare disease and is often overlooked in the differential diagnosis of proctitis or rectal ulcer. The diagnosis of these lesions is difficult, as their clinical presentation points the physician to more common conditions such as cancer or inflammatory bowel disease and can therefore be treated incorrectly.(1) Endoscopic examination is a key investigation in the evaluation of these lesions that may direct the diagnosis to an infectious cause, especially in men who have sex with the male group (MSM).(2,3) We present the case of a patient who came to the proctology clinic for rectal bleeding, anal mucus discharge and anal pain. The colonoscopic appearance is proctitis and ulceration with flattened stamped edges, directing the diagnosis to an infectious cause of this rectal lesion, raising the suspicion of rectal syphilis. The diagnosis was confirmed by the VDRL test. Histopathological examination ruled out rectal cancer.*

INTRODUCTION

Rectal syphilis is a rare condition in medical practice and its diagnosis can be a real challenge for a proctologist. Because both the clinical manifestations and the endoscopic appearance are seemingly nonspecific, the physician may erroneously target more common conditions such as inflammatory bowel disease, rectal cancer, or solitary ulcer. In this way, the initial diagnosis can be postponed or specified in the late stages of the disease.(3)

CASE REPORT

We present the case of a 28-year-old patient who presented to the proctology office for rectorrhagia, ano-perianal pain after defecation and anal mucus discharge. From the patient's personal pathological history, we note that he underwent surgery 4 months before for haemorrhoids - the Milligan Morgan procedure.

Examination of the ano-perianal region concluded the presence of external haemorrhoids. A digital rectal examination was performed and a hardened lesion was felt that stretched for about 4 cm starting from the anal edge. Within the usual protocol in the proctology office, an anoscopic examination was performed which revealed the presence of ulceration in the rectal mucosa, spontaneous bleeding and grade III internal haemorrhoids. At the time of initial presentation, the usual test was collected, including screening tests for viral hepatitis, VDRL and HIV. Due to the non-specific anoscopic aspect, it was decided to perform a lower digestive endoscopy for a more detailed evaluation of the rectal lesions as well as of the entire colon in order to exclude other possible concomitant lesions.

Colonoscopic examination described the hyperemic rectal mucosa with an ulcerated area with flattened stamped edges 3-4 cm in diameter starting from the anal edge; the rest of the colon looked normal. The endoscopic diagnosis was a rectal ulcer, acute rectitis and grade III haemorrhoids. Multiple biopsies were performed during the examination of the lesion.

Figure no. 1. Rectal syphilis – rectal ulcer with flattened stamped edges (colonoscopic aspect)

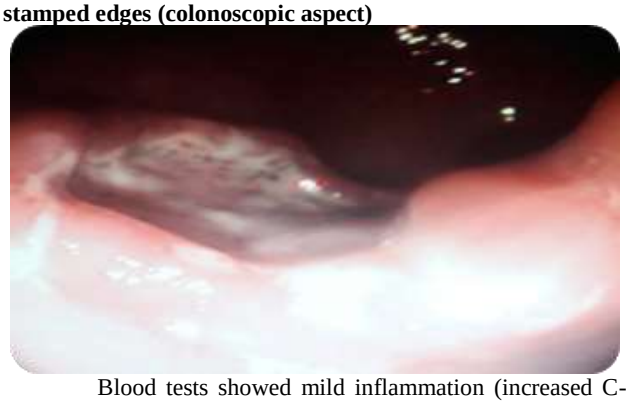

Blood tests showed mild inflammation (increased C-reactive protein and fibrinogen) and a positive VDRL test. The young age, lack of family history for digestive neoplasms, biohumoral data and the endoscopic appearance led to the diagnosis of an infectious inflammatory lesion.

Histopathological examination of the bioptic fragments showed moderate polymorphic inflammation in the chorion, with numerous plasma cells, cryptitis and cryptic microabscesses and marginal areas of erosive inflammation. The histopathological appearance of chronic active, erosive-ulcerative proctitis also raised the suspicion of infectious proctitis, possibly syphilitic, and ruled out the malignancy of the lesion.

In this context, given the diagnosis of primary rectal syphilis, a dermato-venerological consultation was required. Following this consultation, the patient confirmed the initially denied unprotected homosexual practices.

The patient underwent specialized dermato-venerological treatment with Penicillin G benzathine intramuscularly 3.5 million units/ week, for 3 weeks, with a favourable evolution without giving up homosexual practices.

[1]Corresponding author: Lucian Sorin Andrei, Șos. Fundeni, Nr. 258, Sect 2, București, România, E-mail: sandrei741@gmail.com @yahoo.com, Phone: +40722 232011
Article received on 27.07.2022 and accepted for publication on 02.09.2022

Figure no. 2. Crypt abscesses and cryptitis HE400x

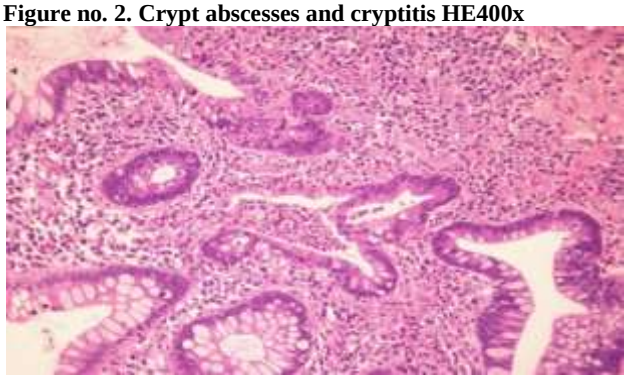

Figure no. 3. Rectal mucosa - active chronic inflammation with architectural distortion of glands, HE 200

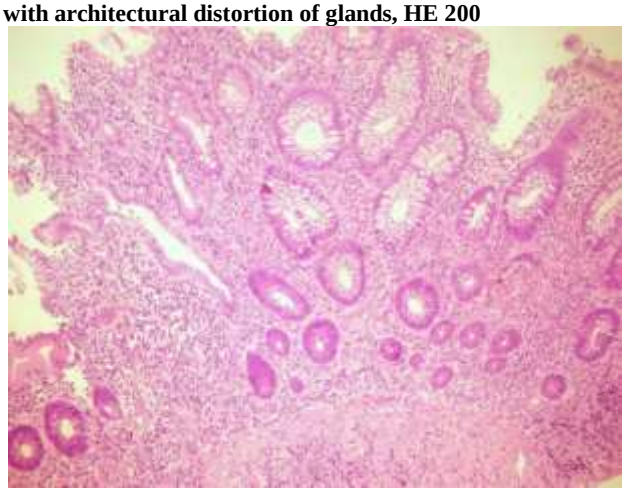

DISCUSSIONS

Syphilis is a sexually transmitted disease caused by a spirochete called Treponema Pallidum; the transmission can occur both vertically and through vaginal, oral and anal sex.(4) Unprotected anal sex is quite common in the MSM group, so in the case of such a patient, sexually transmitted diseases should be taken into account.(5)

The primary chancre is located mainly at the genital or perioral level. The rectal and vaginal localization is difficult to reveal, therefore these patients ensure more frequently further spread of the disease.

The incubation period until the appearance of primary chancre is about 3 weeks (ranging from 10 to 90 days) with its spontaneous healing and replacement with a hardened scarred area in 3-6 weeks; therefore the timing and experience are extremely important in the orientation towards this diagnosis when encountering this kind of lesions.(6) In this case, the macroscopic appearance of an ulcerated mass with flattened stamped edges and rectitis raised the suspicion of rectal syphilis. This aspect can occur in other pathologies such as inflammatory bowel disease and especially rectal cancer.(7,8) This is the reason why although in a suggestive clinical context the lesion may direct the proctologist to an infectious cause, it is important to take biopsies and perform histopathological examination. In the case of rectal syphilis, histopathological examination mostly describes chronic inflammatory infiltrates; acute inflammation, ulceration and erosion are quite commonly described in association with chronic inflammation. Lesions are nonspecific and include perivascular infiltrate with lymphocytes and plasma cells and endothelial proliferation.(2,9)

The diagnosis of syphilis is based on dark field microscopy or PCR test. Darkfield microscopy of exudates from the rectal ulcer may be inaccurate due to contamination with commensal spirochetes found in the normal flora of the rectum and PCR testing is not very accessible; therefore the diagnosis of rectal syphilis can be established by serological testing (VDRL or TPHA), which together with endoscopy and biopsy can confirm the diagnosis.(10) In this case, the diagnosis was confirmed by a VDRL test, which is also necessary for follow-up. We mention that the examination in dark field was not available in the proctology and digestive endoscopy office, and at the time the patient went to the dermato-venereologist it was no longer considered necessary.

The treatment of rectal syphilis consists of benzathine penicillin G, with considerable variation in some case reports in terms of dose and frequency of administration, ranging from a single dose to three doses (one per week for three weeks).(11) In most cases, after treatment, the ulcer and proctitis are completely cured with the concomitant disappearance of the symptoms. In our case, the colonoscopy after treatment showed a normal aspect of the rectum.

Both secondary and tertiary syphilis may occur due to systemic dissemination of spirochetes resulting in a wide range of visceral and cutaneous manifestations.(12) We mention that our patient did not have any suggestive lesions for secondary or tertiary disease.

Screening for viral hepatitis, HIV and syphilis should be considered in all patients with suspected proctocolonic inflammatory lesions or solitary ulcer.(13) Protected sexual intercourse, including in homosexual groups, is recommended in order to reduce the spread of sexually transmitted diseases including rectal syphilis.

CONCLUSIONS

Rectal syphilis is a condition that should be taken into consideration in the case of an endoscopy that detects proctitis or rectal ulcer in a young homosexual patient given the increased risk of sexually transmitted diseases.

Endoscopic orientation to syphilis in case of a flattened stamped edge rectal ulcer can shorten the path to a correct and prompt diagnosis, given that this disease has a systemic evolution and a difficult treatment in the advanced stages.

REFERENCES

1. Struyve M, Meersseman W, Van Moerkercke W. Primary syphilitic proctitis: case report and literature review. Acta Gastroenterol Belg. 2018 Jul-Sep;81(3):430-432.
2. Ferzacca E, Barbieri A, Barakat L. Lower Gastrointestinal Syphilis: Case Series and Literature Review. Open Forum Infect Dis. 2021;8(6).
3. Cha J, Choi S, Lee J. Rectal Syphilis Mimicking Rectal Cancer. Yonsei Med J. 2010;51(2):276.
4. Shu Z, Zhao J, Deng X, et al. Primary chancre in the rectum: A report of rare case of syphilis. Radiology of Infectious Diseases. 2014;1(1):29-31.
5. Foschi C, Gaspari V, Sgubbi P et al. Sexually transmitted rectal infections in a cohort of 'men having sex with men'. J Med Microbiol. 2018;67(8):1050-1057.
6. Grilo Bensusan I, Gómez-Regife L. Primary syphilitic chancre in the rectum. Endoscopy. 2014;46(S01):E533-E533.
7. Tian M, Chang C, Wu P, Chen M. Diagnosis of syphilitic proctitis mimicking ulcerative colitis - A case report. Advances in Digestive Medicine. 2019;7(2):102-105.
8. Chiang Y, Hsieh K, Kung C. Syphilitic proctitis imitating rectal malignancy. Eur J Gastroenterol Hepatol. 2020;32(2):285-286.
9. Trovato Emanuele, Tognetti Linda, Campoli Marco.

Syphilis Diagnosis and Treatment: State of The Art. European Medical Journal. 2021:20-00221.
10. Díaz-Jaime F, Satorres Paniagua C, Bustamante Balén M. Primary chancre in the rectum: an underdiagnosed cause of rectal ulcer. Revista Española de Enfermedades Digestivas. 2017;109.
11. Costales-Cantrell JK, Dong EY. Wu. Syphilitic Proctitis Presenting as a Rectal Mass: a Case Report and Review of Literature. Journal of General Internal Medicine. 2021;36(4):1098-1101.
12. Matthew J Smith, Meydene Ong, Abrar Maqbool, Tertiary syphilis mimicking metastatic rectal cancer, Journal of Surgical Case Reports. 2022(3):rjac093.
13. Pisani Ceretti A, Virdis M, Maroni N et al. The Great Pretender: Rectal Syphilis Mimic a Cancer. Case Rep Surg. 2015;2015:1-4.