ACTA MEDICA TRANSILVANICA September27(3):19-22
Online ISSN 2285-7079

THE ROLE OF VENOUS SINUS STENTING IN IDIOPATHIC INTRACRANIAL HYPERTENSION ILLUSTRATED BY A CLINICAL CASE – CASE REPORT

LUISA MARIA URECHE[1] , FLORIN GROSU[2]

[1,2] "Lucian Blaga University" of Sibiu, [2]County Clinical Emergency Hospital of Sibiu

Keywords: *idiopathic intracranial hypertension, venous sinus stenting, headache, papilloedema, obesity*

Abstract: *Idiopathic Intracranial Hypertension (IIH) also known as pseudotumor cerebri, is a syndrome of increased intracranial pressure of unknown cause with the possible risk of permanent blindness. Headache is also a characteristic symptom who can reduce the quality of life. The condition mainly affects obese young women of childbearing age. Pathogenesis of this condition has not been fully established and clinical presentation is highly variable. Common symptoms include headaches, visual loss and pulsatile tinnitus. Treatment has two major goals: the alleviation of headaches and the preservation of vision. Weight loss and acetazolamide are essential in the treatment of the disorder. Surgical treatment or lumbar punctures are often necessary when symptoms are fast getting worse leading to a loss of visual function. Endovascular management of dural sinus stenosis is clinically effective in patients with IIH who are unresponsive to medical and surgical therapy.*

INTRODUCTION

Idiopathic intracranial hypertension (IIH) is a rare syndrome of elevated intracranial pressure (ICP), with normal cerebrospinal fluid composition and without established pathogenesis.(1)

The disorder is strongly associated with obesity, and patients are mostly female and typically of reproductive age.(2) Weight gain is the only known risk factor for this syndrome. More than 90% of patients with IIH have a high body mass index (BMI), being either overweight (BMI >25) or obese (BMI >30).(3) Its prevalence ranges between 0.5 and 2 per 100,000 of the general population and is expected to increase further given the worldwide increase in obesity.(4) Prevalence in men has been estimated approximately at 9% of definite cases of IIH: such a gender difference does not exist in pre-pubertal timing, suggesting a possible role of sexual hormones in the determinism of the condition in women of child-bearing age. Like women, men suffering from IIH are mostly obese, but older at diagnosis with an average age of 37 years vs. 28 years in women.(5)

There are a lot of studies supporting a direct relationship between ICP, extramural sinus compression, and venous congestion.

Figure no. 1. Hypothesized feedback loop resulting in progressive sinus stenosis and elevations in ICP (6)

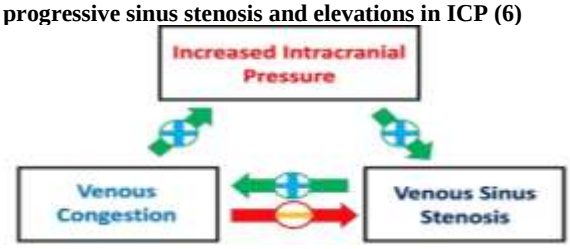

According to this hypothesis, increased ICP from an unclear condition causes extramural compression of the venous sinuses, leading to progressive outflow obstruction and resulting in intracranial venous congestion. Increasing venous pressures upstream of the stenosis results in further elevations in ICP in a positive feedback loop (figure no. 1).(6)

A significant trans-stenosis pressure gradient (TSPG) can be found with angiographic stenosis of only 30%–35%. Eventually, once the TSPG is severe enough, intramural venous pressures resist further extramural compression and an equilibrium is reached where high venous pressures and ICPs coexist.(7)

Given the fact that stenosis of the transverse sinus is also present in asymptomatic patients, it is unclear whether it is a cause or a consequence of increased ICP.(8)

Nonetheless, there exists a hypothesis that by breaking the positive feedback and treating the focal stenosis, there is a chance to lower the ICP.(2)

Several mechanisms have been proposed as the underlying cause of IIH, such as an overproduction of cerebrospinal fluid (CSF), outflow obstruction, elevated pressure in the venous sinuses and more recently a dysfunction in the glymphatic pathway as well as hormonal alterations.(4)

Obesity is noted in most cases of IIH, signifying a strong association of the disorder with weight. One of the early causation theories focused on the physical effects of increased abdominal mass, raising intrathoracic pressure and consequently increasing venous pressure.(2)

Given that none of these theories can explain the entire clinical picture, therapeutic approaches rely mainly on weight reduction and the decrease of CSF production with carbonic anhydrase inhibitors.(4)

IIH Treatment Trial (IIHTT) (9) is a trial which included 165 IIH patients with mild vision loss, comprising the largest cohort of IIH patients rigorously studied to date. The

[2]Corresponding author: Florin Grosu, B-dul. C. Coposu, Nr. 2-4, Sibiu, România, E-mail:drfloringrosu@gmail.com, Phone: +40746 097 966
Article received on 18.07.2022 and accepted for publication on 26.08.2022

baseline profile of IIHTT participants illustrates the prevalence of common symptoms (table no.1).(10)

Many of these symptoms are nonspecific, making clear that a diagnosis of secondary intracranial hypertension or IIH cannot be established based on symptoms alone. Although presentations of IIH are typically subacute and some are chronic, a minority of patients (<5%) have a fulminant presentation with rapidly progressive vision loss over the course of days to weeks.(10)

Table no. 1. Symptoms present at time of patient enrolment in the IIHTT14 (10)

SYMPTOM	PREVALENCE (n = 165)
Headache	84%
Vision changes	
Transient visual obscurations	68%
Vision loss*	32%
Diplopia	18%
Photophobia	48%
Tinnitus	
Pulsatile	52%
Nonpulsatile	23%
Dizziness	52%
Neck pain	42%
Back pain	53%
Cognitive disturbances	20%

*All patients in the trial had bilateral papilledema and mild vision loss on formal visual field testing as a trial entry criterion

Neuroimaging Changes in Intracranial Hypertension diagnosis of IIH is considered in some patients when findings associated with high ICP are found on magnetic resonance imaging (MRI) or computed tomography (CT) of the brain done for other reasons.(10) These include globe flattening, optic nerve protrusion into the vitreous, optic nerve widening with increased CSF spaces in the optic nerve sheath, empty sella, and transverse venous sinus changes.(11) While suggestive, these findings are not diagnoses of active intracranial hypertension due to their occurrence in normal individuals (12) as well as only partial normalization following treatment.(13)

The management algorithm can be subdivided into conservative or medical management, followed by surgical therapy if the patient fails the medical cure or alarming symptoms are present. The goal of the treatment is to preserve visual function and reduce headache disability. Obese patients are encouraged to lose weight and carbonic anhydrase inhibitors are the first line of medical therapy.(8,14)

Traditionally, repeated lumbar punctures were performed but the long-term benefit of this practice is not yet proven in the literature. If the patient fails medical therapy or his severe optic neuropathy can lead to permanent vision loss, surgical options should be considered. These include optic nerve sheath fenestration (ONSF), CSF diversion procedures, including either lumboperitoneal or ventriculoperitoneal shunting (15), bariatric surgery for obesity (16), and the newly introduced transverse sinus stenting.(8)

CASE REPORT

We present the case of a 23-year old patient with IIH evolving since April 2018, causing blindness for the left eye and currently on the rise.

Since the beginning of this year, the patient has reported a reappearance of the symptoms, with a decrease in visual acuity in the right eye. The ophthalmological examination revealed papilledema. Several evacuating lumbar punctures were performed in January and February 2022 (pressures 65 cmH2O - 45 cmH2O). His current treatment includes acetazolamide and potassium.

The various MRIs performed since 2018 (figure no. 2, figure no. 3) found extrinsic stenosis in the lateral sinuses. A cerebral angiography made possible to objectify a relative hypoplasia of the left lateral sinus, a dominant right lateral sinus, bilateral extrinsic stenosis at the junction between the transverse sinus and the sigmoid sinus (figure no. 4). A significant trans-stenotic gradient at the level of stenosis of the right lateral sinus of 18mmHg was found.

Figure no. 2. (A) MRI head sagittal T1 - weighted image showing empty sella sign, (B) MRI head imaging coronal T2-weighted image showing increased perioptic nerve CSF

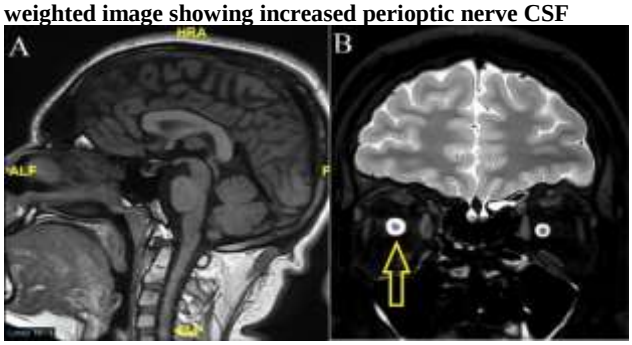

Figure no. 3. MRI head imaging T2 axial - showing posterior scleral flattening, optic nerve head protrusion and enhancement

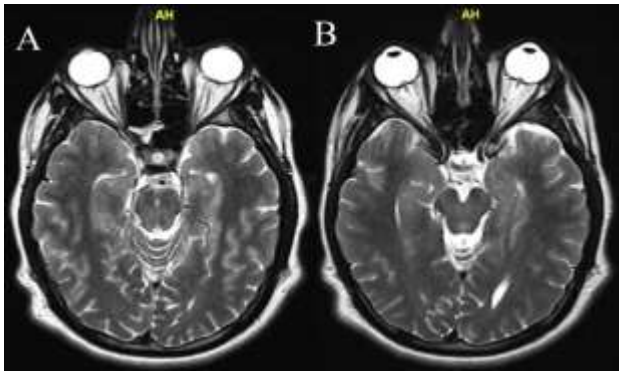

Figure no. 4. DSA, angiogram of the vertebral arteries, venous phase, PA view (A) and oblique view (B) showing relative hypoplasia of the left lateral sinus. Dominant right lateral sinus. Bilateral extrinsic stenosis at the junction between the transverse sinus and the sigmoid sinus

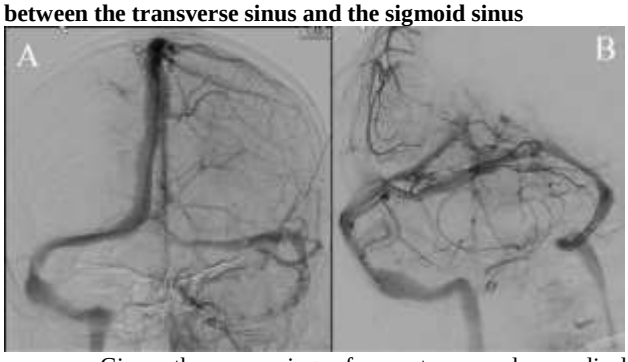

Given the worsening of symptoms under medical treatment, the risk of losing his residual vision in the right eye, as well as the high pressure gradient at the level of the venous stenosis, an indication for treatment by stenting the right lateral sinus was retained (figure no. 5).

The principle of venous stenting and the risks involved were discussed with the patient. A risk of less than 3% of venous infarction or hemorrhagic stroke in the right hemisphere or the posterior fossa is the periprocedural risks.

Brilique and Aspirin premedication to start one day before the intervention (to continue 3 months post-intervention, followed by aspirin alone for another year) were prescribed to the patient.

Figure no. 5. DSA, lateral view - Release of a 7x50mm Wallstent stent at the junction of the lateral sinus with the right sigmoid sinus covering the area of stenosis. In-stent angioplasty using a 7x20mm balloon

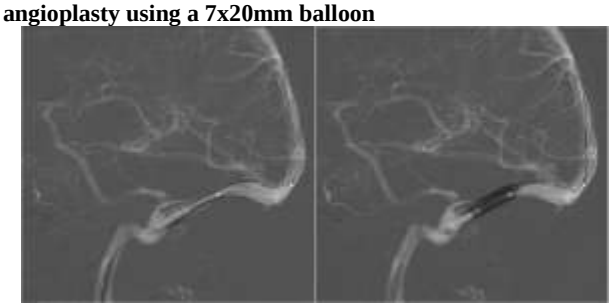

During the stenting procedure, an extrinsic-like stenosis at the transverse sinus junction of the right sigmoid sinus was found. At therapeutic time, stenting at this level with complete reduction of the stenosis was performed. The pressure measurements taken at the end of the operation no longer found a pressure gradient between the superior sagittal sinus and the jugular dome (average pressure under general anesthesia 23mmHg) (figure no. 6).

Figure no. 6. DSA of internal carotid artery, venous phase, lateral view - (A) Measurement of venous pressures (systolic/diastolic, average): significant trans-stenotic gradient at the level of the stenosis of the right lateral sinus 19mmHg (normal values < 8 mmHg), (B) Pressure measurements taken at the end of procedure no longer found a pressure gradient between the superior sagittal sinus and the jugular vein (mean pressure under general anesthesia 23 mmHg)

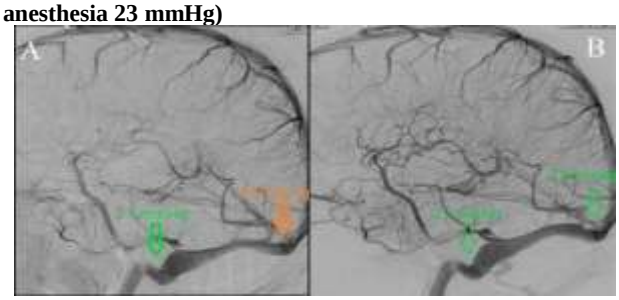

A 3-month follow-up cerebral angio-CT showed good patency of the stent located at the level of the lateral sinus and right sigmoid and a good permeability of large venous collectors. Also, the clinical condition has been improved. The patient no longer had any headaches and the sight has been improved slightly. Decreasing the dose of his treatment with acetazolamide was discussed.

DISCUSSIONS

For diagnosis of IIH, criteria A–E must be satisfied and no known secondary etiologies should be present. A probable diagnosis of IIH can be suggested if only criteria A–D are checked.(2,17)

Cerebral venous sinus stenting aims to reduce cerebral venous hypertension and by extension ICH by opening a stenosis in one of the transverse sinuses. Stenosis, either primary or secondary to high ICP, can be detected on MRV or CTV.

Catheter venography is used to confirm pressure gradient across the stenosis and deploy the stent. Experience is increasing with this relatively new procedure, which appears to be safe and effective in the short term in carefully selected patients.(10)

Table no. 2. Diagnostic criteria for IIH - Adapted from the 2013 revised diagnostic criteria (17)

A.	Papilloedema
B.	Normal neurological examination except cranial nerve abnormalities
C.	Neuroimaging: normal brain parenchyma without hydrocephalus, mass, or structural lesion, and no abnormal meningeal enhancement or venous sinus thrombosis on MRI or MR venography; if MRI is unavailable, contrast-enhanced CT can be used
D.	Normal CSF composition
E.	Raised lumbar puncture opening pressure (>25cmH2O in lateral decubitus)

Among all of the surgical options, the long-term outcomes of endovascular stenting with regards to visual function and headache when followed for 1 year were most promising, with improvement in visual acuity in 78% of cases and headache resolution in 77% of cases.(8)

When a dural venous stenosis is identified in a patient and where emergency surgical treatment is required, the most appropriate intervention that acts directly on venous sinus hemodynamics is venous sinus stenting.(18)

Furthermore, in deciding on therapeutic management for a patient with a minimal response to weight loss and medical cure, it is important to determine the degree of venous sinus stenosis. If a stenotic venous sinus is found with an increase trans-stenotic pressure gradient (e.g. ≥10 mmHg), venous sinus stenting may be appropriate. If stenosis is not present, or the trans-stenotic pressure gradient is sufficiently low to be clinically insignificant, one of the treatments to decrease ICP may be more convenient. One proposed set of criteria for dural venous sinus stenting in IIH is given in table no. 2.(18,19)

Table no. 2. Proposed criteria for dural venous sinus stenting in IIH adapted from Teleb et al (19)

Major Criteria (all required for qualification)
○ Failed MMT for at least one month or Fulminant course refractory to medical treatment with rapidly worsening vision. ○ Presence of pressure gradient across the stenosis ≥10 mmHg. ○ Pressure ≥25 mmHg. ○ Pulsatility seen on manometry that is attenuated post-stenosis. ○Visual changes, papilledema, or other focal objective neurological symptoms. Headaches only if severely disabling. ○ No contraindications to dual antiplatelet therapy.
Minor Criteria (one required for qualification)
○ Intolerance to repeated lumbar puncture or lumbar drain. ○ Diagnosis of DSS ≥50% on CT or MR venogram or catheter angiography. ○ Failed surgical shunting procedure or Failed optic nerve fenestration. ○ Patient preference

*Note: Reproduced from Teleb et al (19)., Stenting and Angioplasty for Idiopathic Intracranial Hypertension: A Case Series with Clinical, Angiographic, Ophthalmological, Complication, and Pressure Reporting. John Wiley and Sons. Copyright © 2013 by the American Society of Neuroimaging.

A meta-analysis identified 473 patients from 24 studies concluded that in patients with refractory IIH and venous sinus stenosis with elevated pressure gradient, venous sinus stenting is associated with a reduction in pressure gradient and ICP, improvement in signs and symptoms of IIH, and acceptable stent survival rates.(20)

Other surgical options such as ONSF and CSF diversion procedures act to reduce CSF pressure; do not act directly on venous sinus hemodynamics and therefore may not modulate the underlying cause.(18)

There is evidence that venous sinus stenting in the appropriate patient is also associated with a trend towards shorter duration of medical treatment with acetazolamide.(18)

The most common adverse episode reported in the literature was transitory post-procedure headache, typically lasting days, ipsilateral to the side of stenting. These headaches have been reported in one review to occur in around 30% of

patients.(21)

The most frequent cause of failure is re-stenosis, which can appear in or adjacent to a current stent. In-stent thrombosis may occur secondary to suboptimal location of the original stent with residual thrombosis proximal to the stent.(22)

This patient presents several typical criteria for this pathology. Even if women are more predisposed, we encounter this situation in a young, male patient, who presents the most important and frequent risk factor: obesity. Clinical manifestations are typical for IIH: headache and decreased visual acuity, as well as diagnostic findings: papilledema on fundus examination and CSF pressure of 69 cmH20 on lumbar puncture.

Repeated evacuations by lumbar puncture and treatment with acetazolamide failed to control the patient's condition, sinus venous stenting was decided. The evolution of this patient was favourable, the symptoms improving and the trans-stenotic gradient decreasing to normal values.

CONCLUSIONS

Idiopathic intracranial hypertension is a diagnosis of exclusion, but it is often difficult to make. Although IIH is most common among obese women in their 20s, it also may occur in children, and males adults. This pathology should be taken in consideration for this type of patients, especially if they also have headaches and/or visual disorders.

Confirmation of the diagnosis through measurement of ICP as well as careful assessment of optic nerve function and structure are important to guide management with the goal of preserving vision and controlling symptoms.

Venous sinus stenting has a low morbidity and high success rate at long-term follow-up for the treatment of IIH. There is evidence this type of stenting in the appropriate patient is also interrupts the vicious circle and improves intracranial pressure and clinical symptoms, associated with a trend towards shorter duration of medical treatment with acetazolamide.

Endovascular management of dural sinus stenosis appears technically feasible and safe. It is clinically efficacious in patients with IIH who have failed medical and surgical therapy with dural sinus stenosis.

REFERENCES

1. Boyter E. Idiopathic intracranial hypertension. JAAPA. 2019 May;32(5):30-35.
2. Markey KA, Mollan SP, Jensen RH, Sinclair AJ. Understanding idiopathic intracranial hypertension: mechanisms, management, and future directions. Lancet Neurol. 2016 Jan;15(1):78-91.
3. Thurtell MJ, Kawasaki A. Update in the Management of Idiopathic Intracranial Hypertension. Neurol Clin. 2021 Feb;39(1):147-161.
4. Raoof N, Hoffmann J. Diagnosis and treatment of idiopathic intracranial hypertension. Cephalalgia. 2021 Apr;41(4):472-478.
5. Toscano S, Lo Fermo S, Reggio E, Chisari CG, Patti F, Zappia M. An update on idiopathic intracranial hypertension in adults: a look at pathophysiology, diagnostic approach and management. J Neurol. 2021 Sep;268(9):3249-3268.
6. Fargen KM. A unifying theory explaining venous sinus stenosis and recurrent stenosis following venous sinus stenting in patients with idiopathic intracranial hypertension. J Neurointerv Surg. 2021 Jul;13(7):587-592.
7. Fargen KM. Idiopathic intracranial hypertension is not idiopathic: proposal for a new nomenclature and patient classification. J Neurointerv Surg. 2020 Feb;12(2):110-114.
8. Al-Mufti F, Dodson V, Amuluru K, Walia J, Wajswol E, Nuoman R, Keller IA, Schonfeld S, Roychowdhury S, Gupta G. Neuroendovascular Cerebral Sinus Stenting in Idiopathic Intracranial Hypertension. Interv Neurol. 2020 Jan;8(2-6):164-171.
9. Wall M, Kupersmith MJ, Kieburtz KD, et al; NORDIC Idiopathic Intracranial Hypertension Study Group. The idiopathic intracranial hypertension treatment trial: clinical profile at baseline. JAMA Neurol. 2014;71(06):693–701
10. Ahmad SR, Moss HE. Update on the Diagnosis and Treatment of Idiopathic Intracranial Hypertension. Semin Neurol. 2019 Dec;39(6):682-691.
11. Degnan AJ, Levy LM. Pseudotumor cerebri: brief review of clinical syndrome and imaging findings. AJNR Am J Neuroradiol. 2011;32 (11):1986–1993.
12. Kelly LP, Saindane AM, Bruce BB, et al. Does bilateral transverse cerebral venous sinus stenosis exist in patients without increased intracranial pressure? Clin Neurol Neurosurg. 2013;115(08):1215–1219.
13. Ranganathan S, Lee SH, Checkver A, et al. Magnetic resonance imaging finding of empty sella in obesity related idiopathic intracranial hypertension is associated with enlarged sella turcica. Neuroradiology. 2013;55(08):955–961.
14. Celebisoy N, Gökçay F, Sirin H, Akyürekli O. Treatment of idiopathic intracranial hypertension: topiramate vs acetazolamide, an open-label study. Acta Neurol Scand. 2007 Nov; 116(5):322–7.
15. Sinclair AJ, Kuruvath S, Sen D, Nightingale PG, Burdon MA, Flint G. Is cerebrospinal fluid shunting in idiopathic intracranial hypertension worthwhile? A 10-year review. Cephalalgia. 2011 Dec; 31(16):1627–33.
16. Spitze A, Malik A, Lee AG. Surgical and endovascular interventions in idiopathic intracranial hypertension. Curr Opin Neurol. 2014 Feb; 27(1):69–74.
17. Friedman DI, Liu GT, Digre KB. Revised diagnostic criteria for the pseudotumor cerebri syndrome in adults and children. Neurology. 2013; 81:1159–65.
18. Gurney SP, Ramalingam S, Thomas A, Sinclair AJ, Mollan SP. Exploring The Current Management Idiopathic Intracranial Hypertension, And Understanding The Role Of Dural Venous Sinus Stenting. Eye Brain. 2020 Jan 14;12:1-13.
19. Teleb MS, Cziep ME, Issa M, et al. Stenting and angioplasty for idiopathic intracranial hypertension: a case series with clinical, angiographic, ophthalmological, complication, and pressure reporting. J Neuroimaging. 2015;25:72–80.
20. Saber H, Lewis W, Sadeghi M, et al. Stent survival and stent-adjacent stenosis rates following venous sinus stenting for idiopathic intracranial hypertension: a systematic review and meta-analysis. Interv Neurol. 2018;7(6):490–500.
21. Dinkin MJ, Patsalides A. Venous sinus stenting for idiopathic intracranial hypertension: where are we now? Neurol Clin. 2017;35:59–81.
22. Shields LBE, Shields CB, Yao TL, et al. Endovascular treatment for venous sinus stenosis in idiopathic intracranial hypertension: an observational study of clinical indications, surgical technique, and long-term outcomes. World Neurosurg. 2019;121:e165–e171.