

HISTOLOGICAL EVALUATION OF INDIRECT PULP CAPPING PROCEDURES WITH CALCIUM HYDROXIDE AND MINERAL TRIOXIDE AGGREGATE

MONICA MONEA¹, ALEXANDRA STOICA², ADRIANA MONEA³

^{1,2,3}University of Medicine and Pharmacy Tirgu-Mures

Keywords: calcium hydroxide, MTA, dental pulp capping, tertiary dentin

Abstract: The purpose of our study was to obtain a histological comparison of tertiary dentin after indirect pulp capping procedures using calcium hydroxide or MTA in teeth with deep carious lesions, regarding its morphological characteristics and degree of inflammation induced to the dental pulp. We used 60 third molars with occlusal caries lesions from 30 patients of 17-26 years of age. Class I and II deep cavities were prepared and randomly restored with calcium hydroxide or MTA and glass ionomer cement. The histologic specimens were obtained at 2-4-6 weeks and the evaluation was done by the same person in a double blind manner. The results showed statistical significant differences between these capping materials regarding the formation rate and morphology of tertiary dentin induced by indirect pulp capping procedures. The success of this therapy is conditioned by the use of dental materials that contain or can deliver calcium hydroxide, completed with a final restoration without marginal leakage, which prevents microbial infiltration from oral cavity.

Cuvinte cheie: hidroxid de calciu, MTA, coafajul indirect, dentina terțiară

Rezumat: Scopul acestui studiu este de a compara rezultatele histologice obținute în urma coafajului indirect cu un preparat pe bază de hidroxid de calciu sau MTA în cazul cariei simple profunde, pe baza caracteristicilor morfologice ale dentinei de reacție și a gradului de inflamație al pulpei dentare. Au fost studiați 60 de dinți molari de minte cu carii ocluzale simple propuși pentru extracție în scop ortodontic, de la 30 de pacienți cu vârsta cuprinsă între 17-26 de ani. La aceștia s-au preparat cavități profunde de clasa I-a și a II-a obturate aleator cu un preparat pe bază de hidroxid de calciu sau MTA și ionomer de sticlă. Secțiunile histologice au fost obținute după 2-4-6 săptămâni și evaluate de aceeași persoană în manieră "dublă-orb". Rezultatele studiului arată diferențe semnificative din punct de vedere statistic privind viteza de depunere a dentinei terțiare și morfologia acesteia, prin influența celor două materiale folosite în terapia cariei simple profunde prin coafaj indirect. Succesul tratamentului este condiționat de folosirea materialelor care să conțină sau să elibereze hidroxid de calciu, iar reconstituirea coronară să asigure o bună închidere marginală, prevenind infiltrația microbiană de la nivelul cavității bucale.

INTRODUCTION

The principles that constitute the fundamentals for therapeutic concepts in dental caries are characterized by numerous modifications and intense controversy during the years in dental literature, mainly due to difficulties in reaching to the correct diagnosis and best treatment. A profound knowledge in the histopathology of dental pulp and dentin proved to be essential in evaluating the results of clinical studies regarding indirect pulp capping with different materials.(1-3)

After cavity preparation, the dentin is subjected to direct stimulation from oral cavity environment including microorganisms, that invade the dentinal tubules. Under these circumstances, the dental treatment should provide the total elimination of noxious factors and protection of dentin surface and subjacent dental pulp with materials that enhance the dentinogenetic mechanisms.(4) A thorough knowledge of deep caries histomorphology proved to be essential in the evaluation of clinical results obtain after indirect pulp capping procedures using different materials in order to maintain dental pulp vitality.(5)

During dental treatment of simple carious lesions, the protection of dentin-pulp complex is always justified and its purpose is to stop caries progression, to prevent dental pulp

inflammation, to stimulate tertiary dentin formation and remineralization of uninfected demineralized dentin.(6)

PURPOSE

The purpose of our study is to conduct a histological comparison of clinical results obtained after indirect pulp capping procedures in deep carious lesions using calcium hydroxide and MTA, based on morphology of tertiary dentin and degree of inflammation induced in the dental pulp.

METHODS

This study was conducted on 30 patients 17-26 years of age with a total of 60 third molars scheduled for extraction due to orthodontic reasons, that accepted to enter the study. All the patients, for those under 18 years of age the legal representatives, received complete information about aim, methodology and possible risks of the study and only after this procedure was completed they were asked to sign a written agreement, according to the rules of Commission of Research Ethics from our university.

The following including criteria were used:

- Teeth from clinic healthy patients, without systemic diseases that could influence the dental pulp reaction to

¹Corresponding author: Alexandra Stoica, Str. Gh. Marinescu, Nr. 38, Târgu Mureș, România, E-mail: stoicaalexandramihaela@gmail.com, Tel: +40746 115788

Article received on 14.07.2014 and accepted for publication on 04.08.2014
ACTA MEDICA TRANSILVANICA September 2014;2(3):315-318

CLINICAL ASPECTS

the capping material;

- Occlusal or proximal carious lesions that involved only one marginal crest;
- Carious lesion that can be easily restored by coronal filling;
- No clinical or radiographical signs of pulp or periapical inflammation.

From the total of 60 teeth we made 2 study groups with 30 teeth each that randomly received indirect pulp capping with either Life cement (Kerr) or MTA (Dentsply) (table no. 1). For the coronal filling we used light cured glass ionomer cement Kavitan LC (Spofa). Each group was further divided in 10 teeth that were extracted after an interval of 2-4-6 weeks and prepared for histological examination, based on the following protocol:

- Storage in formalin solution 10% for 10 days;
- Decalcification with EDTA solution 10% for 4 weeks;
- Dehydration with ethilic alcohol solution 90%;
- Paraffin inclusion;
- Sections of 3-5 microns were obtain and stained with Hematoxylin-Eosin and Trichrome Szekely.

The histological evaluation was made by the same investigator and was repeated for 10% of the specimens after 4 weeks from the first examination. Then histopathological changes of dental pulp were assessed based on the following criteria:

1. Normal pulp, without signs of inflammation;
2. A few inflammatory cells limited to the odontoblastic layer, without extension into the subjacent pulp tissue;
3. Presence of inflammatory reaction of the pulp subjacent carious lesion, with hyperemia, fibrosis and moderate inflammatory infiltrate.

The tertiary dentin formation was evaluated as follows:

1. Absence of tertiary dentin
2. Islands of tertiary dentin (interrupted layer of reactive dentin)
3. Complete bridge of tertiary dentin.

The morphological aspects of tertiary dentin formed were evaluated using the following scores:

1. Unidentified structural changes
2. Random demineralization at the coronary and radicular level of the pulp
3. Dentin reaction of amorphous nature, existence of cellular inclusions
4. Dentin reaction structure similar to physiological dentin reaction, presence of dentinal tubules

Table no. 1. Distribution of study groups regarding the type of cavity and capping material

Age	Cavity Class I		Cavity Class II	
	MTA	Life	MTA	Life
17	2	2	2	1
18	2	2	1	2
19	2	2	2	2
20	2	1	1	1
21	2	2	3	1
22	2	2	2	2
23	1	1	1	-
24	1	2	3	-
25	-	1	1	-
26	2	1	-	3

Statistical analysis was based on One-way ANOVA test from GraphPad Prism program, that was used to determine the differences between study groups regarding dental pulp inflammation (code 1-3), presence of tertiary dentin (scores 1-3)

and its morphology (scores 1-4) in relation with the capping material used, for a $p < 0,05$.

RESULTS

The percentage values calculated for the scores obtained for each study group are presented in tables 2-4. We encountered no failures, defined as spontaneous or induced pain after the treatment procedures.

Statistical analysis regarding tertiary dentin formation and morphological aspects of reparative dentin showed significant differences ($p < 0,0001$) between study groups treated with Life cement (noted by L2, L4 and L6 according to the moment of extraction) compared with MTA groups (noted as MTA2, MTA4 and MTA6).

In the groups MTA4 and MTA 6 we noted a complete tertiary dentin bridge 60% respectively 70% of the cases, compared to groups L4 and L6 where the values were 30% and 50% respectively.

In the case of tertiary dentin morphology in connection with the capping material used, in the groups MTA4 and MTA6 the aspect was similar to secondary dentin formed under physiological conditions, with dentin tubules present in 60% respectively 70% of the cases, where for the groups L4 and L6 the values were 20% and 30% respectively. The evaluation of dental pulp inflammation showed no statistical significant differences between the study groups ($p = 0,1997$).

Table no. 2. Rate of tertiary dentin formation

Group	Tertiary dentin formation		
	1	2	3
L2	40%	40%	20%
L4	30%	40%	30%
L6	10%	40%	50%
MTA 2	-	60%	40%
MTA 4	10%	30%	60%
MTA 6	-	30%	70%

$p < 0,0001$

Table no. 3. Morphological characteristics of tertiary dentin

Group	Morphology of tertiary dentin			
	1	2	3	4
L2	40%	10%	40%	10%
L4	30%	20%	30%	20%
L6	10%	30%	30%	30%
MTA 2	-	10%	20%	70%
MTA 4	10%	10%	20%	60%
MTA 6	-	10%	20%	70%

$p < 0,0001$

Table no. 4. Evaluation of dental pulp inflammation level

Group	Level of pulp inflammation		
	1	2	3
L2	80%	10%	10%
L4	80%	10%	10%
L6	90%	10%	-
MTA 2	80%	10%	10%
MTA 4	80%	20%	-
MTA 6	90%	10%	-

$p = 0,1997$

The histological evaluation of specimens from the study groups according to the capping material and the study period is presented in the following figures (figures no. 1-7):

Figure no. 1 Group L2. The presence of odontoblastic layer in close contact with predentin. Numerous capillaries present in the pulp tissue are an expression of intense metabolic activity. The tertiary dentin is formed. (Hematoxiniln – Eosin (H&E), X 20).

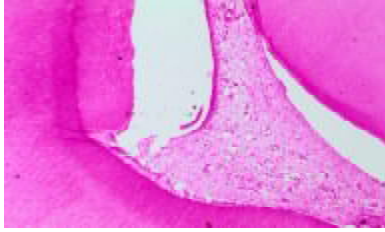

Figure no. 2 Group MTA 2. Pulp tissue with many cells and blood vessels, a well defined odontoblastic layer and a bridge of tertiary dentin with amorphous inclusions. (H&E, X 20).

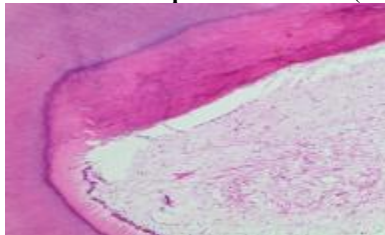


Figure no. 3 Group L4. A great population of cells in the dental pulp present also in the cell free zone, dilated blood vessels and a dense odontoblastic layer, beneath a thick bridge of tertiary dentin with dental tubules, similar to secondary dentin. (H&E, X 20).

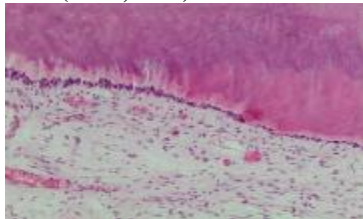


Figure no. 4 Group MTA 4. Thick barrier of tertiary dentin with dentin tubules surrounding a pulp tissue free of inflammation. (H&E, X20)

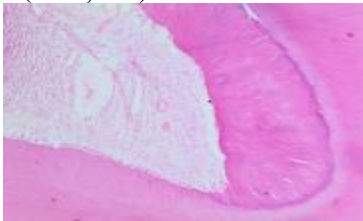


Figure no. 5 Group L6 Moderate pulp inflammation, reduced inflammatory cells infiltrate and a few dilated blood vessels. The tertiary dentin formed is rich in dentin tubules that seem to be in close connection with those of the secondary dentin. (Trichrome Szekely, X20)

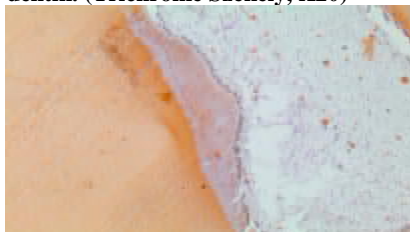

Figure no. 6. Group MTA 6. The presence of the odontoblastic layer beneath a thick predentin zone and above it a barrier of tertiary dentin with dentinal tubules. The aspect is characteristic to a mild pulpal stimulation, with the preservation of the normal histological aspect of the pulp tissue. (H&E, X 20).

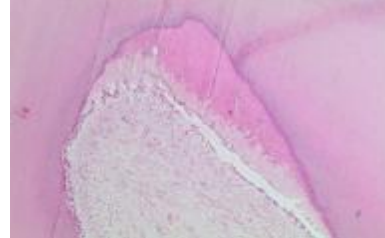
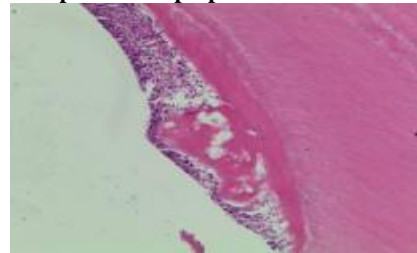


Figure no. 7 Group L6. Calcification in the pulp chamber with the development of a pulp stone.



DISCUSSIONS

The dental materials with calcium hydroxide used in capping procedures can induce tertiary dentin formation in deep carious lesions. This process takes place only in favourable morphological and functional conditions, represented by the presence of odontoblasts and undifferentiated mesenchymal cells which are responsible of dentinogenetic function.(7-9) These requirements are met only in young patients, as after 40-45 years of age there is an important decrease in cell population of dental pulp, accompanied by a reduction of dentinogenetic capacity.

For the teeth in our study groups, the therapy was successful in all the cases, as the patients were asymptomatic and vitality tests remained in normal limits compared to neighboring teeth. These excellent results were explained by correct diagnosis, complete removal of decayed dentin, the use of a proper pulp capping material (Life cement or MTA) and a coronal restoration that could prevent microleakage from the oral cavity. The importance of a good coronal seal was emphasized by many experimental and clinical studies, which demonstrated that the absence of microorganisms and nutrients at the interface of dental material with subjacent dentin will assure clinical success even in the presence of demineralized dentin at the base of dental cavity.(10-17)

Estrela and colab. (18) noted that pastes with calcium hydroxide have a better antimicrobial effect than Dycal and MTA against certain species (*Enterococcus faecalis*, *Pseudomonas aeruginosa*, *Bacillus subtilis*, *Staphylococcus aureus*) or fungi (*Candida albicans*). For Dycal the antibacterial effect was the least, results confirmed by Reeves et al (19). Similar results were published by Leye Benoist et al (20) who evaluated the tertiary dentin formation induced by Dycal and MTA in a group of teeth treated by indirect pulp capping and concluded that MTA gave better results. Ferracane and colab. (21) confirmed that only dental materials that contain or may release calcium hydroxide can induce the releasing of bioactive proteins as Transforming Growing Factor 1 beta (TGF 1 beta) which are present in the dentin and released under certain

condition in order to stimulate tertiary dentin formation.

The results of our study showed that Life cement represents an intense stimulating agent for tertiary dentin formation compared with MTA, due probably to the higher pH; MTA releases slowly the calcium hydroxide during setting time and therefore is considered to induce a mild stimulation.

The dental materials with calcium hydroxide demonstrated an excellent long-term success rate in deep caries therapy and therefore they have maintained an important role in modern conservative dentistry.(22) On the other hand, MTA also has the capacity to release calcium hydroxide and more, a very good dentin seal and setting in the presence of moisture.(23-25) All these allow us to conclude that today we have efficient therapeutic methods that can be used in the treatment of deep carious lesions and a carefully case selection will provide the best conditions in preserving the vitality of dental pulp.

CONCLUSIONS

Indirect pulp capping is a conservative treatment option that characterized by an excellent success rate in the treatment of deep carious lesions. For these results, it is mandatory to use dental materials with calcium hydroxide and to avoid microleakage after coronal restoration.

The results of our study showed that formation rate and histological aspect of tertiary dentin is influenced by the material used for indirect capping, but statistically significant differences were noted only on short-term follow up periods of 2-4 weeks.

MTA proved to induce a mild stimulation in inducing tertiary dentin compared to Life cement, but the morphological characteristics of this reparative dentin were more similar to secondary physiologic dentin. Anyway, these differences between pulp capping materials were less evident after longer periods of time.

REFERENCES

1. Briso ALF, Rahal V, Mestrenner SR, Dezan E. Biological response of pulps submitted to different capping materials. *Brazilian Oral Research* 2006;20(3):219-225.
2. Chacko V, Kurikose S. Human pulp response to Mineral Trioxide Aggregate (MTA): A histologic study. *J of Clin Ped Dent* 2006;30(3):203-209.
3. Anderson MH, Molvar MP, Powel LV. Treating dental caries as an infectious disease. *Oper Dent* 1991;16:21-28.
4. Bjorndal L. Dentin and pulp reactions to caries and operative treatment: biological variables affecting treatment outcome. *Endodontic Topics* 2002;(1601-1538):10-23.
5. Bjorndal L. Dentin caries: Progression and clinical management. *Operative Dentistry* 2002;27:211-217.
6. Bjorndal L, Thylstrup A. A structural analysis of approximal enamel caries lesions on subjacent dentin reactions. *Eur J Oral Sci* 1995;103:25-31.
7. Bjorndal L. Indirect pulp therapy and steways excavation. *J Endod* 2008, 34: 29-33.
8. Casagrande L, Bento LW, Dalpian DM, Garcia-Godoy. Direct pulp treatment in primary teeth: 4-year results. *Am J Dent* 2010;23:34-38.
9. Senawongse P, Otsuki M, Tagami M, Mjör IA. Morphological characterization of attrited human dentine. *Arch Oral Biol* 2008;53:14-19.
10. Briso ALF, Rahal V, Mestrenner SR, Dezan E. Biological response of pulps submitted to different capping materials. *Brazilian Oral Research* 2006;20(3):219-225.
11. Espelid I, Fjeltveit K. Clinical diagnosis of occlusal dentin carries. *Caries Res* 1999;28:368-372.
12. Stevenson AG, Beeley JA. The specificity of caries detector in cavity preparation. *Br. Dent J* 2002;176:417-421.
13. Pashley DH. Clinical correlations of dentine structure and function. *J Prosthet Dent* 1991;66:777-781.
14. Al-Hiyasat AS, Barrieshi-Nusair KM, Al-Omari MA. The radiographic outcomes of direct pulp capping procedures performed by dental students. *J Am Dent Assoc* 2006;137:1699-1705.
15. Costa CA, Giro EM, Nascimento AB, Teixeira HM, Hebling J. Short term evaluation of the pulpo-dentin complex response to modified glass-ionomer cement and a bonding agent applied in deep cavities. *Dent Mater* 2003;19:739-746.
16. Snuggs HM, Cox CF, Powell CS, White KC. Pulpal healing and dentinal bridge formation in an acid enviroment. *Quintessence Int* 1993;24:501-510.
17. Faraco IM, Holland R. Response of the pulp of dogs to capping with MTA or calcium hydroxide cement. *Dent Traumatol* 2001;17:163-166.
18. Estrella CR, Bammann LL, Silva RS, Pecora JD. Antimicrobial and chemical study of MTA, Portland cement, calcium hydroxide paste, Sealapex and Dycal. *Braz Dent J* 2000;11:3-9.
19. Reeves R, Stanley HR. The relationship of bacterial penetration and pulpal pathosis in carious teeth. *Oral Surg Oral Med Oral Pathol* 1966;22:59-65.
20. Leye Benoist F, Gaye Ndiaye F, Kane AW, Benoist HM, Farge P. evaluation of Minerale Trioxid Aggregate versus calcium hydroxide cement (Dycal) in the formation of dentin bridge: a randomized controlled trial. *Int Dent J* 2012;62:33-39.
21. Ferracane JL, Cooper PR, Smith AJ. Can interrraction of materials with dentin-pilp complex contribute to dentin regeneration. *Odontology* 2010;98:2-14.
22. Accorinte MLR, Loguercio AD, Reis A, Carneiro E, Grande RHM, Murata SS, Holland R. Response of human dental pulp capped with MTA and calcium hydroxide powder. *Operative Dentistry* 2008;33-5:488-495.
23. Olsson H, petersson K, Rohlin M. Formation of a hard tissue barrier after pulp cappings in humans. A systematic review. *Int Endod J* 2006;39(6):429-442.
24. Olsson H, Petersson K, Rohlin M. Formation of a hard tissue barrier after pulp cappings in humans. A systematic review. *Int Endod J* 2006;39(6):429-442.
25. Furey A, Hjelmhaug J, Lobner D. Toxicity of Flow line, Durafill, vs Dycal to dental pulp cells. Effects of growth factors. *J Endod* 2010;36:1149-1153.