

CORRELATIONS BETWEEN PRECANCEROUS LESIONS AND MELANOCYTIC AND NON-MELANOCYTIC SKIN CANCERS

MARIA ROTARU¹, GABRIELA IANCU²

^{1,2}“Lucian Blaga” University of Sibiu

Keywords:

precancerous lesions, nonmelanoma skin cancers, melanocytic skin cancers

Abstract: Nonmelanocytic skin cancers (NMSC) are the most common frequent of skin cancers, which may appear de novo, in normal skin or on precancerous cutaneous lesions. There are many pre-existing lesions holding a potential to transform in skin cancers. Of these, the most common are actinic and seborrheic keratoses, sebaceous nevus, leukoplakia etc. Malignant melanoma (MM) can appear after a malignant transformation of melanocytic lesions or of nevi with a dysplastic potential or de novo in apparently healthy skin. Lately, the medical community has observed more frequent de novo MM than the ones building upon underlying nevi lesions. Based on these data and taking into account that the diagnosis and treatment of precancerous lesions would allow reducing the incidence of skin malignancies and thus mortality, especially in MSC, we conducted a prospective study in which we analyzed precancerous lesions and the NMSC and MSC that appeared on these.

Cuvinte cheie: leziuni precanceroase, tumori cutanate melanocitare, tumori cutanate nonmelanocitare

Rezumat: Tumorile cutanate nonmelanocitare (TCNM) sunt cele mai frecvente neoplazii cutanate, acestea putând apărea de novo, pe tegumente indemne sau pe leziuni precanceroase preexistente. Există o multitudine de leziuni preexistente, cu potențial de transformare în cancere cutanate dintre care cele mai frecvente sunt keratozele actinice și seboreice, nevil sebaceu, leucoplazia, etc. Melanomul malign (MM) poate apărea prin transformarea malignă a unor leziuni melanocitare, respectiv a unor nevi cu potențial displazic sau de novo, în piele aparent sănătoasă. În ultimul timp s-a observat apariția mai frecventă a MM de novo, decât pe leziuni nevice preexistente. Plecând de la aceste date și luând în considerare faptul că diagnosticarea și tratamentul leziunilor precanceroase ar permite scăderea incidenței neoplaziilor cutanate și implicit a mortalității, în special prin TCM, am realizat un studiu prospectiv în care am analizat leziunile precanceroase și TCNM și TCM aparute pe acestea.

INTRODUCTION

Malignant transformation of precancerous lesions is suspected when there are changes in the shape, size, colour and texture of the lesions. In the case of NMSC, the malignant transformation of precancerous lesions takes a long period of time, sometimes even decades, unlike the MSC, where changes can occur very rapidly.

Precancerous lesions that are most commonly transformed in basal cell carcinomas (BCC) and squamous cell carcinoma (SCC) are actinic keratoses, seborrheic rarely, leukoplakia (specifically for SCC lip) etc. In 2009, Criscione et al published a study on a total of 7784 of actinic keratoses, observing that the risk of transformation in SCC ranged from 0.6% after 1 year and 2.57% after four years, and that the risk of transformation in BCC varied between 0.48% after 1 year and 1.97% after 4 years.(1)

Where MM appeared on precancerous lesions, it was observed that the lesions were atypical nevi structures, in which, at a certain moment, architectural and structural changes occurred, drifting towards malignancy. In existing studies, over 50% of MM appears on existing nevi lesions, the percentage ranging and depending on clinical or histopathological criteria. By corroborating clinical and histopathological criteria, it is considered that 39.5% of MM appears upon pre-existing structures of nevi.(2) The importance of the diagnosis and treatment of precancerous lesions lies in the possibility of decreasing the incidence and mortality of skin cancer. Since

NMSC are the most common of skin cancers, the decrease in their incidence will allow an earlier diagnosis, treatment in the early stages and a total reduction of costs, which could alternatively be used for the initiation of dermato-oncologic education programmes.

METHODS

We conducted a prospective study over a period of three years in cases of MSCT and NMSC in the department and outpatient of Dermatology and Oncology from the Clinical Hospital, Sibiu. 385 patients with skin tumours were kept under observation, including 275 with BCC, 57 SCC and 83 with MM. We made a questionnaire for patients affected by NMSC and MSC - the data were extracted from the observation sheets and the dermato-oncologic sheets of patients with skin tumours.

In our group of patients, in addition to the demographic data, we followed the emergence of MSC and NMSC upon new or preexisting lesions, as well as the correlation between precancerous lesions and the type of skin tumour. Data were statistically analyzed using SPSS version 10.

RESULTS

Of the total of 385 skin tumours included in our study most were NMSC (78.44%), while MSC constituted the rest (21.56%). The most common skin tumours were BCC, representing 81.12% of NMSC and 63.64% of patients from group 1; SCC tumours were at 18.87% of NMSC and 14.80% of

¹Corresponding author: Maria Rotaru, Bvd. Corneliu Coposu, Nr. 2-4 Sibiu, România, E-mail: mrotaru07@gmail.com, Tel: +40269 215050
Article received on 22.10.2014 and accepted for publication on 11.11.2014
ACTA MEDICA TRANSILVANICA December 2014;2(4):265-267

CLINICAL ASPECTS

the total skin tumours (figure no. 1).

Figure no. 1. Group distribution upon the type of tumour

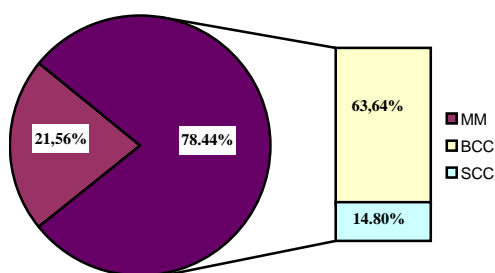
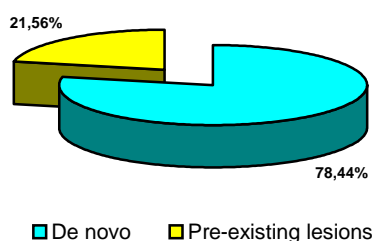
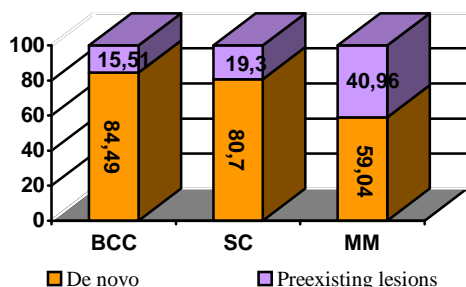


Figure no. 2. The correlation between preexisting lesions and cutaneous tumours



From analyzing the results, we noticed that NMSC and MSC mostly occurred de novo (78.44%) (figure no. 2).

Figure no. 3 Correlations between preexisting lesions and skin cancers



By conducting a comparative analysis of NMSC / MSC, we noticed that NMSC occurred more frequently on normal skin without preexisting lesions (82.59%), compared with MSCT (59.04%) ($p = 0.006^{**}$) (figure no. 3).

BCC occurred most frequently de novo (84.49%), followed by the appearance on the scars (8.16%) and actinic keratosis (7.35%), the results being statistically significant ($p = 0.000^{**}$).

SCC developed most frequently de novo (80.70%), followed by the appearance on cheilitis (8.77%) on actinic keratosis (7.03%), on scars and ulcers (1.75%), the results being statistically significant ($p = 0.000^{**}$).

Our results reveal a roughly equal proportion of actinic keratosis converted into BCC (7.35%) and SCC (7.03%), in contrast to data found in the literature, where the malignant transformation of actinic keratoses in the SCC is higher than in BCC.(1).

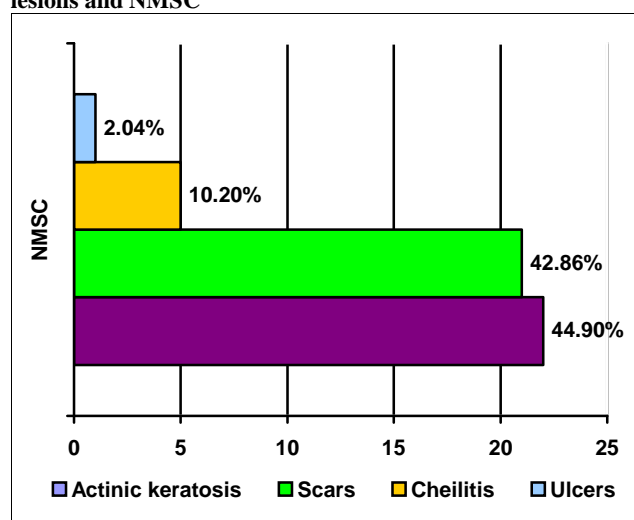
MM appeared de novo in 59.04% of the cases, with the rest (40.96%) attributed to malignant transformations of the nevi lesions ($p = 0.651$) (table no. 1), the results being similar to those in medical literature.(2)

Table no. 1. Analysis of precancerous lesions in the group of patients

Preexisting lesions	BCC	SCC	MM	Total
De novo	207(84,49%)	46(80,70%)	49 (59,04%)	302(78,44%)
Actinic keratoses	18(7,35%)	4 (7,03%)	0	22 (6,38%)
Scars	20 (8,16%)	1(1,75%)	0	21 (5,45%)
Cheilitis	0	5 (8,77%)	0	5 (1,30%)
Ulcer	0	1 (1,75%)	0	1 (0,26%)
Nevi	0	0	34 (40,96%)	34 (8,83%)
p	0,000**	0,000**	0,651	

The NMSC that appeared on precancerous lesions and turned malignant, the most common preexisting lesions were actinic keratoses (44,90%), scarring (42,86%), cheilitis (10.20%) and ulcers (2.04%) (figure no. 4).

Figure no. 4 Correlations between the types of precancerous lesions and NMSC



DISCUSSIONS

Skin tumours can either arise de novo, on healthy-looking skin, or as a result of a malignant transformation of precancerous lesions or dysplastic nevi. In our study, skin cancers occurred predominantly de novo (78.44%), with the following distribution: 84.49% in NMSC and 59.04% in MSC.

In the literature, it was argued that the types of precancerous lesions which can set off NMSC are very diverse, including actinic keratoses and seborrheic, sebaceous nevus, basal cell nevi syndrome, epidermodysplasia verruciformis, vaccination scars, tattoos, chronic radiodermatitis, leukoplakia, erosive oral lichen planus, Bowen disease, eritroplazia, discoid lupus erythematosus (3), varicose ulcers, lupus vulgaris, necrobiosis lipoidica, sclerose-atrophic lichen, deep chronic fungal infections, epidermolysis bullosa (4,5), burns (6), osteomyelitis, acne conglobata, cellulite dissecans of the scalp, hidradenitis suppurativa, lymphogranuloma venereum etc.(7,8,9)

In this study, the most common pre-existing lesions in patients with BCC were scars (8.16%) and actinic keratoses (7.35%).

In patients with SCC, the most common precancerous lesions were cheilitis (8.77%) and actinic keratoses (7.05%). A special case worth noting was that of a malignant transformation into SCC of a mixed arterio-venous ulcer localized on the ankle that had been in the florid phase for several years. After three years since the amputation of the affected lower limb, the patient is alive without metastases. (Note: In our patient, this particular

CLINICAL ASPECTS

ulcer had first appeared 25 years ago, scarring repeatedly and presenting vicious epithelization). The studies published on the subject recognize that the transformation of chronic scarring in SCC may occur on average after 35 years (10), with a 30% rate of metastasis (10,11), and a 33% mortality rate.(12)

In a group of 200 patients with invasive SCC, the risk of metastasis was 12.5%, which was correlated with tumour size, grade of differentiation, perineural invasion and recurrence.(13)

MM may arise “de novo” in about 60% of cases, the rest arising from dysplastic nevi or nevi with a modified clinical character.(2) Patients with dysplastic nevi have a higher risk of developing MM during their lifetime, either through the evolution of a mole or directly on healthy skin (14); the presence of atypical nevi may be considered to be a marker for the identification of a category of patients with the relative risk for the development of MM.

In the group of patients with MM, 59.04% of the cases occurred de novo. This result is almost identical to the one from the literature.(2)

By analyzing the pre-existing lesions that turned malignant, we noticed that MSC developed upon clinically changed nevi (40.96%) and NMSC developed upon actinic keratoses, scars, cheilitis and mixed arteriovenous ulcers.

These results converge to the same idea: recognition of precancerous lesions and of dysplastic nevi, as well as establishing effective and early therapeutic measures could allow a significant decrease in the incidence of skin malignancies in the future and their diagnosis in the early stages of the disease. In this case, public education plays a very important role; the prospective patient should consult a dermatologist as soon as she identifies new skin lesions or any changes in nevi preexisting lesions. Unfortunately, in Romania patients delay consulting their doctor when faced with a suspicious lesion due to a scientifically unfounded fear of metastasis resulting from the tumour excision. Removing this fear will allow us to finally be aligned with developed countries, where patients seek endorsed medical advice in a much more timely manner.

In Australia, where the incidence of skin cancers, particularly MM, is high, the diagnosis is carried out to a large extent by the patient and the primary medical network, and it is then certified by dermatologists. This is reflected in the diagnosis of the disease in the early stages, a decrease of mortality in these tumours and a reduction of their treatment material resources.

CONCLUSIONS

1. In our group of patients, the clinical distribution on forms of tumour was: 63.64% BCC 21.56% MM and 14.80% SCC.
2. In our study, skin cancers occurred predominantly de novo (78.44%). Over two thirds of NMSC appeared on seemingly healthy skin (84.49%) and 59.04% of MSC arose de novo.
3. In the NMSC group that appeared on preexisting lesions, the most common pre-cancers were actinic keratoses (44,90%) and scarring (42,86%), followed by cheilitis (10.20%) and ulcers (2.04 %).
4. The identification of pre-existing lesions, as well as a timely treatment, would reduce the incidence of both skin malignancies and mortality, especially in MSC.

REFERENCES

1. Criscione VD, Weinstock MA, Naylor MF et al. Natural history and risk of malignant transformation in the

- Veterans Affairs Topical Tretinoin Chemoprevention Trial, Cancer, Jun 2009;115(11): 2523-30.
2. Chang AE, Ganz PA, Hayes DF et al. Oncology, Spinger Science – Business Media Inc USA; 2006.
3. Harper JG, Pilcher MF, Szlam S, Lind DS - Squamous cell carcinoma in an African American with discoid lupus erythematosus: a case report and review of the literature. South Med J Mar 2010;103(3):256-9.
4. Mallipeddi R et al. Epidermolysis bullosa and cancer. Clin Exp Dermatol. Nov 2002;27(8):616-23.
5. Fine JD, Johnson LB, Weiner M, Li KP, Suchindran C - Epidermolysis bullosa and the risk of life-threatening cancers: the National EB Registry experience, 1986-2006. J Am Acad Dermatol Feb 2009;60(2):203-11.
6. Kowal-Vern A, Criswell BK - Burn scar neoplasms: a literature review and statistical analysis. Burns. Jun 2005;31(4):403-13.
7. Lal S et al. Saree Cancer: The Malignant Changes in Chronic Irritation. Journal of clinical and diagnostic research. Retrieved 12 November 2012.
8. Monroe MM, Meyer AD, Alam M, et al. Cutaneous squamous cell carcinoma, 2014, <http://emedicine.medscape.com/article/1965430-overview#showall>.
9. Turegun M, Nisanci M, Guler M - Burn scar carcinoma with longer lag period arising in previously grafted area Burns Sep 1997;23(6):496-7.
10. Moller R, Reymann F, Hou-Jensen K. Metastases in dermatological patients with squamous cell carcinoma. Arch Dermatol Jun 1979;115(6):703-5.
11. Novick M, Gard DA, Hardy SB, Spira M - Burn scar carcinoma: a review and analysis of 46 cases. J Trauma Oct 1977;17(10):809-17.
12. Arbiser JL, Fan CY, Su X, et al. Involvement of p53 and p16 tumor suppressor genes in recessive dystrophic epidermolysis bullosa-associated squamous cell carcinoma. J Invest Dermatol Oct 2004;123(4):788-90.
13. Cherpelis BS, Marcusen C, Lang PG. Prognostic factors for metastasis in squamous cell carcinoma of the skin Dermatol Surg 2002;28(3):268-273.
14. Cho E et al. Risk factors and individual probabilities of melanoma for whites. J Clin Oncol 2005;23:2669-75.