

# GOLDEN PROPORTION USED IN SELECTION AND ARRANGEMENT OF ARTIFICIAL TEETH IN COMPLETE DENTURES - CASE REPORT

VIOREL ȘTEFAN PERIEANU<sup>1</sup>, MĂDĂLINA VIOLETA PERIEANU<sup>2</sup>, ANCA TEMELCEA<sup>3</sup>, DANA CRISTINA BODNAR<sup>4</sup>, TRAIAN BODNAR<sup>5</sup>, ION ALEXANDRU POPOVICI<sup>6</sup>, ION PĂTRAȘCU<sup>7</sup>

<sup>1,2,3,4,5,6,7</sup> "Carol Davila" University of Medicine and Pharmacy Bucharest

**Keywords:** golden section grid, complete denture

**Abstract:** Choosing and arranging the adequate teeth in complete dentures is extremely important from an aesthetic point of view. In most of the cases, the decision is purely subjective (considering only the patient's desire) but can be strongly influenced by the dentist. Thus, the "golden proportion" can eliminate many sources of errors during dental treatment and at the same time, it offers the patients a natural smile.

## INTRODUCTION


Harmony and perfection in creation have been related to "golden proportion" since the antiquity. At first, this concept was applied to buildings and art, but Leonardo Da Vinci was the first to demonstrate that human body also hides this "golden number (1,618...)" in many ways.

The "golden proportion" of the face has been extensively documented in the specialty literature by Levin E., Ricketts R.M., Mack M.R. etc.(1,2,3)

This case report illustrates the use of the "golden proportion grid" (figure no. 1) conceived by Dr. E. Levin (1978) who optimized the smile dimension and the mesio-distal width of the upper central incisor.

There was used the proportion between the width of the upper central incisor and the visible front width of upper lateral incisor, upper canine, first upper premolar. Based on these measurements a correlation has been established between the "half width of smile" and the "half of the anterior aesthetic segment".

**Figure no. 1. "Golden section grid" by Dr. E. Levin (1978)**



## General information

To better understand the concept of the "golden proportion", the significance of different segments on the golden section grid will be defined, as seen from the front:(1-5)

- A: width of first upper premolar;
- B: width of upper canine;
- C: width of upper lateral incisor;
- D: width of upper central incisor;
- E: half width of anterior aesthetic segment;
- F: half width of smile.

There is a correlation between the above segments which imply the "golden number", and all the calculations start from the width of the upper central incisor.(1-5)

$$D = C * 1.618$$

$$C = B * 1.618$$

$$B = A * 1.618$$

$$E = A + B + C + D$$

$$F = E * 1.618$$

The dental practitioner chooses the artificial teeth set on the basis of the width of the upper central incisor. The manufacturers of artificial teeth produce a large variety of sets with different mesio-distal sizes. These teeth are delivered in single/double or in rows (maxillary or mandibular) or in complete sets. The producers also offer sets of the front six, lateral, top and bottom teeth only.

When using fractioned artificial sets, the manufacturers offer a tooth selection chart that facilitates the selection of corresponding sizes to match the selection of anterior teeth.(1-5)

The "golden section grid" (by Dr. E. Levin) is used by dental technicians in order to obtain an aesthetic arrangement of the artificial teeth.

## CASE REPORT

A 62-year-old female patient presented in the dental office with untreated maxillary Kennedy Class II mod I edentation and mandibular Kennedy Class I mod I edentation (figure no. 2).

Both clinical and paraclinical examination of the patient were performed. It was decided to extract the remaining

<sup>2</sup>Corresponding author: Mădălina Perieanu, B-dul. Constantin Brâncoveanu, Nr. 13, Bl. B16, Sc. 5, Et. 4, Ap. 132, Sect. 4, București, România, E-mail: trili\_poli@yahoo.com, Phone: +40723 472632

Article received on 15.10.2014 and accepted for publication on 17.11.2014

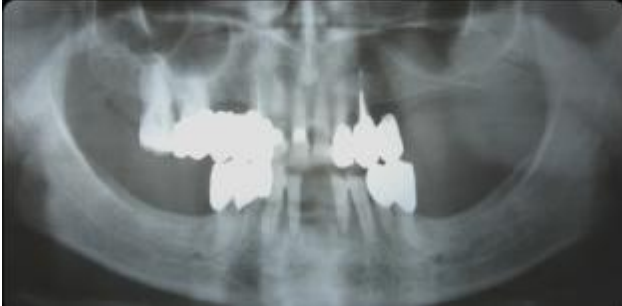ACTA MEDICA TRANSILVANICA March 2015;20(1):116-117

## CLINICAL ASPECTS

teeth because they have no prosthetic value. The adequate treatment option was implant supported complete dentures rehabilitation.

The artificial teeth were chosen by using the “golden section grid”. At first, the width of smile when viewed from the front was measured with a compass. Based on the values obtained, the appropriate “golden grid” was selected and thus the adequate mesio-distal width of the upper central incisor.(1-5)

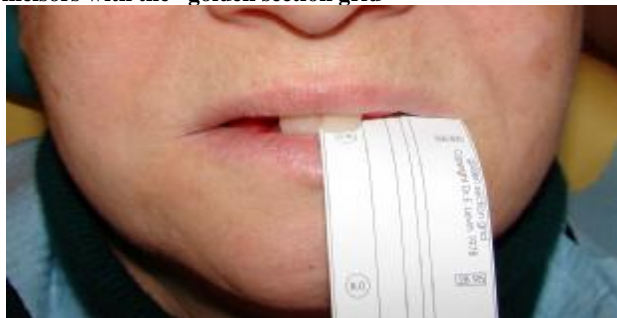**Figure no. 2. Panoramic X-ray of initial dental status**



The dental technician assembled the upper central incisors on the maxillary wax occlusal rim to verify the right dimension of the teeth.

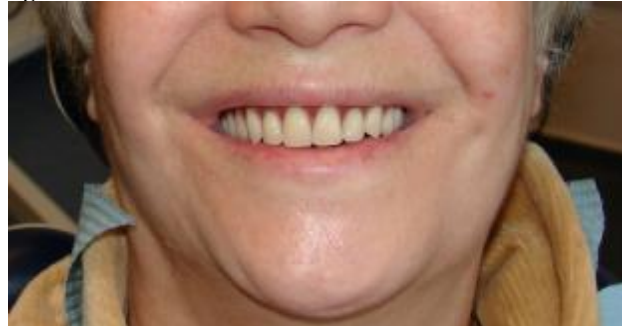With the occlusal rim in place, there was a perfect correlation between the width of upper central incisor and the width of half smile when compared to the “golden section grid” (figure no. 3).

**Figure no. 3. Verifying the choice of the upper central incisors with the “golden section grid”**



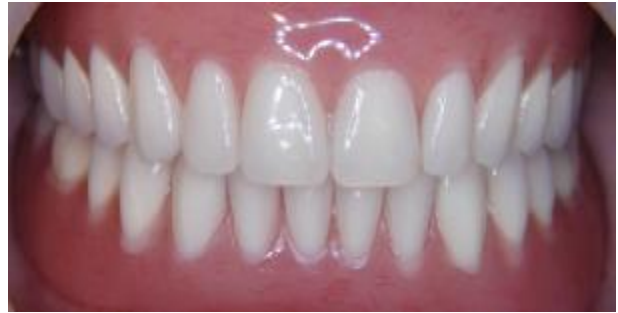Using the “golden proportion grid” the dental technician mounted the artificial teeth on the complete denture obtaining a natural smile (figure no. 4).(1-5)

**Figure no. 4. Beautiful natural smile after oral rehabilitation**



The function and aesthetic of the patient had been monitored at 1 month, 6 month, 1 year and 2 years (figure no. 5).

**Figure no. 5. Harmonious aspect of the two complete dentures in occlusion**



## CONCLUSIONS

“Golden proportion” between different elements of the face is considered a useful tool in designing a beautiful and natural smile.(4)

Scientific analysis of beautiful smiles has shown that this principle can be systematically applied to evaluate and improve denture esthetics in predictable ways.(4,5)

This concept also improves the collaboration between dentist and technician where it comes to choosing and setting teeth for complete dentures.(5)

## REFERENCES

1. Levin E. Dental esthetics and the golden proportion. J. Prosthet Dent. 1978 Sept;40:244-52.
2. Ricketts RM. Divine proportion in facial esthetics. Clin Plast Surg. 1982 Oct;9(4):40/1-22.
3. Mack MR. Perspective of facial esthetics in dental treatment planning. J Prosthet Dent. 1996 Feb;75(2):169-76. Review.
4. Constantinescu MV, Feinmann PB, Hutu E, David D, Constantinescu FE. Utilizarea numărului de aur în medicina dentară. Revista Română de Stomatologie. 2006;LII:1-2,12/71-6.
5. Seth V, Kamath P, Prasad R, Vishwanath M. Creating a new smile and a new life with orthodontics. Orthodontic CYBER Journal, August 2011, [www.orthocj.com](http://www.orthocj.com).