ACTA MEDICA TRANSILVANICA June 26(2):36-40
DOI: 10.2478/amtsb-2021-0031
Online ISSN 2285-7079

MADELUNG DISEASE – BETWEEN LIPECTOMY AND LIPOSUCTION. REPORT OF A CASE AND LITERATURE REVIEW

ALIN MIHEȚIU[1], ALEXANDRA SANDU[2], FLORIN FLUTURE[3], FLORIN DUȚĂ[4]

[1,4]Sibiu County Clinical Emergency Hospital, [2]"Lucian Blaga" University of Sibiu, [3]Emergency Hospital, Râmnicu Vâlcea

Keywords: *Madelung disease, lipomatosis, alcohol, lipectomy, liposuction*

Abstract: *Madelung's disease or multiple symmetric lipomatosis could be described as being anything, but an ordinary entity. The etiopathogenetic mechanisms are admittedly multifactorial, debatable and not marked by promptness. Despite the aesthetic, most of the symptoms are direct results of the compression which occurs on the adjacent anatomical structures. Because of their characteristic appearance, patients with this condition can be clinically diagnosed, during the information-gathering process or while performing a physical exam. So far, the treatment of choice was surgical resection, leading to a well-pleasing outcome and reducing the risk of recurrence.*

INTRODUCTION

Madelung's disease, also called multiple symmetric lipomatosis, was first mentioned by Benjamin Brodie in 1846. Studies with more extended data followed in 1888 and 1898 and were conducted by Madelung, respectively by Launois and Bensaude. "Launois-Bensaude disease" subsequently became an eponym for this disorder, being frequently used in the medical literature.

The condition itself is not considered as life-threatening, but comorbidities that may associate could lead to critical situations. Males aged 30-70 years-old are predominantly affected (male: female ratio of 15:1), with an increased prevalence in the Mediterranean and Eastern Europe areas.(1, 2,3,4)

The vast majority of the patients have a history of daily alcohol intake. Masses of adipose tissue were mostly observed to develop within the neck region. Patients who are usually demanding treatment, are incriminating the aesthetic disturbances, but more severe complications can occur due to loco-regional impairment.

Madelung's disease is a rare disorder, with 300 reported cases in the medical literature, heretofore. The treatment plan must be multimodal, including surgical removal of the fat pads and patient's adherence to behavioural and dietary guidance. If there are any associated diseases, treatment should be adapted accordingly to their occurrences and to the patient's predisposing factors.(5,6)

CASE REPORT

A 58-year-old male patient was referred to our department complaining about painful, swollen and large masses in the supra and infraclavicular regions, as well as in the superior cervical region. He experienced difficulty breathing, mostly during the night time (nocturnal dyspnea). The patient had significant previous history of sinus tachycardia, high blood pressure, hepatic steatosis, post tuberculosis sequelae and chronic alcohol abuse.

Hands-on examination of the patient revealed signs of pain and lumps of adipose tissue, which varied in size, having the typical features of lipomas: firm, semimobile, palpable. The fatty deposits were symmetrical, nonencapsulated, with no precise delimitation, situated at the level of the upper thorax, anterior, lateral and posterior cervical regions. Similar enlargements were afterwards noticed in the presacral space. Laboratory tests were ranged between the normal values of the parameters. Ultrasound imaging of the soft-tissues detected hypoechoic, imprecisely delimited lesions, with no demonstrable flow on Doppler imaging and with usual lipoma characteristics.

Patient's clinical appearance was suggestive for multiple symmetric lipomatosis, known as Madelung's disease, because of the representative pseudoathletic aspect.

Figures no. 1, 2, 3, 4. Clinical aspect of Madelung disease in patient reported

[2]Corresponding author: Alexandra Sandu, Str. Iazului, Nr. 2A, Ap. 5, Sibiu, România, E-mail: alexandrasandu96@yahoo.ro, Phone: +40766 722364
Article received on 11.05.2020 and accepted for publication on 30.04.2021

The patient was submitted to surgical procedure under general anesthesia, with orotracheal intubation. Intraoperative findings highlighted multiple, septated, lipomatous accumulations of fatty tissue, adherent to the neighboring structures, with poorly delimited edges. During its evolutive process, formations reached the level of the superior thoracic aperture, on the right side. Surgical excision was carefully accomplished and followed by drainage. The course of the case during postoperative surveillance was favorable, the patient showed no signs of local recurrence in the follow-up time.

The histopathological examination of the obtained samples showed fibrolipomatous tumors, each containing fat cells without cellular or nuclear atypia. Sizes varied from 11 x 9 x 4 cm^3 to 1 x 1 x 0,5 cm^3.

Figure no. 5,6. Postoperatory specimen

DISCUSSIONS

Madelung's disease is an uncommon disorder of lipid metabolism, clinically recognized by the characteristic appearance of non-encapsulated lipomatous tumors, simetrically arranged in the maxillofacial region, neck, joints, trunk, limbs and other locations. The distinctive aspect is that of a pseudo-athlete.

Enzi divided MSL into two types. In type I, the accumulation of adipose tissue at the cervico-thoracic level determines the typical pseudo-athletic appearance, while in type II the distribution does not specifically change the patient's clinical aspect and can be misdiagnosed with obesity, due to their similarities.(7,8)

According to the classification system proposed by Donhauser et al, MSL was categorized into four types: type I – horsecolar; type II – pseudo-athletic; type III – gynecoid; type IV – abdominal.(9) Starting from the premise that the proliferative process begins from the neck level and subsequently disseminates caudally, Schiltz et al proposed the classification into 5 phenotypes.(10)

Figure no. 7. Schiltz classification from reference (10) and partially modified

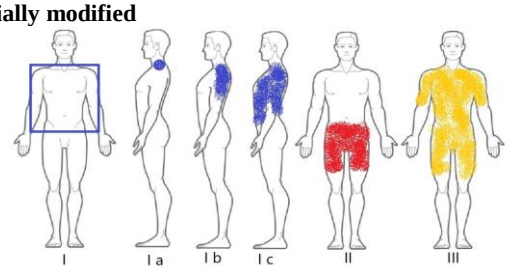

Multiple symmetric lipomatosis should be distinguished from familial multiple lipomatosis characterized by the growth of smaller-sized nodules spread across the limbs, rarely affecting the neck and shoulders region.

The exact causes that lead to this disease are incompletely elucidated. The existence of an autosomal dominant transmission with mutations in the mitochondrial DNA is suspected, affecting genes that are involved in the lipolytic regulation process. Some recent evidence indicated that intra-adipocitary changes in those suffering from MSL are the result of the mitochondrial changes occurring in the brown adipose tissue.(8,11,12)

There is clear evidence regarding the connection between this condition and the overuse of alcohol. The vast majority of people with Madelung's disease are chronic alcohol users, with a large number of cirrhotic cases being associated. The mechanism that explains the causal relationship between alcohol overconsumption and this type of lipomatosis involves mitochondrial enzymatic changes that interrupt the lipolysis mechanism. Simultaneously, alcohol causes a decrease in the number and activity of β-adrenergic receptors, thus promoting lipogenesis.(12)

From a clinical point of view, the initial phase of this disorder is based on an accelerated process of tumor development, therefore followed by a slower progression of the disease. By far, the majority complains about the unsightly appearance given by the lipomatous formations, but pain is often associated and in advanced forms of illness, it is accompanied by respiratory, digestive (swallowing difficulties), nervous or vascular dysfunctions through extrinsic compression of the nearby elements.

The pseudo-athletic aspect and the presence of lipomatous nodules with neck, upper thorax and maxillofacial dispositions, represents the most relatable diagnostic features. However, Madelung's disease should be suspected in any patient in whom multiple symmetric lipomatosis is perceived, in spite of its location. This diagnosis should be presumed, especially if alcohol consumption is identified in that patient.

The diagnostic process is not dependent upon the laboratory tests, but there are abnormalities in the lipid profile (lipids, total cholesterol, triglycerides) and liver function tests that could be recognized and disease-related.

There are other pathologies associated with this syndrome, such as: hyperlipemia, hyperuricemia, insulin resistance, metabolic syndrome, tubular acidosis, reactive hepatitis and liver cholestasis, all of them certainly contributing to an accelerated proliferation of the disease. Paradoxically, the serum concentration of HDL-cholesterol is usually high.(13,14)

60-90% of the patients with MSL have alcoholic liver cirrhosis or hepatic steatosis.(8)

The histological diagnosis is that of adipose tissue without atypia but with lipid accumulation in the brown adipose tissue. Malignant transformation is a rare occurrence, isolated case reports of evolution to myxoid sarcoma or liposarcoma have been described.(15,16)

The imaging consists of the ultrasound examination that can identify the lipomatous character of the formations. CT and especially MRI, provides additional data, including details about how the lesion is located or related to the nearby structures. Although rarely, the condition is also described in pediatric ages, when diagnostic imaging is of utmost importance, in order to differentiate this disorder from other congenital diseases.(17)

A list of possible differential diagnoses should include: morbid obesity, Cushing's syndrome, salivary gland pathologies, lymphoma, Froelich's syndrome, angiolipomatosis, mixed-type liposarcoma, neurofibromatosis or Dercum's disease.(16,18)

Medical treatment strategy uses fibrate therapy, which is considered to reduce further progression of the disease by lowering triglycerides concentrations in blood serum. Alcohol withdrawal is recommended, since alcohol consumption was named to be a significant risk factor in the onset, development and persistence of the disease.(19)

Subcutaneous administration of lipolytic solutions including lecithin or phosphatidylcholine, may have beneficial

results, but the eventuality of experiencing side effects, especially in cases with neuropathy, prevent the current use of this type of therapy.(20,21)

Surgical treatment oscillates between excisional lipectomy of the lipomatous formations through multiple incisions or through one incision, located in the anterior cervical region, prolonged laterally and liposuction.

One big advantage of the liposuction is the aesthetic result and purpose, with minimal incisions and scarring, and also the possibility to recover faster. This approach is mostly considered when the growing deposits of adipose tissue are located at the level of the abdomen, thorax and limbs. It is rarely known for the cervical region to be approached this way. A higher recurrence rate comes as a disadvantage when comparing liposuction with lipectomy, probably due to the fact that lipomas in Madelung's disease are not encapsulated, being poorly delimited, with an increased possibility for the residual fatty tissue to remain. In addition, using a blind approach of the cervical, maxillofacial, upper thoracic areas, with rich vascularity and superficial innervation, can cause hemorrhage or unpleasant nerve injury.(22)

Lipectomy allows the surgeon to excise lipomas located in spaces that may firstly appear as being difficult to approach, placed between important anatomical elements. In this manner, a better visualization and excisional process are warrantied.

Since surgical management is controversial, we decided to consult the medical literature in order to establish which of the surgical techniques is more used and which one has better outcomes. We conducted a literature review over a 20-years period of time (between 2001 and 2021), using PubMed database, by entering the following keywords: Madelung's disease, lipectomy and liposuction. Our search returned 57 results. Pediatric cases, reports that could not have been accessed, cases that provided with insufficient information or publications in a language other than English were excluded. Afterwards, we obtained 19 articles that met our review criteria (table no.1) From these 19 articles, 24 patients were selected, 70.83% male and 29.16% female with a sex ratio of 3 : 1. The average age of the patients figured out to be 53.9 years, 54.6 years for men and 52.1 years for women. Alcohol abuse was identified in 62.15% of cases (n=15), (58.82% of men and 71.42% of women), 37.5% of patients had liver cirrhosis, 12.5% liver steatosis and 37.5% presented abnormalities of the lipid profile.

The most common locations of lipomatosis were represented by the neck and head areas – 58.33%, followed by the abdominal and thoracic regions. Scrotal and orbital dispositions of the lipomas were rarely met. In men, lumps were predominantly located at the neck and head level (76.47%), while in women, chest and shoulders were identified as being the most affected areas.

Lipectomy was performed in 75% of the patients and liposuction in 25%. In men, lipectomy was the surgical technique of choice (88.23%) and in 57.14% of women, liposuction was preferred. Liposuction was commonly performed in cases with thoracic and abdominal disposition of the adipose tissue masses in women, and with maxillofacial and neck disposition in cases of men. No recurrences were recorded, but in 2 cases lipectomy was chosen after an unsuccessful prior liposuction procedure, which resulted in recurrence.

Evidences revealed that Madelung's disease and alcohol consumption are closely linked. The most frequent locations of interest proved to be represented by the neck and upper thoracic region. In most cases, lipectomy achieved better results than liposuction in terms of postoperative recurrences. Dietary and pharmacological treatment, alcohol withdrawal, weight loss and surgical management does not exclude the risk of local recurrence, some patients requiring multiple interventions.

CONCLUSIONS

Madelung's disease is a rare entity with a multifactorial etiology. Its diagnosis can be easily presumed, mainly by the typical clinical appearance. Most patients associate other comorbidities with this condition, especially liver pathologies. Lipomatous lumps can cause complications by compressing the surrounding elements.

The most successful treatment with the highest rate of effectiveness is the surgical one, lipectomy being preferred at the expense of liposuction.

Table no. 1. Madelung disease literature review 2001-2021

No.	Authors	Year	Age	Gender	Alcohol abuse	Disposition	Lipectomy	Liposuction
1.	Jung K et al (23)	2020	59	F	✓	Trunk	✓	
2.	da Costa JN et al (24)	2017	59	M	✓	Scrotal	✓	
3.	Sharma N et al (39)	2015	51	M		Neck	✓	
4.	Celentano V et al (25)	2014	51	M	✓	Head and neck	✓	
5.	Hundeshagen G et a l(26)	2014	53	M	✓	Head and neck	✓	
6.	Lin FY et al (27)	2013	68	M		Head and neck	✓	
7.	Nikolić ZS et al (28)	2013	51	M	✓	Thorax, breast	✓	
8.	Agostini T et al (29)	2013	62	M		Thorax and abdomen		✓
9.	Di Candia et al (30)	2011	34	M		Head and neck	✓	
10.	Laure B et al (31)	2011	70	M		Orbits	✓	
11.	Strassburg CP et al (32)	2009	44	F	✓	Shoulders and upper arms	✓	
12.	Verna G et al (13)	2008	62	F	✓	Upper arms and thorax		✓
			64	F	✓	Abdomen	✓	
			40	M	✓	Head and neck	✓	
			55	M	✓	Neck	✓	
13.	Grassegger A et al (33)	2007	54	F	✓	Neck and thorax		✓
14.	Goshtasby P et al (34)	2006	35	F		Hips		✓
15.	Guilemany JM et al (35)	2005	52	M		Head and neck	✓	
16.	González-García et al (36)	2004	51	M	✓	Head and neck	✓	
			52	M		Head	✓	
17.	Baynosa RC et al (37)	2004	47	F		Head and neck		✓
			64	M	✓	Head and neck	✓	
18.	Faga A et al(38)	2001	51	M	✓	Headand neck		✓
19.	Adamo C et al (6)	2001	65	M	✓	Head and neck	✓	

REFERENCES

1. Brodie BC. Clinical Lectures on Surgery Delivered at StGeorges Hospital. Philadelphia, Pa, USA: Lea and Blanchard; 1846.
2. Madelung OW. Uber den Fetthals. Archiv für klinische Chirurgie. 1888;37:106–130.
3. Launois PE, Bensaude R. L'adenolipomatose symmetrique. Bulletin et Memoires de la Societe Medicale des Hospitaux des Paris. 1898;1:298–318
4. Mevio E, Sbrocca M, Mullace M, Viglione S, Mevio N. Multiple symmetric lipomatosis: a review of 3 cases. Case Rep Otolaryngol. 2012;2012:910526. doi:10.1155/2012/910526.
5. González-García R, Rodriguez-Campo FJ, Sastre-Pérez J, Muñoz-Guerra MF. Benign symmetric lipomatosis (Madelung's disease): case reports and current management. Aesthetic Plastic Surgery. 2004;28(2):108–112
6. Adamo C, Vescio G, Battaglia M, Gallelli G, Musella S. Madelung's disease: case report and discussion of treatment options. Ann Plast Surg. 2001 Jan;46(1):43-5. doi: 10.1097/00000637-200101000-00008.
7. Enzi G. Multiple symmetric lipomatosis: an updated clinical report. Medicine. 1984;63(1):56–64.
8. Szewc M, Sitarz R, Moroz N, Maciejewski R, Wierzbicki R. Madelung's disease - progressive, excessive, and symmetrical deposition of adipose tissue in the subcutaneous layer: case report and literature review. Diabetes Metab Syndr Obes. 2018 Nov 26;11:819-825. doi: 10.2147/DMSO.S181154.
9. Donhauser G, Vieluf D, Ruzicka T, et al. [Benign symmetric Launois-Bensaude type III lipomatosis and Bureau-Barrière syndrome]. Hautarzt. 1991;42:311–314.
10. Schiltz D, Anker A, Ortner C, Tschernitz S, Koller M, Klein S, Felthaus O, Schreml J, Schreml S, Prantl L. Multiple Symmetric Lipomatosis: New Classification System Based on the Largest German Patient Cohort. Plast Reconstr Surg Glob Open. 2018 Apr 4;6(4):e1722. doi: 10.1097/GOX.0000000000001722.
11. Chen K, Wang L, Yang W, Wang C, Hu G, Mo Z. Profiling of differentially expressed genes in adipose tissues of multiple symmetric lipomatosis. Mol Med Rep. 2017 Nov;16(5):6570-6579. doi: 10.3892/mmr.2017.7437.
12. Plummer C, Spring PJ, Marotta R, Chin J, Taylor G, Sharpe D, Athanasou NA, Thyagarajan D, Berkovic SF. Multiple Symmetrical Lipomatosis--a mitochondrial disorder of brown fat. Mitochondrion. 2013 Jul;13(4):269-76. doi: 10.1016/j.mito.2013.03.003.
13. Verna G, Kefalas N, Boriani F, Carlucci S, Choc I, Bocchiotti AM. Launois-Bensaude Syndrome: an unusual localization of obesity disease. Obes Surg. 2008;18(10):1313-7
14. Lee HW, Kim TH, Cho JW, Ryu BY, Kim KH, Choi CS. Multiple symmetrical lipomatosis: Korean experience. Dermatol Surg. 2003;29(3):235-40.
15. Enzi G, Busetto L, Ceschin E, Coin A, Digito M, Pigozzo S. Multiple symmetric lipomatosis. Clinical aspects and outcome in a long-term longitudinal study. Int J Obes Relat Metab Disord. 2002;26(2):253-61.
16. Ardeleanu V, Chicos S, Georgescu C, Tutunaru D. Multiple benign symmetric lipomatosis -- a differential diagnosis of obesity. Chirurgia (Bucur). 2013 Jul-Aug;108(4):580-3. PMID: 23958107.
17. Micu R, Chicea AL, Bratu DG, Nita P, Nemeti G, Chicea R. Ultrasound and magnetic resonance imaging in the prenatal diagnosis of open spina bifida. Med Ultrason. 2018 May 2;20(2):221-227. doi: 10.11152/mu-1325.
18. Esposito AC, Munhoz T, Abbade LP, Miot HA. Do you know this syndrome? Type 2 benign symmetric lipomatosis (Launois-Bensaude). An Bras Dermatol. 2016;91(6):840-841. doi:10.1590/abd1806-4841.20164744
19. Tong Y, Hara A, Komatsu M, Tanaka N, Kamijo Y, Gonzalez FJ, et al. Suppression of muscle associated proteins PPAR alpha in brown adipose tissue. Biochem Biophys Res Commun. 2005; 336(1):76-83.
20. Rohrich RJ. Mesotherapy: what is it? Does it work? Plast Reconstr Surg. 2005;115(5):1425.
21. Rotunda AM, Kolodney MS. Mesotherapy and phosphatidylcholine injections: historical clarification and review. Dermatol Surg. 2006;32(4):465-80.
22. Tănăsescu C, Bratu D, Sabău D. Characteristics of Thoraco-Abdominal Injuries - A Series of Three Cases. Chirurgia (Bucur). 2020 Jul-Aug;115(4):530-536. doi: 10.21614/chirurgia.115.4.530.
23. Jung K, Lee S. A case report of Multiple Symmetric Lipomatosis (MSL) in an East Asian Female. BMC Womens Health. 2020;20(1):200. Published 2020 Sep 14. doi:10.1186/s12905-020-01055-w
24. da Costa JN, Gomes T, Matias J. Madelung Disease Affecting Scrotal Region. Ann Plast Surg. 2017 Jan;78(1):73-77. doi: 10.1097/SAP.0000000000000714.
25. Celentano V, Esposito E, Perrotta S, Giglio MC, Tarquini R, Luglio G, Bucci L. Madelung disease : report of a case and review of the literature. Acta Chir Belg. 2014 Nov-Dec;114(6):417-20.
26. Hundeshagen G, Hundeshagen G, Assadov KF, Podmelle F. Facelift- and circum-occipital incision placement for fat extirpation of the neck in Madelung's disease - a two-case report. J Craniomaxillofac Surg. 2014 Mar;42(2):175-9. doi: 10.1016/j.jcms.2013.04.011.
27. Lin FY, Yang TL. Madelung disease. CMAJ. 2013;185(1):E79. doi:10.1503/cmaj.120191
28. Nikolić ZS, Jeremić JV, Drčić LJ, Rakočević ZB, Tačević ZD, Jeremić KV, Stojnić JD. Madelung disease: a rare case associated with gynaecomastia and scrotal involvement. J Plast Surg Hand Surg. 2013 Oct;47(5):415-8. doi: 10.3109/2000656X.2012.729627.
29. Agostini T, Perello R, Bani D, Mori A, Quattrini Li A, Russo GL. Histomorphometry of dystrophic fat in a patient suffering Madelung's disease. J Plast Reconstr Aesthet Surg. 2014 Jan;67(1):132-4. doi: 10.1016/j.bjps.2013.07.014
30. Di Candia M, Cormack GC. Rhytidectomy approach for recurrent Madelung disease. Aesthet Surg J. 2011 Aug;31(6):643-7. doi: 10.1177/1090820X11415394.
31. Laure B, Sury F, Tayeb T, Corre P, Goga D. Launois-Bensaude syndrome involving the orbits. J Craniomaxillofac Surg. 2011 Jan;39(1):21-3. doi: 10.1016/j.jcms.2010.04.003.
32. Strassburg CP, Lehner F, Kreipe HH. Clinical challenges and images in GI. Image 3: Madelung syndrome. Gastroenterology. 2009 Feb;136(2):406, 732. doi: 10.1053/j.gastro.2008.07.071.
33. Grassegger A, Häussler R, Schmalzl F. Tumescent liposuction in a patient with Launois-Bensaude syndrome and severe hepatopathy. Dermatol Surg. 2007 Aug;33(8):982-5. doi: 10.1111/j.1524-4725.2007.33204.x.
34. Goshtasby P, Brooks G, Fielding LP. Lipomatous disorder of the peri-trochanteric soft tissue: case report and review. Curr Surg. 2006 Sep-Oct;63(5):338-44. doi: 10.1016/j.cursur.2006.03.005.
35. Guilemany JM, Romero E, Blanch JL. An aesthetic deformity: Madelung's disease. Acta Otolaryngol. 2005 Mar;125(3):328-30. doi: 10.1080/00016480410022903.

36. González-García R, Rodríguez-Campo FJ, Sastre-Pérez J, Muñoz-Guerra MF. Benign symmetric lipomatosis (Madelung's disease): case reports and current management. Aesthetic Plast Surg. 2004 Mar-Apr;28(2):108-12; discussion 113. doi: 10.1007/s00266-004-3123-5.
37. Baynosa RC, Shah HR, Khiabani KT, Zamboni WA. Ultrasound-assisted liposuction in the treatment of lipodystrophy secondary to cushingoid-type disease of unknown cause. Plast Reconstr Surg. 2004 Aug;114(2):474-7. doi: 10.1097/01.prs.0000128639.00060.3f.
38. Faga A, Valdatta LA, Thione A, Buoro M. Ultrasound assisted liposuction for the palliative treatment of Madelung's disease: a case report. Aesthetic Plast Surg. 2001 May-Jun;25(3):181-3. doi: 10.1007/s002660010118.
39. Sharma N, Hunter-Smith DJ, Rizzitelli A, Rozen WM. A surgical view on the treatment of Madelung's disease. Clin Obes. 2015 Oct;5(5):288-90. doi: 10.1111/cob.12111.